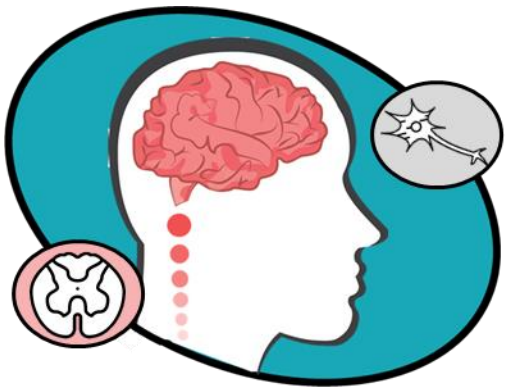

CNS

Anatomy

Sheet Slide

Number

6

Done by:

Doctor 2015

Corrected by:

Osama Asa'ad Khader

Doctor:

Mohammad Alsalem

A quick revision for the spinal cord blood supply:

Arterial Blood supply of spinal cord

The spinal cord got its arterial supply by two ways:

- Longitudinal arteries
- Segmental arteries

1- Longitudinal arteries: the vertebral arteries proceed superiorly and enter transverse foramina of cervical vertebrae then they enter foramen magnum in the occipital bone. After right and left vertebral arteries pass through foramen magnum they run medially and meet each other on the lower border of pons (pontomedullary junction) forming **basilar artery** which run superiorly in the basilar groove on anterior border of pons, on upper border of pons it divides into <u>two posterior cerebral arteries</u>. But before that they give branch on anterior aspect of spinal cord and they meet each other on anterior median fissure to form <u>anterior spinal artery</u>, which descends along the spinal cord.

- Right and left vertebral arteries also give posterior inferior cerebellar arteries which give two posterior spinal arteries (in the posterolateral sulcus).

Now we have one anterior spinal artery and two (right and left) posterior spinal arteries.
(They are the longitudinal arteries of spinal nerve)

<u>Central cord syndrome</u>: temporary occlusion in the anterior spinal artery due to mostly neck hypertension with the presence of sharp edges form bone (spares).

It's <u>characterized by</u>:

- bilateral (only one artery for both sides) muscle weakness since the anterior spinal artery supplies the anterior grey matter.
- bladder dysfunction
- variable pain and thermal defects

The recovery begins distally then goes upwards.

Brain stem:

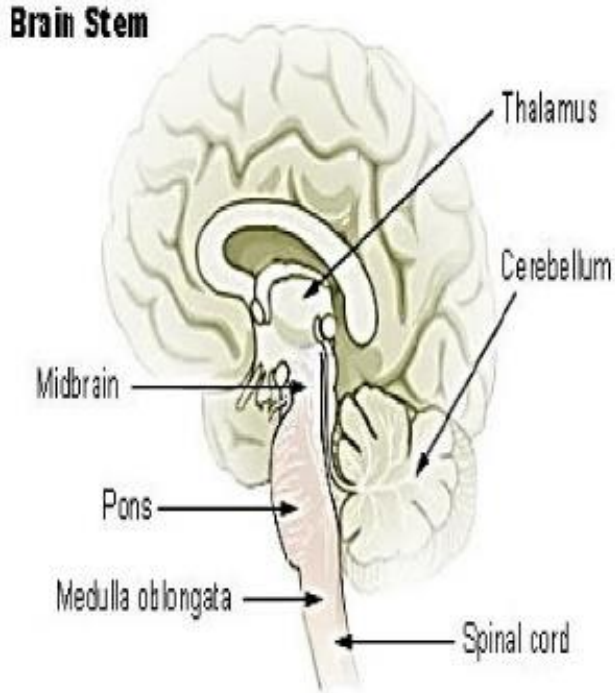

- **Hindbrain:**
  - Medulla
  - Pons
  - Cerebellum
- **Brain stem:**
  - Medulla
  - Pons
  - Midbrain: above it the thalamus which part of the diencephalon.

- Gross/external features: (explained in lab)

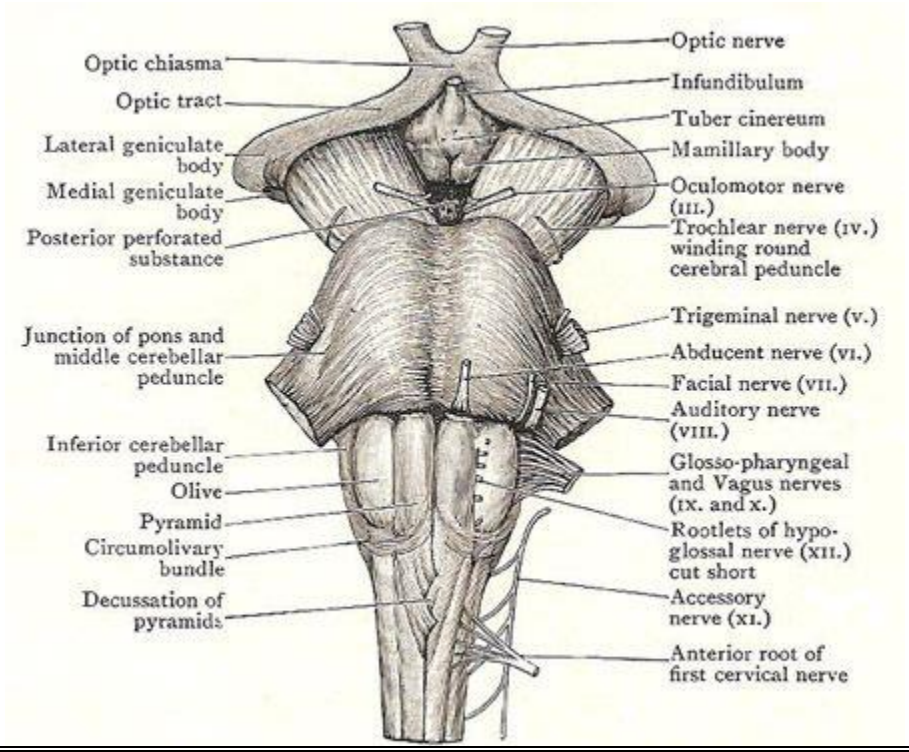

- **The Pyramid two bulges around the midline**, while **the olive away from midline.**
- 10 of the cranial nerves emerge from the brain stem.
- The picture shows the order of cranial nerves arising from brain stem.
- The first two cranial nerves**, olfactory (I) and optic (II), are not related to brain stem** they arise from the **forebrain (CNS)**. Both are sensory.
- Oculomotor (III) arises from the floor of the mid-brain, and it is a motor nerve.
- *Trochlear N. (IV) is the only one that arises from posterior\dorsal aspect of brainstem* (interpeduncular fossa), it is a motor nerve.
- Trigeminal N.(V) largest cranial nerve, arises from mid pontine area, divides into two sensory branches (ophthalmic and maxillary) and one motor branch (Mandibular)
- Medially to laterally: Abducent (VI), Facial (VII) and Vestibulocochlear (VIII) nerves arise from **pontomedullary junction**
- Glossopharyngeal (IX), Vagus (X), accessory (XI) → arise from the groove between the olive and inferior cerebellar peduncle.
- Hypoglossal (XII) arises from the groove In between the pyramid and olive.
- The nuclei of these nerves are either sensory, motor, or parasympathetic. We will talk about them in details when we discuss the sections.

Q: what is the cavity found in the hindbrain?

The Fourth ventricle, it is related to both **pons and medulla oblongata.**

It has the shape of a tent, with a roof and floor.

- the **floor** of 4th ventricle is formed of **the posterior aspect of pons of medulla oblongata**
- **the roof is toward the cerebellum**
- **the upper part of medulla oblongata is related to the lower part of the 4th ventricle (the cavity)**

- a cross section in the lower part of medulla oblongata will show the central canal.

Q: What do you expect to see in the brain stem?

- ascending and descending tracts.
- The nuclei of the cranial nerves (sensory and motor nuclei instead of ventral and dorsal horns as is the spinal gray matter).
- Reticular formation.

Internal structure of medulla:

All brainstem will be studied **in 8 sections**, 4 of them from **medulla oblongata**, 2 of these 4 are on **the lower medulla**, where the cavity is the *central canal.*

- if the section has a big cavity → open medulla (2 sections)
- if you see a central canal in the section → close medulla (2 sections).

From downward to upward:

- level of pyramidal decussation (close medulla / motor) level of foramen magnum.
- level of decussation of lemnisci (close medulla / sensory)
- level of olives (open medulla)
- level just inferior to the pons

  practically they are 3 decussations because 3rd and 4th decussations are too similar.

Level of decussation of pyramid:

- This is a **posterior view.**
- You can see the floor of the 4th ventricle which has a rhomboid shape (two triangles).
- The lower part of it (the lower triangle) is the part that is related to medulla oblongata.
- Both sections A & B in the picture below will cut into the closed medulla which mean that they will show the central canal.

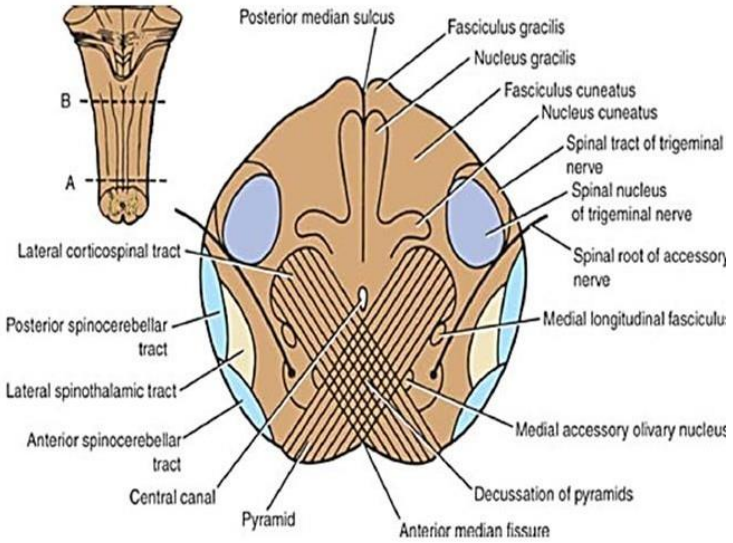

- First thing to notice is the **central canal** *(make it your reference point).*
- **Pyramidal decussation is anterior to central canal.**
- This decussation is composed of corticospinal tract fibers crossing each other; right to left & left to right, **except** for the **anterior corticospinal fibers that go ipsilateral.**
- If you look posterior to central canal you will see:
    - **Gray matter:**
        - Nucleus gracilis: close to midline
        - Nucleus cuneatus: lateral. Remember: <u>nucleus</u> indicates gray matter
    - **White matter**:
        - Fasciculus gracilis
        - Fasciculus cuneatus

Just to remind you when we took the posterior column system:

The fibers that go **up** are divided to:

- Medially **gracilis**
- Laterally **cuneatus**

Both are white matter in spinal cord, and they go up to the lower part of medulla and their you'll see:

- The 2 nuclei (gracilis and cuneatus) and their fibers (white matter Fasciculi)
- In brainstem: you'll see the traces of both ascending and descending fibers, all will pass through the brainstem.
- The brainstem consists mainly from the nuclei of the cranial nerves (sensory or motor).

➔ Spinal nucleus of trigeminal nerve:

- **trigeminal Nerve:** originates from **mid pontine area (pons)**
  - **mainly sensory:** head, neck, nasal cavity, oral cavity and face (except for the angle of mandible)
  - **motor:** muscles of **mastication** (tensor tympani, tensor veli palatine, mylohyoid, ant. Belly of digastric)
  - has **four** nuclei: one motor, three sensory
  - sensory nuclei of trigeminal:
    I. **main sensory (primary sensory):** found in pons
    II. **mesencephalic:** name indicates it's up in the brain
    III. **spinal nucleus of trigeminal Nerve:**

- spinal nucleus of trigeminal is named so because it extends **along the brainstem from mid pontine down to spinal cord**, it is an extension of the upper cervical segment substantia gelatinosa (lamina II)
- you'll see the **spinal nucleus in upper and lower sections in brain stem**.
- note it doesn't extend along all the brainstem, it starts from mid pontine and below, while above the mid pontine it is replaced by **main sensory**.

Q: Why are there three nuclei for the Trigeminal nerve?

For modalities.

- **spinal:** pain and temp.
- **mesencephalic:** proprioception
- **main sensory:** crude touch

- Spinal nucleus of trigeminal is surrounded by fibers from trigeminal (white matter) trying to reach nucleus.

- **Important:** the anterolateral system in the spinal cord doesn't change very much when reaching the medulla oblongata, fibers come closer but they still have the same position related to each other, so you should pay attention to the few things:
  1. Nucleus gracilis and nucleus cuneatus (not found in spine)
  2. Fasciculus gracilis and Fasciculus cuneatus
  3. Pyramidal decussation

- **Important**: spinal nucleus of trigeminal is not only trigeminal fibers, the only reason to call it trigeminal is that most of fibers are trigeminal fibers (predominant fibers) but all cranial nerves that have pain and temperature modality (facial, glossopharyngeal, vagus) all relay to spinal nucleus of trigeminal (for example, the glossopharyngeal fibers send input to spinal nucleus of trigeminal).

Medial longitudinal fasciculus:

Vestibular nucleus gives a bundle of white matter that connects the vestibular nucleus with **the motor nucleus of the 3rd, 4th and 6th cranial nerves** (oculomotor III, trochlear IV, abducens VI), to synchronize the movement of eye ball, that bundle of white matter is called **medial longitudinal fasciculus**.

The idea of the link between the three cranial nerves is to coordinate the movement of right and left eye:

When you move your eyes to right or left direction, in one eye it's the medial rectus muscle that contracted but for the other eye it's the lateral rectus that contracted, and for this to happen at the same time we need the connection between the three motor nuclei.

What about the **vestibular nucleus**? The connection between motor nuclei and vestibular nucleus is to coordinate the movement of head with movement of eye (vestibular provides information about gravity) to maintain the visual field while walking and moving your head.

we will see the Medial longitudinal fasciculus more clearly from **upper sections

Remember:

Nerves that control the movement of the eyeball:

1- **Oculomotor (III):** all external muscles except superior oblique and lateral rectus.

2- **Trochlear (IV):** supplies superior oblique.

3- **Abducent (VI):** supplies lateral rectus.

Now let's take a look at the section of the next higher level:

Level of decussation of lemnisci:

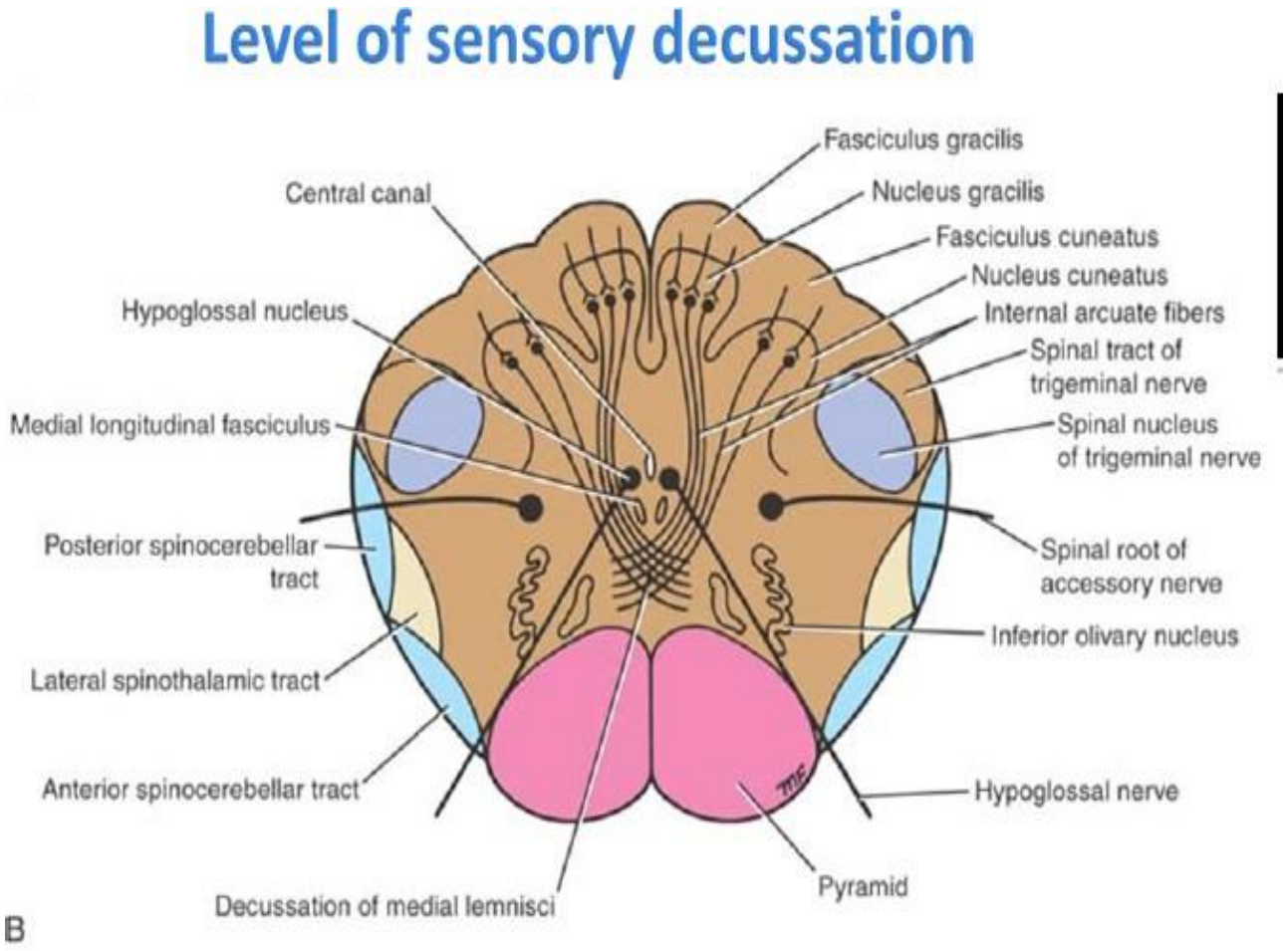

1-The cavity of this section is central canal → closed medulla

2- Posterior to central canal are nuclei of gracilis and coneatus, behind them are fasciculus gracilis and coneatus.

3- In these nuclei synapsis happens between 1st order neuron (from spinal cord)

4- and 2nd order neuron (from the nuclei), and internal arcuate fibers emerge and cross to contralateral side and this is the decussation.

The decussation (major sensory decussation) happens between the pyramids (anterior) and central canal (posterior), and when these fibers go up, we call them medial lemniscus.

The two pyramids are responsible for the bulge on anterior aspect of medulla oblongata close to the midline.

*Note: we can't see olives on this level.

On either side of central canal is the hypoglossal nucleus (motor nucleus), so the hypoglossal nerve has one nucleus (pure motor) and supplies all muscles of the tongue except palatoglossal muscle.

Hypoglossal nucleus receives signals from cortex by corticonuclear tract from both sides except small portion of the nucleus which supplies genioglossal muscle, which receives from opposite side of the cortex.

Anterior to hypoglossal nucleus is MEDIAL LONGITUDINAL FASCICULUS which is a bundle of white matter from VESTIBULAR NUCLEI connecting motor nuclei of three cranial nerves moving the eyeball (3rd, 4th, and 6th), and it descends to upper cervical segments (anterior horn of upper cervical segments) to coordinate between movement of head\ neck and eyeball movement.

Accessory nerve (xi) has cranial root and spinal root:

Spinal root from upper 5 segments (accessory nucleus in anterior horn) enters foramen magnum to go to cranial cavity and it meets cranial root of accessory nerve.

The nucleus in this level is a motor nucleus of accessory nerve but it's not exclusive for this nerve only, in fact it is a motor nucleus for cranial nerves number 9 \ 10 and 11, and we call it nucleus ambiguous.

Cranial root of accessory emerges from nucleus ambiguous to unite with spinal root of accessory, but they divide after that immediately.

ALS is unchanged on this level also, but here it starts to form spinal lemniscus with spinotectal tract.

*note: sometimes we can see a small part of inferior olivary nucleus but we don't consider it the level of the olives.

The third level is **<u>the level of olives:</u>**

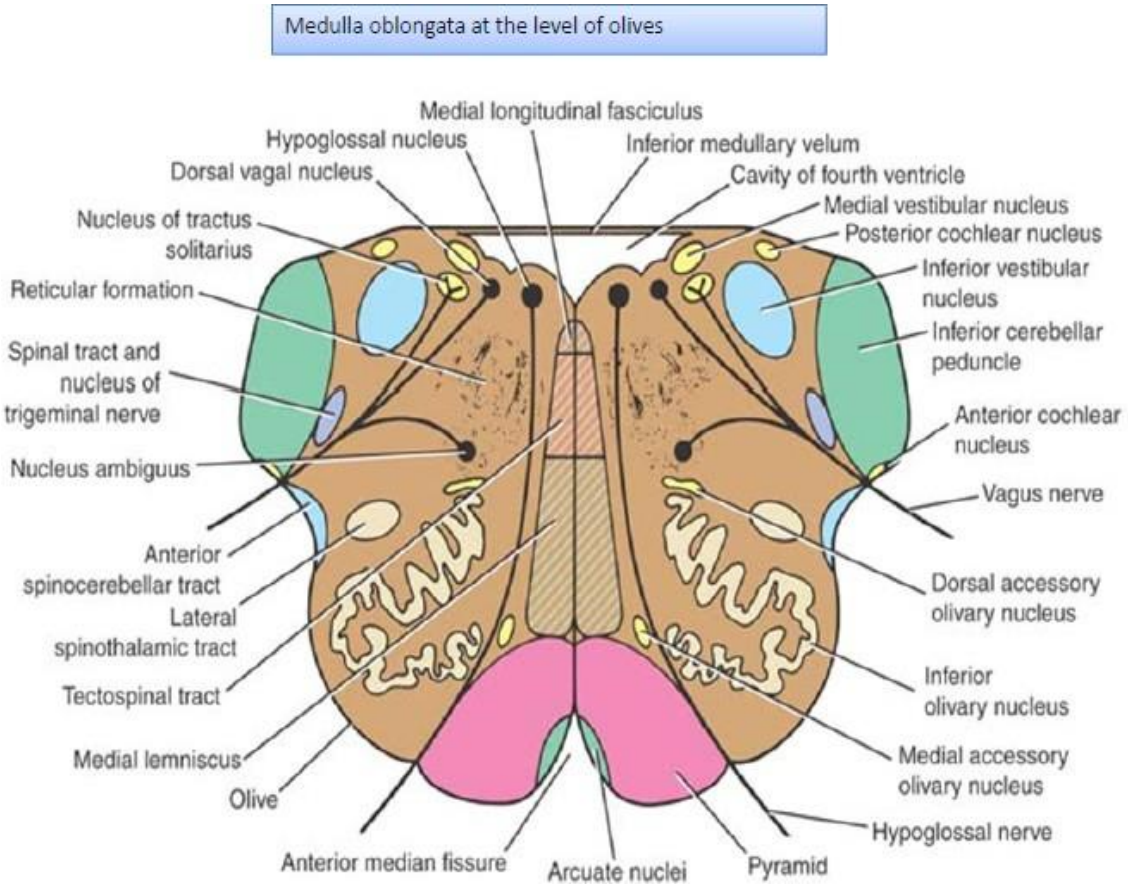

1- The cavity of this section is inferior part of 4th ventricle (open medulla), behind it is the cerebellum.

Floor of 4th ventricle ⟶ medulla oblongata

Roof of 4th ventricle ⟶ cerebellum

2- Posterolateral in this section is INFERIOR CEREBELLAR PEDUNCLE (ICP) which connects medulla oblongata with cerebellum. (one of the structures that cross ICP is posterior spinocerebellar tract).

3- There are many olivary nuclei on this level (OLIVARY NUCLEAR COMPLEX), the biggest one is INFERIOR OLIVARY NUCLEUS, which is the cause of the bulging in the olive (its shape resembles crumpled bag with its opening directed medially).

The function of inferior olivary nucleus is motor, and has a connection with cerebellum and cerebrum. There are fibers emerging from it that go to cerebellum by ICP, their name is climbing fibers.

*note: Fibers that go to cerebellum are divided into climbing fibers and Mossy fibers.

*note: Spino-olivary tract is very similar to spinocerebellar tract and is considered an alternative pathway from spinal cord to cerebellum.

4- Corticospinal tract gives branches to the olive, they are involved in voluntary movement and from olive to spinal cord (olivospinal tract which is motor (not important)).

*note: neurodegenerative diseases that affect olive will always affect the cerebellum so symptoms are overshadowed clinically.

Now let's talk about the *midline structures* in this section:

➢Medial lemniscus which is posterior to the pyramids and very close to the midline (lemniscus not fasciculus because fibers are elongated in shape and not rounded in the cross-section) which goes up until it reaches VPL in thalamus (one of the ventrobasal complex nuclei).

*note: VPM which is one of ventrobasal complex nuclei, is concerned with face and taste sensory pathway.

➢ posterior to medial lemniscus is tectospinal tract (extrapyramidal tract) which is very important in visual-spinal reflex (superior colliculus takes signals from visual pathway and spinotectal tract, then it sends signals through tectospinal tract to upper cervical segments).

*note: withdrawal reflex is different from spinovisual reflex. Withdrawal reflex is the sudden and immediate withdrawal movement of the limb after the harm signals reach the spinal cord. On the other hand, spinovisual reflex is when you move your head and eyes to see your limb after the harm signals reach the superior colliculus by tectospinal tract.

➢posterior to tectospinal tract is medial longitudinal fasciculus which is underneath the floor of 4th ventricle.

Now let's talk about *nucleus ambiguous*:

Nucleus ambiguous (which is deep in reticular formation) is a **motor** nucleus to **3 cranial nerves** (glossopharyngeal 9th \ vagus 10th \ cranial root of accessory nerve 11th).

*note: lower part of nucleus ambiguous is the part that supplies cranial root of accessory nerve.

*note: cranial nerves 10th \11th supply muscles of soft palate, pharynges, larynx and palatoglossus.

*note: reticular formation is in the core of brain stem (medulla oblongata, pons and may extend to midbrain.

Also, on this level we can see Central gray matter:

Underneath the floor of 4th ventricle, contains 4 structures from medial to lateral:

1- Motor nucleus of hypoglossal nerve: fibers of hypoglossal nerve emerge between pyramids and olives. (notice that 9th \10th \11th pass between olive and ICP)
2- Dorsal vagal nucleus (which is parasympathetic nucleus of vagus): if we cut vagus nerve we will see motor, sensory, parasympathetic, special sensory and visceral fibers. This nucleus gives parasympathetic supply to as long as distal third of transverse colon, after that level the sacral parasympathetic supply takes over.
   *note: only cranial and sacral nerves give parasympathetic supply to the body.
3- Nucleus of tractus solitarius (solitary nucleus) (sensory): takes fibers from vagus nerve (not only from vagus), its function is special sensation (taste) and visceral sensation.

Innervation of the tongue:

Anterior 2\3	Posterior 1\3
1- Lingual and trigeminal nerve (general sensory) 2- Facial nerve (chorda tympani) (taste)	Glossopharyngeal nerve (special sensory and general sensory)

*note: in infratemporal fossa there is a connection between lingual nerve and chorda tympani (facial).

**important: what is the connection between vagus nerve and taste? there are taste fibers on epiglottis which are from vagus nerve.

When vagus nerve gets out of skull by jugular foramen (9th and 11th use jugular foramen also) it will face 2 ganglia: inferior vagal ganglia and superior vagal ganglia, the cell body of taste and visceral sensory are in inferior vagal ganglia (glossopharyngeal is the same), superior vagal ganglia contain cell body of general sensation.

*note: jugular foramen is between superior and inferior vagal ganglia.

4- Inferior vestibular nucleus (medial vestibular nucleus): sensory nucleus for vestibular nerve which is part of vestibulocochlear nerve 8th (important for balance), which leaves the cavity of inner ear then internal acoustic meatus then brain stem (pontomedullary junction), cell body in Scarpa ganglia which is relay station in the groove between ICP and olive. Emergence of vestibulocochlear nerve: from vestibular nucleus to 1- cerebellum 2- medial longitudinal fasciculus 3- down on spinal cord 4- some people think it may project on cerebral cortex (VPL then cortex).

Now let's talk about 4th and last level of medulla oblongata:

Level just inferior to Pons:

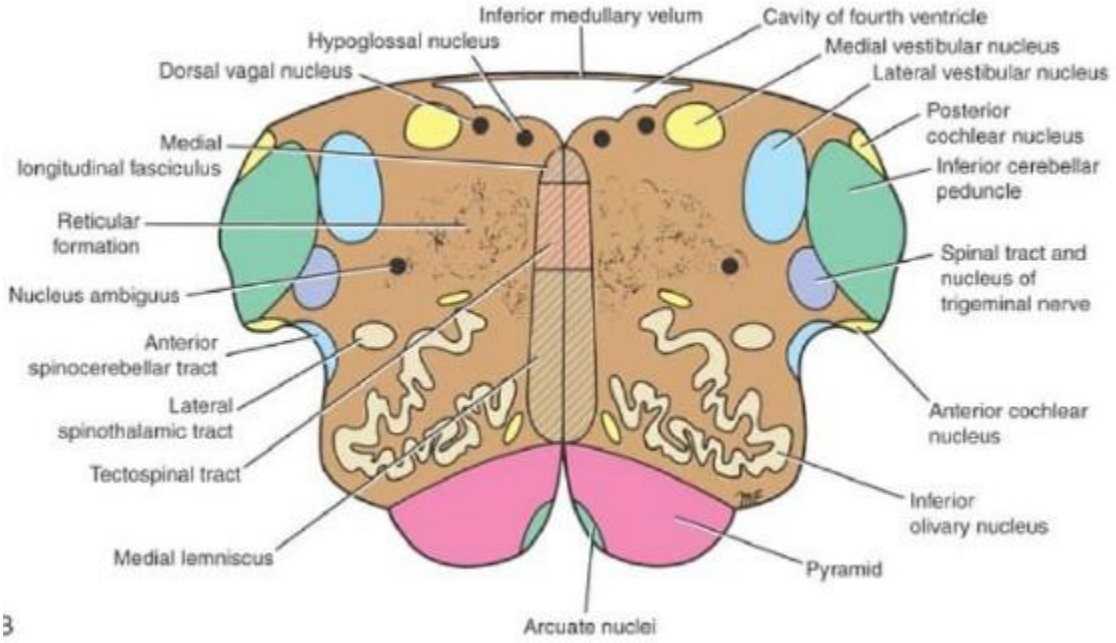

1- No major changes.
2- Most upper level in medulla oblongata
3- Lateral vestibular nucleus replaces inferior vestibular nucleus
4- Cochlear nuclei become visible on anterior(ventral) and posterior(dorsal) of ICP (relay station for cochlear nerve the second part of cranial nerve vestibulocochlear nerve 8th).