02

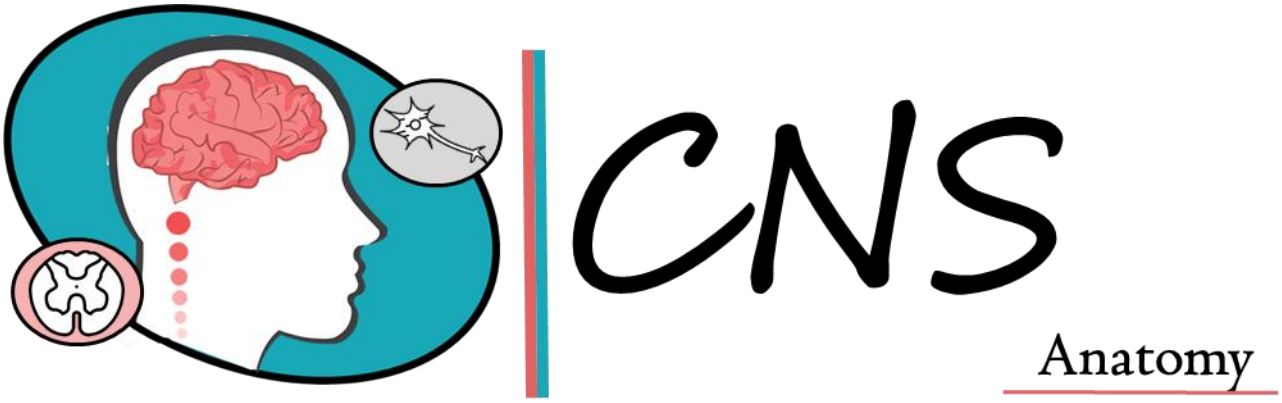

Sheet Slide

Number

Embryology

Done by:

Mustafa Khader and Zeina Assaf

Corrected by:

-

Doctor:

Dr. Maha Al Beltagy

In this lecture we will discuss the development of the Central Nervous System and the different congenital anomalies that may arise due to the failure of any step of its development.

Development of the Neural Tube:

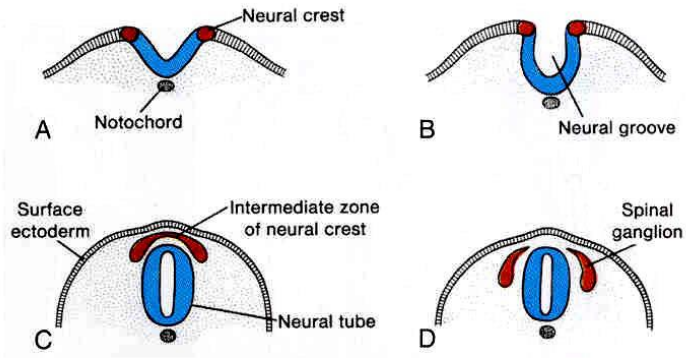

The development of the CNS begins around the **third week** of intrauterine life, it is initiated by the development of what is known as the **Neural Tube**. The neural tube begins as an **ectodermal** thickening of the trigeminal germ disc. As you know, the trigeminal germ disc starts to develop early following implantation. It consists of three layers; Endoderm, Mesoderm, and Ectoderm.

The ectodermal thickening stated previously forms what is known as the **Neural Plate**. This process is triggered by a structure present within the embryo (posterior to the surface ectoderm) known as the **Notochord.** At the end of development, the Notochord will form the Nucleus Pulposus of the Intervertebral Discs between the vertebrae. Therefore, it is important for you to know that once again the notochord is what initializes the process of ectodermal thickening and neuralization.

The Neural Plate invaginates towards the notochord to form a structure known as the **Neural Groove,** this is the second step in the development of the neural tube. The superior aspects of the neural groove (the lips of the neural grove) start to approach each other and the neural grooves fuse incompletely. Thus, leaving the “lips” unfused and allowing them to form neural crests which will develop into spinal ganglion.

This fusion causes the formation of the neural tube, and as you may have guessed we have now completed the development of the neural tube. The neural tube then sinks inside the surface ectoderm, causing the surface ectoderm to cover the neural tube completely. The neural tube now has two openings; one anterior and one posterior, these are known as neural pores.

The anterior pore then closes on the 25th day and the posterior pore closes on the 27th day transforming the neural tube into a closed tube.

Development of the Spinal Cord:

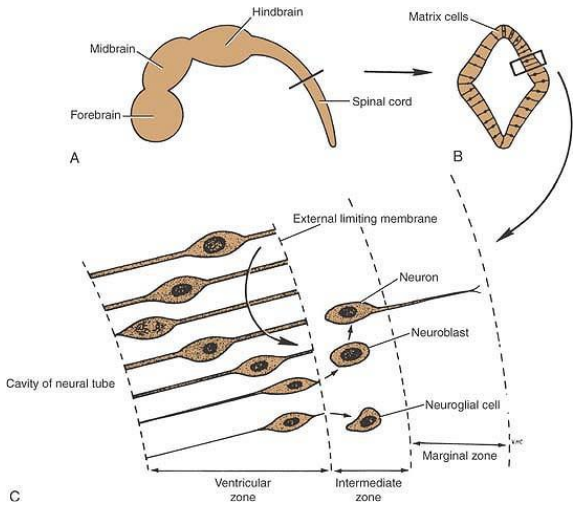

The neural tube consists of proximal and distal portions. The proximal portion will give rise to the Forebrain, Midbrain, and Hindbrain vesicles, which will form the brain, brain stem, and the Cerebellum. However, the distal portion will develop into the spinal cord.

As stated previously, the neural tube is a closed tube which has now become lined with a unicellular layer known as the neural matrix. The neural matrix will go through several cycles of division to increase in the length and diameter of the neural tube. During the course of division, the cells migrate towards the periphery of the tube giving rise to three layers of cells which can be distinguished in the figure above:

1. Inner Layer: will form the inner **Grey Matter** of the spinal cord
2. Intermediate Layer
3. Outer Layer: Also named the marginal layer, consists of the nerve fibres of the neuroblasts (the earliest stage of the neurons) and will develop into the **White Matter** of the spinal cord. Some neuroblasts also develop into Glial cells such as Astrocytes and Oligodendrocytes. On the other hand, the microglial cell is derived from the surrounding mesenchymal tissue.

The newly developed cells in the later wall of the neural tube will differentiate into three layers:

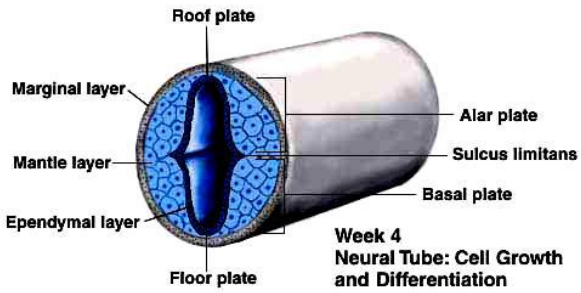

1. Inner Matrix Area: Also called the inner ependymal layer and will form the ependymal lining of the central canal of the spinal cord and the brain ventricles.
2. Middle Mantle Layer: this will form the grey matter of the spinal cord.

3. Outer Marginal Layer: forms the white matter of the spinal cord.

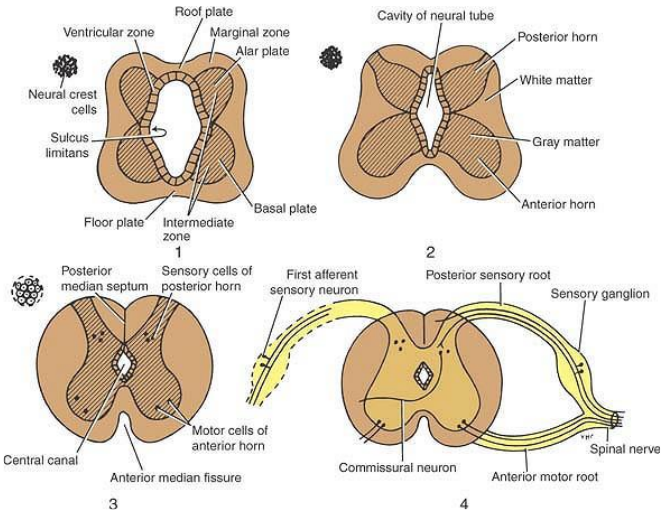

The lateral walls of the neural rube are connected by the roof plate dorsally and the floor plate ventrally. A groove then develops in the cells of the lateral wall of the tube known as Sulcus Limitans and will divide the tube into a dorsal and a ventral portion. The dorsal portion will form what is known as the Alar Plate and the ventral part will form the Basal Plate. The cells of the Alar Plate will extend dorsally to form the cells of the posterior horn/root of the spinal cord. On the other hand, the basal plate will extend ventrally/anteriorly to form the anterior/motor horn of the spinal cord. The cavity of the neural tube then narrows leading to the formation of the central canal of the spinal cord.

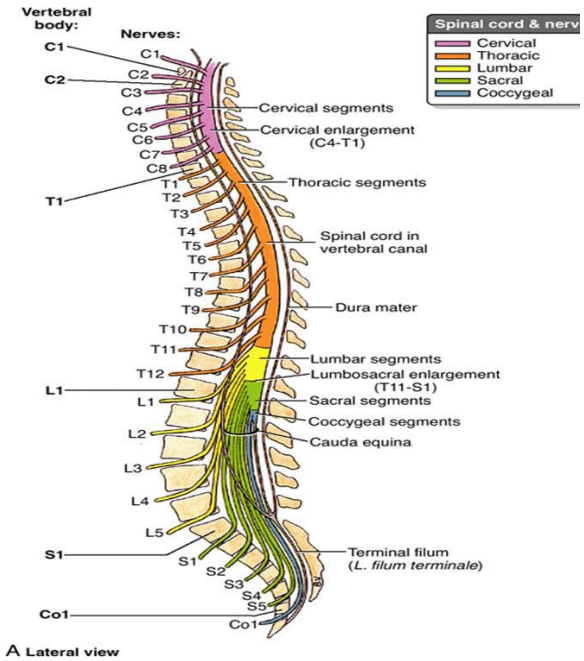

You are well aware that the brain and spinal cord are covered by three layers of meninges known as Pia, Arachnoid, and Dural matters from inside to outside respectively. We will now discuss the stages that lead to the development of the three meningeal layers. There is a layer of mesoderm which surrounds the neural tube known as para-axial mesoderm. The para-axial mesoderm will be subdivided into somites/segments which are further divided into:

1. Sclerotomes: Gives rise to the bones of the vertebral column, the cartilage between each successive vertebra, and the meninges.
2. Myotomes
3. Dermatomes

Continuing with the meninges, they are separated by spaces, for example the subarachnoid space between the Arachnoid and Pia matters. This space will develop as a cavity between the previous two

layers and later on in its development will become filled with cerebrospinal fluid. You should also be aware that during the first 2 months of intrauterine life the spinal cord and vertebral column are of the same length. At birth the Coccygeal aspect of the vertebra lies at the level of lumbar vertebra number three (L3). However, in adults the spinal cord terminates at the intervertebral disc between L1 and L2 and the end of the spinal cord is known as Conus Medullaris. The nerves passing bellow the Conus Medullaris are known as Cauda Equina which means "Horse Tail"

The table found below allows you to identify each segment of the spinal cord compared to the vertebral level it terminates at.

Regions	Spinal segments	Vertebral level	General rule
Upper cervical	C2	C2	Same level
Lower cervical	C6	C5	One vertebra above
Upper thoracic	T5	T3	Two vertebrae above
Lower thoracic	T10	T7	Three vertebrae above
Lumbar	L1–L5	T10–T11	Three to five vertebrae above
Sacral and coccygeal	S1–S5 and C × 1	T12–L1	Six to ten vertebrae above

Congenital Anomalies of Spinal Cord Development:

The most common congenital anomaly of the spinal cord is known as Spina Bifida, which means absence of the vertebral arch of the vertebral bone even though the spinal cord develops normally. There are many subtypes of spina bifida such as:

1. Spina bifida occulta: the most common type of Spina Bifida where the spinal cord lies within the vertebra however there is a failure in the development of the posterior aspect of the vertebral arch. Clinically it shows as hairy skin on the babies back and it most commonly affects the Lumbosacral Region.
2. Spina bifida cystica: In this type there is failure in development of the vertebral arch, but the spinal cord is also affected.
    a. Meningocele: In this subtype only the sac of meninges protrudes outside, and the spinal cord does not protrude and remains protected by the vertebral proximal part of the vertebral arch
    b. Meningomyocele: In this condition both the spinal cord and meninges are protruding in the sac filled with CSF, and this is more severe the Meningocele

c. Myelocele (Rachischisis): In this subtype which is the most severe of the three, the neural tube fails to obliterate and the spinal cord is protruded without any meninges.

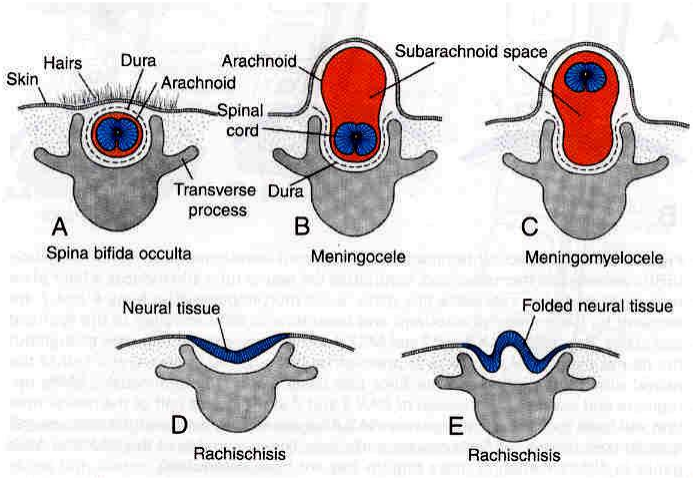

Development of the Brain:

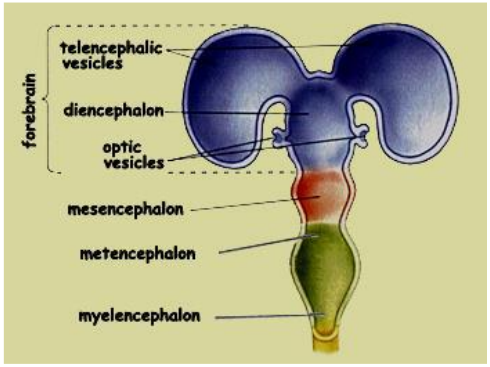

We will now begin with the development of the brain and the brainstem. In the early stages of development of the neural tube we stated that the proximal/cranial aspect of the neural tube has three vesicles:

1. **Forebrain Vesicle (Prosencephalon):** which forms 2 lateral evaginations known as **Telencephalon** which develop to form the **2 cerebral hemispheres** (their cavities form the lateral ventricles) and the median part develops to form the **Diencephalon** (its cavity forms the 3rd ventricle which lies between the two thalami)
2. **Midbrain Vesicle (Mesencephalon):** develops into the midbrain and its cavity forms the cerebral aqueduct which connects the third ventricle superiorly to the fourth ventricle inferiorly.
3. **Hindbrain Vesicle (Rhombencephalon):** will develop into the pons, medulla, and cerebellum and its cavity forms the fourth ventricle. It will be further divided into two vesicles; the **metencephalon** which gives rise to the **Cerebellum and Pons**, and the **myelencephalon** which gives rise to the **Medulla Oblongata**.

Doctor Maha stated that the following table has a question in the exam therefore make sure to memorize it:

Primary Vesicle	Secondary Vesicle	Derivatives
Prosencephalon	Telencephalon	Cerebral Cortex Cerebral White Matter Basal Ganglia
	Diencephalon	Thalamus Hypothalamus Subthalamus Epithalamus
Mesencephalon	Mesencephalon	Midbrain
Rhombencephalon	Metencephalon	Cerebellum Pons
	Myelencephalon	Medulla oblongata

Development of the medulla oblongata:

As you can see from the table above the medulla oblongata is a derivative of the Myelencephalon from the Rhombencephalon. The development of the medulla oblongata and the brain stem is very similar to the steps of the development of the spinal cord. As you may remember we have two Alar plates lying dorsally and two Basal Plates lying ventrally and a central canal. In the case of the Medulla we have the same structures however, the central canal is the 4th ventricle. In the case of the Medulla the Alar plate will develop into the sensory nuclei that lie within the Medulla. On the other hand, the basal plate will give rise to the motor nuclei within the Medulla. Similarly, to the spinal cord, both the Alar and Basal plates are connected via the roof plate.

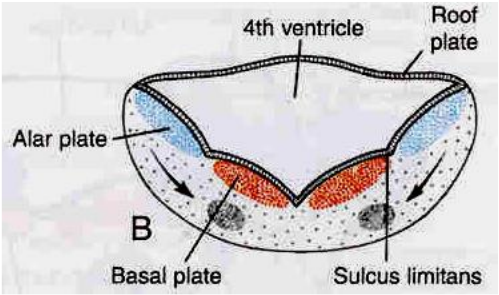

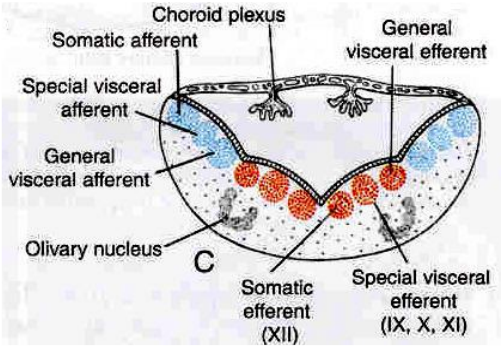

In contrast to the spinal cord however, the two Alar plates will migrate laterally extending the roof plate leading to a larger cavity which will develop into the fourth ventricle. In the case of the Medulla the Sulcus Limitans also appears here, which separates the sensory and motor nuclei from each other.

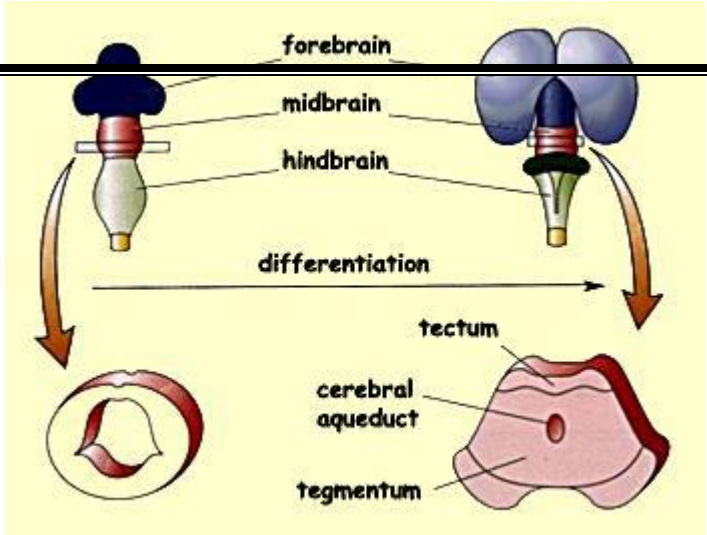

Between the fourth and fifth months in intrauterine life the connection between the fourth ventricle and the subarachnoid space begins to develop as the **Median Foramen of Magendie** and **the Lateral Foramina of Luschka** in the roof of the fourth ventricle. As you can see from the figure the choroid plexus also begins to develop in the roof of the fourth ventricle.

Development of the pons & cerebellum:

Going back to the table the Pons and Cerebellum are derivatives from the Metencephalon of the Rhombencephalon. Once again, we have we have two Alar plates lying dorsally and two Basal Plates lying ventrally and the central canal which will also develop into the floor of the fourth ventricle. In contrast to everything we stated in the case of both the spinal cord and the medulla, in the case of the pons and cerebellum the Alar plates grow **medially** to form 2 rhombic lips. These rhombic limps will enlarge and move towards each other to form the cerebellar plate. The cerebellar plate differentiates into a **median part** which forms the **vermis**, a **basal plate** which will form the **pons**, and **alar plates** which form the cerebellar hemispheres.

Development of Midbrain:

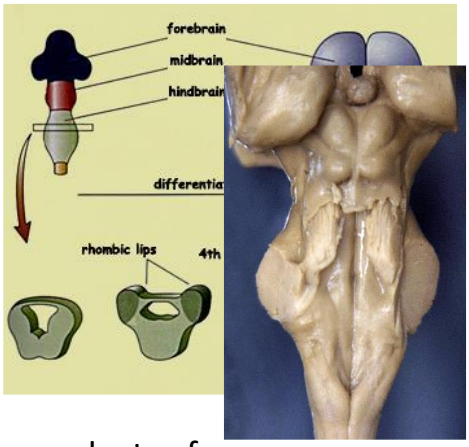

The midbrain is the only structure derived from the Mesencephalon, as you may have guessed once again, we have alar plates in the dorsal aspect of the midbrain and basal plates in the ventral aspect of the midbrain. Therefore, the **dorsal aspect** of the midbrain is named **Tectum,** the **ventral part** is named **Tegmentum** and the cavity between the two is the narrowest part of the ventricular system known as the cerebral aqueduct of Sylvius.

The Tectum/Posterior aspect of the midbrain has four rounded structures known as colliculi (two superior and two inferior), which play a role in both vision and hearing. On the other hand, the tegmental part of the Midbrain which lies anteriorly is formed by the basal plates.

Development of the Diencephalon:

The diencephalon develops from the median vesicles between the two telencephalic vesicles which are all derived from the Prosencephalon. The Diencephalon consists of two lateral walls connected by both a roof and a floor plate. The cavity that is found between the two lateral walls will narrow to form the third ventricle. The roof plate will be divided into an anterior part which develops into the choroid plexus of the third ventricle and a posterior part which will develop into the pineal body that lies in the posterior end of the thalamus. As you know we also have the hypothalamic sulcus which separates between the Thalamus above and the Hypothalamus below. This sulcus will develop between both in the lateral wall of the roof plate. Finally, the floor plate will develop into the posterior lobe of the pituitary gland.

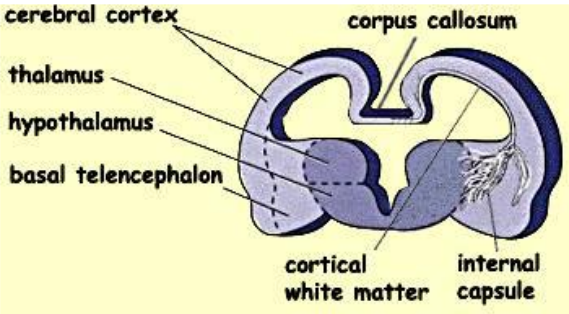

Development of the Pituitary Gland:

This is not included in our course as we took it extensively in the endocrine system.

Development of the Cerebral Hemisphere:

They are developed from the telencephalic vesicles which are developed from the proximal part of the neural tube (prosencephalic vesicle)

The cavity in each cerebral hemisphere expands to form the lateral ventricle .

The mantle layer of the neural tube;which gives rise to the grey matter ,will form the basal nuclei at the base of each cerebral hemisphere .

Lastly, the cerebral hemispheres enlarge and overlap the brain stem and the cerebellum.

So the end result the cerebral hemispheres are above and the brain stem and the cerebellum are inside and below the cerebrum.

Congenital Malformations of Brain Development:

1-Hydrocephalus: increased size of the head due to enlarged brain cavity inside the telencephalic vesicle
It is divided into two types:
-Internal Hydrocephalus: Excessive accumulation of CSF within the lateral ventricles of the brain (the cavity of the telencephalic vesicles)

-External hydrocephalus: Excessive accumulation of the CSF between the brain & arachnoid mater inside the subarachnoid space.

Signs and symptoms:
-Sunset appearance of both eyes
-Headache
-Vomiting

2-Exencephaly:
As mentioned before the neural tube has anterior and posterior neuropores which close at 25th and 27th day respectively.

It is due to failure of closure of anterior neuropore. The vault of the skull is absent & the brain is exposed.

When the brain is degenerated in Exencephaly the anaomaly is known as **Anencephaly**.

3-Meningeocele:
Failure of obliteration of the anterior neuropore and protrusion of the meninges through the deficient part of the skull

4-Meningoencephalocele:
If the sac that is herniated through a deficit in the skull (Meningeocele) has brain tissue inside it then it is known as meningoencephalocele
-Meningeocele+brain tissue= Meningoencephalocele

5-Meningo-hydro-enecephalocele: part of the ventricle is found within the brain tissue which herniated through the meningocele. This malformation is more dangerous than the previous case.

6-Holoprosencephaly: Results from degeneration of midline structures leading to fusion of lateral ventricles, orbital & nasal cavities

https://www.youtube.com/watch?v=Tp25wrm-AoA