Urogenital system

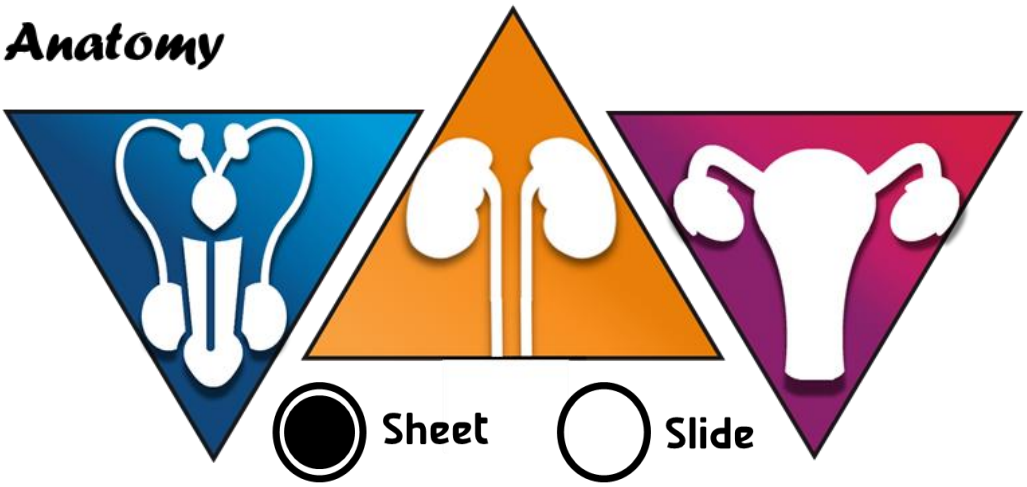

Number:	Histo 3 Online
Done by:	Mustafa Khader
Corrected by:	-
Doctor:	Dr. Ahmad Salman

The video of this lecture was only 15 minutes long therefore, the sheet will be fairly short. In previous histology lectures we discussed the histology of the renal system, male genital system, and in this lecture, we will discuss the histology of the female reproductive system. Please check the slides for pictures.

Let's start with a revision of the Female Reproductive System, it consists of:

1. Vagina
2. Uterus
3. A pair of Fallopian Tubes (which connect the ovaries to the uterus)
4. A pair of Ovaries

Histology of the Uterus:

The uterus consists of three parts:

1. Cervix
2. Fundus
3. Body

Subsequently, histologically its wall is composed of three layers:

1. **Endometrium**: The innermost layer of the uterus which can be divided into two layers:
    a. Functional Layer: The layer that is sloughed off during menstruation. Consists of:
        i. Surface epithelium
        ii. Lamina Propria: Containing glands.
    b. Basal Layer: Deep layer responsible for the regeneration of the functional layer following menstruation.

Before Puberty & Menopause :

-The Endometrium is lined with simple cuboidal with scanty spindle-celled stroma

- Contain rudimentary tubular glands which undergo cystic distention at menopause and fail to respond to estrogen and progesterone

During reproductive years:

-Epithelium is ciliated columnar cells and secretory columnar cells

Lamina propria composed of dense irregular connective tissue and vessels supports epithelium and houses simple coiled tubular glands

-The epithelium has (ciliated cells and non ciliated secretory cells)

2. **Myometrium**: Thickest layer of the uterus, from the prefix myo- we can conclude that it is a **muscular** layer. It is composed of three poorly defined areas which are separated by connective tissue:
    a. Stratum Submucosa: Thin inner layer composed of two layers arranged as **Longitudinal and Circular** muscle fibres
    b. Stratum Vasculare: Thick middle layer characterised by being highly vascular -hence the name- with irregularly arranged muscle fibres. Due to the fact that this is the most contractable layer. The fibres run **Longitudinally, Obliquely, Circularly, and Transversely**.
    c. Stratum Subserosum: The outer layer of myometrium and the majority of fibres are oriented **Longitudinally.**

    The myometrium is oestrogen dependant/sensitive, meaning that in its presence stimulation of the smooth muscle cells occurs leading to their hypertrophy and hyperplasia.

    During pregnancy the ability of the uterus to contract is inhibited by the hormone **Relaxin** which is secreted by the Corpus Luteum. On the other hand, during labour the hormone **Oxytocin** which is secreted by the Posterior Pituitary Gland induces contraction of the uterus.

3. **Adventitia:** Also known as Perimetrium and is the outermost layer of the uterus. This layer is of two types:
    a. If it is covered by peritoneum then it is called **Serosa**, which is a single layer of simple squamous mesothelium
    b. If the aforementioned layer of perimetrium is not covered by peritoneum then it is called **Adventitia**, which is composed of Areolar Connective Tissue.

Blood Supply of the Uterus:

As we know the blood supply of the Uterus is by the **Uterine artery**, the uterine artery penetrates the myometrium giving off **Arcuate arteries,** which then give rise to **Radial Arteries.** These radial arteries penetrate the endometrium giving rise to **Basal Arteries** that supply the basal layer of the endometrium, and then the Radial Arteries terminate as **Spiral Arteries** (coiled in shape) which supply the functional layer.

Uterine Arteries → **Arcuate Arteries** → **Radial Arteries** → **Basal Arteries** / **Spiral Arteries**

Menstrual Cycle: The menstrual cycle consists of four phases:

1. **Menstrual Phase:** Days 1-4
2. **Proliferative/Follicular Phase:** Days 5-14 of the cycle. This phase occurs due to the effects of **Eostrogen** that is secreted by the **Theca cells** of the ovarian follicles. This phase can be divided into two subphases:
    a. Early proliferative: Glands are small
    b. Late proliferative: Proliferation of the cells occurs leading to the formation of **simple columnar epithelium,** the glands also enlarge and become coiled in shape, and the spiral arteries begin to penetrate the functional layer.
3. **Ovulation:** Approximately occurs on the 14th day of the cycle
4. **Secretory/Luteal Phase:** Days 15-28 of the cycle. This phase occurs due to the effects of **Progesterone** secreted by the Corpus Luteum. In this stage the glands are coiled and filled with secretions, the spiral arteries are now coiled and penetrate the functional layer, and now the endometrium has reached its full thickness of approximately 5mm. After this phase we have two options:
    a. Fertilization occurs and the zygote is implanted into the uterine wall
    b. No fertilization occurs causing the breakdown of the Corpus Luteum, which leads to decreased levels of progesterone. This decrease in the levels of progesterone causes vasoconstriction of the spiral arteries supplying the functional area. This causes hypoxia and ischemia to the cells of the functional layer leading to their necrosis and

they start to slough off and bleed in the phase of menstruation.

- **Uterine Cervix:** Histologically the cervix consists of a mucosa, musculosa, and adventitia. It is important to know that unlike the mucosa of the fundus and body of the uterus, the mucosa of the cervix **does not** slough off during menstruation. The glands located within the cervix are **branched tubuloalveolar** glands which secrete mucus. This mucus is thin in mid-cycle, however; following ovulation the mucus secretions become thick. If obstruction of the glands occurs for any reason it will give rise to **Nabothian Follicles.** The lamina propria of the cervix contains connective tissue, elastic fibres, and muscle fibres. Finally, the musculosa consists of inner circular and outer longitudinal muscle cells. Softening of cervix during parturition is due to lysis of collagen

The cervix consists of two parts:

1. Endocervical Canal: Located inside the Uterus and is lined by **simple columnar partially ciliated** epithelium
2. Vaginal part: As the name suggests is located inside the vagina and therefore has the same lining has the vagina which is **stratified squamous non-keratinized** epithelium.

Between the previous two layers there is a transitional zone of epithelium.

- The transition zone shows nabothian follicles or cyst (result from occlusion of ducts of mucosal glands)
- It most common also site for development of cervical cancer

Uterine Tube: Also known as the fallopian tube which as stated in the beginning of this sheet connect the ovaries to the uterus and it important to know that it pierces the peritoneum. This tube is composed of four parts:

1. Intramural segment: related to the uterine wall
2. Isthmus: adjacent to uterine wall

3. Ampulla: Most dilated part
4. Infundibulum: Funnel shaped segment near the ovary but not in direct relation (does not touch the ovary) contains fimbria, to "pick up" the oocyte after ovulation.

The layers of the tube are as follows:

1. Mucosa: Lined by **simple columnar** epithelium which is **partially ciliated** in some areas. The non-ciliated cells contain microvilli on their surface and are called **peg cells.** are secretory cells that produce a watery tubal fluid which nourish spermatozoa ,zygote
2.
3. The mucosa is characterized by having folds along the length of the uterine tubes.
4. Musculosa: consists of inner circular and outer longitudinal layer of cells. The peristaltic movement of this layer together with beating movement of the cilia causes the pushing of the oocyte throughout the tubes and into the uterus
5. Serosa: Due to the fact that is covered by peritoneum it is comprised of simple squamous mesothelium and contains the blood vessels and nerves to the fallopian tubes.

Vagina: is a muscular tube connecting the cervix with the external female genitalia. It is composed of three layers:

1. Mucosa: the surface epithelium is **stratified squamous non-keratinized** epithelium. Lying under the surface epithelium is the lamina propria containing dense connective tissue and a vast network of elastic fibres. A characteristic of the mucosa of the vagina is that it does not contain glands. Therefore, the secretions that are found in the vagina are either from transudates of the blood vessels in the lamina propria or the secretions of the cervical glands. The thickness of the mucosa differs by age, in prepubertal and postmenopausal females the mucosa is thin, and in females in the reproductive age it is thick. This is due to either an increase in the mitotic activity of the basal cells or parabasal cells or hypertrophy of the superficial cells due to accumulation of lipids within the cells.

2. Musculosa: Inner circular and outer longitudinal cell layers
3. Adventitia: Rich in elastic fibres to allow its distention during labour and child birth.

This is my last sheet in the basic years, I would like to apologize for any mistakes I made in any previous sheet throughout the past three years and would like to wish you all three more years filled with success and achievements.

Sincerely,

Your colleague: Mustafa Salah Khader