Urogenital system

PBL

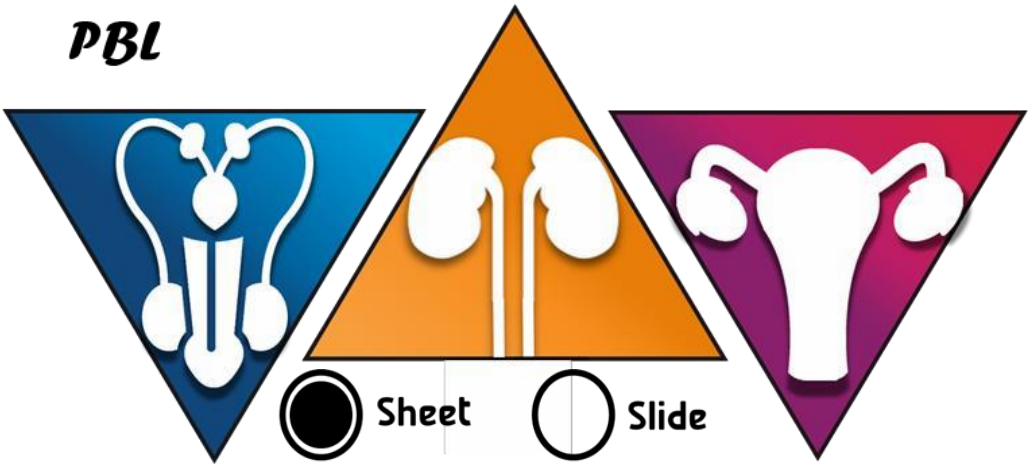

Number: -1

Done by: - Nancy Ayyad

Corrected by: - Yaseen Fatayer

Doctor: -

UGS Applicable Cases

We'll start talking about some cases that have the **same presentation** but the **diagnosis** of patent A is **different** from patent B. we'll discuss **why** that is happening, and we'll start looking for the "**clue**" for each situations.

other thing we should consider is **age**; pediatric, adolescence and elderly have causes and situations different from each other.

The following cases show the importance of urine analysis as mirror or magnifier to see inside the kidney.

Case #1

***23** yrs old male, previously healthy*, c/o Rt loin pain of 2 days duration and noticed blood in the urine. What is your next step?*

*not diabetic/ not hypertensive/ does not have autoimmune diseases.

*you sent for him a **urinalysis** and it showed:*

nil protein, nil sugar, 10-20 RBCs, WBCs 4-5.

- we can say it's not infection. Why? Because WBCs should be more in case of infection. **Not UTI**.
- no protein and sugar in urine means it is not a systemic disease. **Not Glomerulonephritis.**

so it is something local in the urinary tract that cause some RBCs appear in urine. according to age: most common cause of hematuria in this age group is **stones**.

Case #2

***56** yrs old male, previously healthy*, c/o Rt loin pain of 2 days duration and noticed blood in the urine. What is your next step?*

Age totally change the situation and the way of thinking about the case.

*you sent for him a **urinalysis** and it showed:*

nil protein, nil sugar, 10-20 RBCs, WBCs 4-5.

Diagnosis is totally different between both age groups:

- we can exclude prostatitis. Why? Patent didn't have symptoms like frequency and urgency (same symptoms of UTI). also prostatitis dose not cause blood in urine.
- so is it Kidney Stones or Renal Cell Carcinoma?

the most common in this age group and the most serious is **Renal Cell Carcinoma**.

Case #3

***30** yrs old male previously healthy, c/o Rt loin pain of 2 days duration, he noticed blood in the urine. Your next step was to send a urinalysis for him. Results showed :*

+2 protein, nil sugar, 10-20 RBCs, 4-5 WBCs.

Probably **Glomerulonephritis**.

The key is **proteinuria** and RBCs. Proteinuria only happen with defect in the filtration barrier.

Case #4

***30** yrs old male previously healthy, c/o sudden sever Rt loin pain, then noticed blood in the urine.*

when you sent urinalysis for him it was the same as the one in case #3. What is next?

sudden sever pain is common with **Renal Infarction** or **Renal Vein Thrombosis**.

usually after heavy nephrotic syndrome.

Case #5

***30** yrs old male, previously healthy, noticed blood in the urine. Urinalysis showed : protein nil, sugar nil, RBCs 1-2, WBCs 1-2. What is next?*

Thin basement membrane disease- Benign familial condition of recurrent hematuria.

these patients need **observation** and you have to **illustrate the history of the family** to make sure that the hematuria caused by thin basement disease or other cause.

Case #6

***70** yrs old male presented to the clinic with painless attacks of bloody urine and urgency. His urinalysis showed no sugar, +1 protein, but 10-15 RBCs, and 20-25 WBCs.*

Most likely UTI - cystitis.

- WBCs and some RBCs with irritation (urgency). But why painless? maybe the patient is diabetic or have some neurologic disease.

These cases just to learn how to think about the case. In the clinic, before urinalysis you should take full history, do physical examination and set differential diagnosis then you order some test to supply it.

Case #7

***70** yrs old male presented to the clinic with painless attacks of bloody urine, and history of passing clots.*

his urinalysis showed numerous RBCs, 8-10 WBCs, and numerous epithelial and transitional cells.

Transitional Cell Carcinoma. (a lot of epithelial and transitional cells in urine).

What is urinalysis? test of 2 parts: **Dipstick** part - when urine reacts with certain factors, and **Microscopy** part.

* dipstick alone is not enough.

dipstick	microscopy
• Blood -ve • Ketones -ve • Glucose^ -ve • Protein -ve or trace~ • pH 5.0 to 8.0	• Cells: rare red cells (<<1/hpf*); squamous cells. • CastsHyaline • Crystals – Calcium oxalate.

Normal Urine

*High Power Field.

^sugar in urine is a mark for diabetes or proximal convoluted tubule syndrome (aka Fanconi syndrome- inadequate reabsorption in the proximal tubules *where sugar is reabsorbed*)

~ protein could be found with small amounts in healthy people due to: fasting/ dehydration/ pregnancy…

- **cells** (of microscopic part):

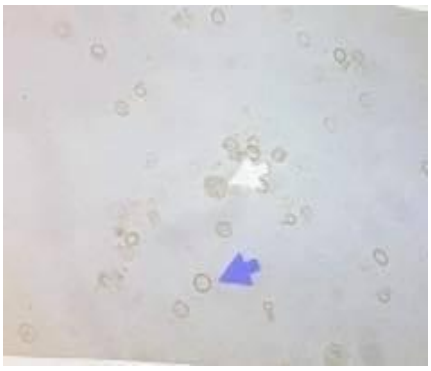

pic#1

blue arrow- **RBC** : small, distinct cell membrane, clear cytoplasm.

3 RBCs (maximum) per high power field is normal.

hematuria could be microscopic not seen grossly. The **shape** of RBCs could be **normal** or **dysmorphic**, and each one is **indicative** for different disease.

normally shaped RBCs indicate stones/ renal cell carcinoma/ ureteric infection or obstruction/ something in the bladder.

while dysmorphic RBCs indicate glomerular diseases. (the red blood cell have to cross the filtration barrier – capillary fenestrated endothelium بتحشر then the basement membrane then the podocytes so the cell between these structures becoming dysmorphic – abnormal RBC حالها shape).

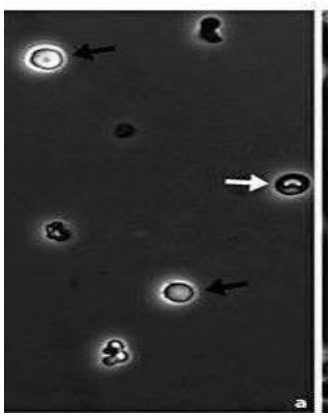

pic#2 (not the same pic used by the doctor)

white arrow- dysmorphic RBC (like RBCs in sickle cell anemia)

white arrow in pic#1- **WBC**: larger, less distinct cell membrane, granular cytoplasm. More than 1-2 at the field indicate **UTI** with candida or yeast.

pic#3 budding yeast

#3 budding yeast

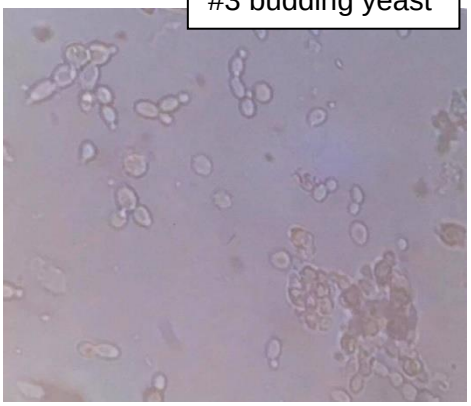

note they are similar in size to RBC but often in **chains**. **squamous cells**- large, polygonal cells from uroepithelium.

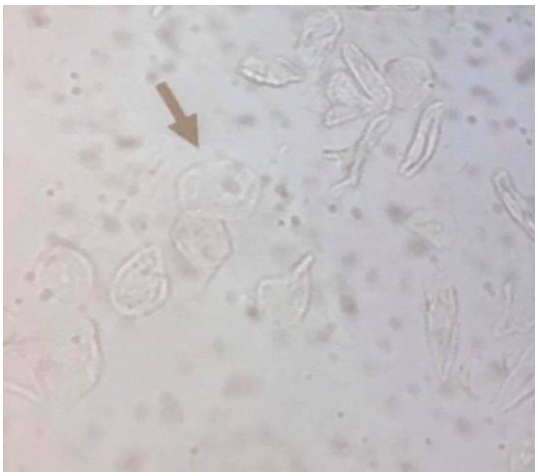

pic#4

1-2 cells is normal (flushed with urine), more than that indicate **malignancy**(e.g. penile malignancy).

- **Acellular casts**

- Hyaline cast :

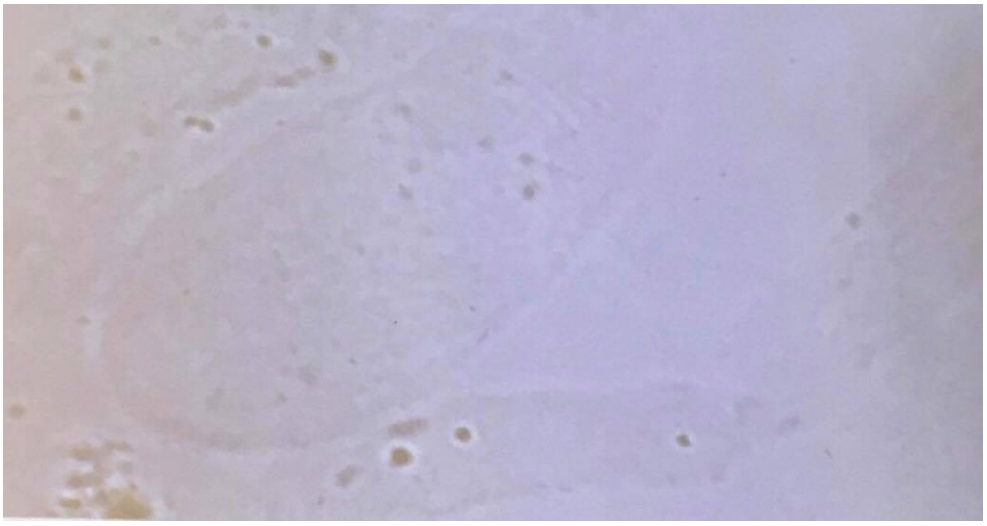

pic#5

normal in urine, common in highly **concentrated urine**: probably due Tamm-Horsfall protein (produced by the tubules). (appear with dehydration and fever too).

- Granular Cast :

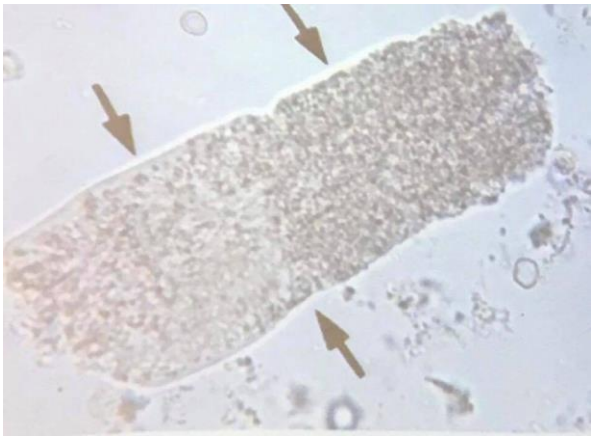

pic#6

abnormal but **non-specific**.

- Heme Granular Cast : heme-pigmented granular cast

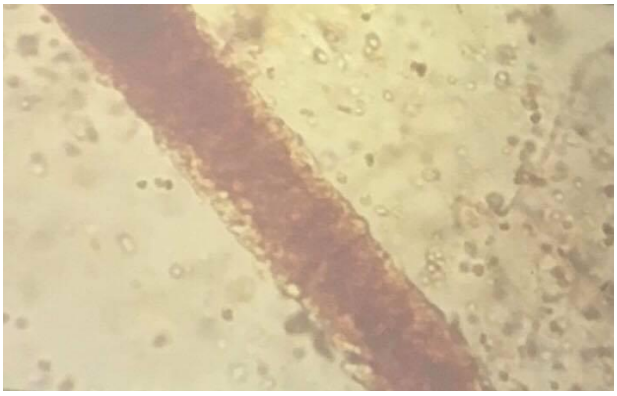

pic#7

most common with **Acute Tubular Necrosis**.

- Lipid Cast :

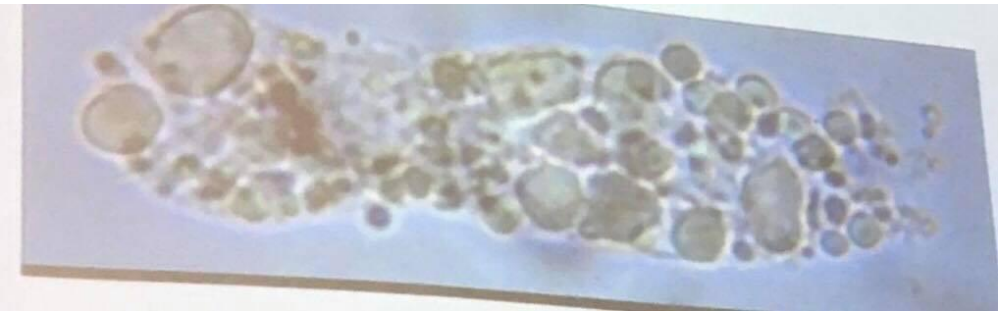

pic#8

seen in **nephrotic syndrome**; dipstick protein >3 g/L. (the loss of

proteins stimulate the liver to compensate so it synthesize all its products including lipids).

note variable size of droplets of lipid.

oval fat body/ lipid droplets: are oval, round or cast-shaped dark object with small "bubbles" within.

pic#9

- **Cellular cast**

- WBC Casts :

pic#10

seen in: **pyelonephritis** (upper UTI)/ allergic interstitial nephritis/ granulomatous interstitial nephritis.

- RBC Cast :

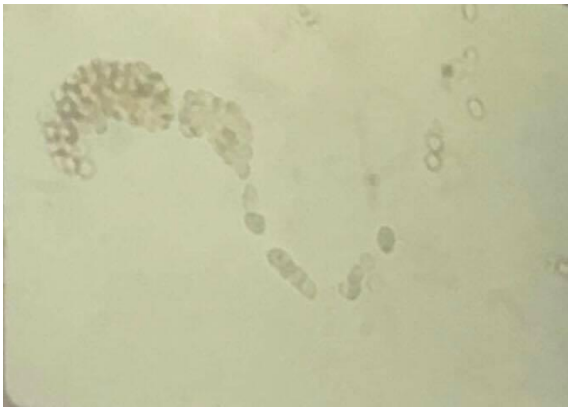

pic#11

not numerous, seen in proliferative or necrotizing GN.

+ve dip for blood.

- Bacteria :

always abnormal, if associated with white cells **suggest UTI**.

look for movement of bacteria.

bacteria in urinalysis **not indicative for UTI.** You need +ve culture.

- **Crystals**

- Calcium Oxalate :



pic#12

seen in **normal** urine. If numerous suspect **ethylene glycol poisoning**. (used as anti-freez)

- Uric Acid

- Triple phosohate :



pic#13

) التابوت زي الشكلseen with **chronic UTI**. (

- Cysteine :



pic#14

rare, autosomal recessive **genetic disorder**.

- Mucous :

Seen in **men**

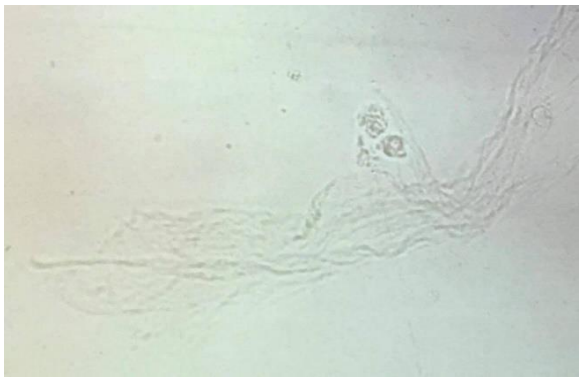

إن لم تكن زائدة على هذه الحياة شيئاً عليها

♦ good luck♦

Nancy Ayyad.