Urogenital system

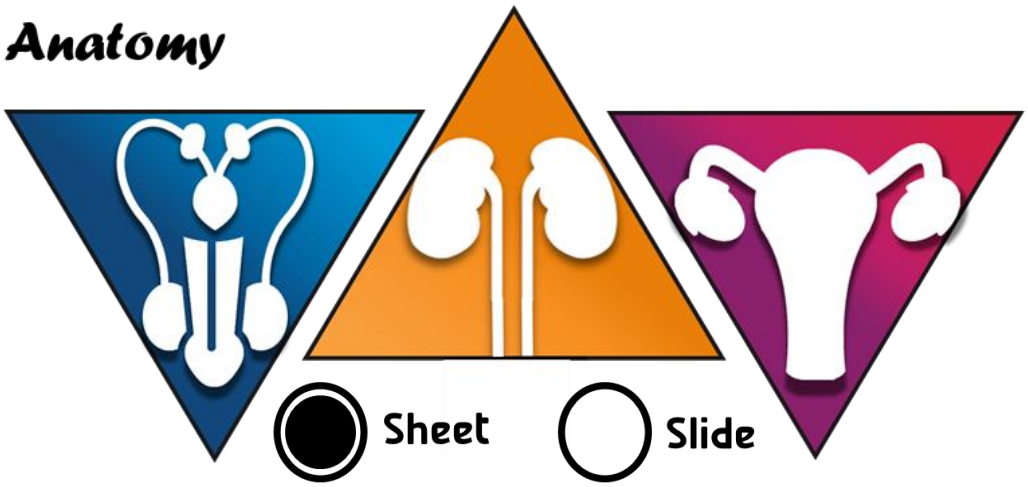

Number: - Hitology 1

Done by: - Anas Raed

Corrected by: - Zaid Emad

Doctor: - Ahmad Alsalman

yone, hope you are doing well!

This will be my last sheet in the basic years. I tried to make it as easy as I could.

This lecture will be about the histology of the Urinary system .If you have any question, you are more than welcome to contact me.

Let's get the party started...

As we know the urinary system is composed of: 2 kidneys, 2 ureters, one bladder & one urethra.

Functions of the Kidney:

1. Controlling the water and electrolytes balance.
2. Regulating the extracellular fluid volume.
3. Eliminating waste products, toxins and drugs; most importantly Urea.
4. Controlling the acid-base balance of blood.
5. Has a hormonal and metabolic function like:
   - Secretion of **Renin** by juxtaglomerular cells which regulate blood pressure.
   - Secretion of **Erythropoietin** that stimulates the production of erythrocytes in the bone marrow and thus regulates the oxygen-carrying capacity of the blood.
   - Conversion of pro-hormone **Vitamin D** to the active form which regulates calcium balance.

Kidney structure:

Like any organ, the kidney has: An **external capsule**, and this capsule sends **trabeculae** inside the kidney, also, it has the **reticular stroma** that retains the shape and the structure of the kidney, and it has a functional unit that is responsible for the secretion of urine and it's called **Uriniferous tubule**.

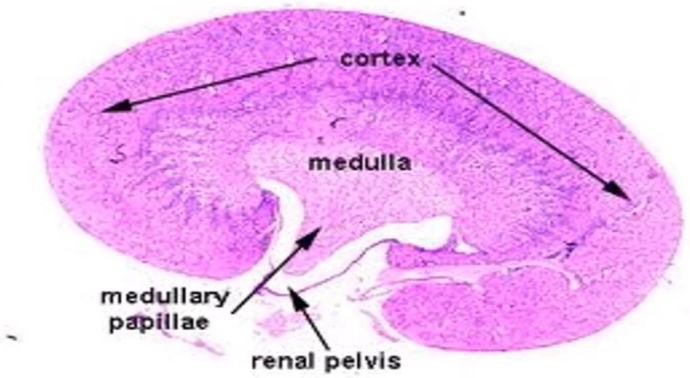

The Kidney General Structure:

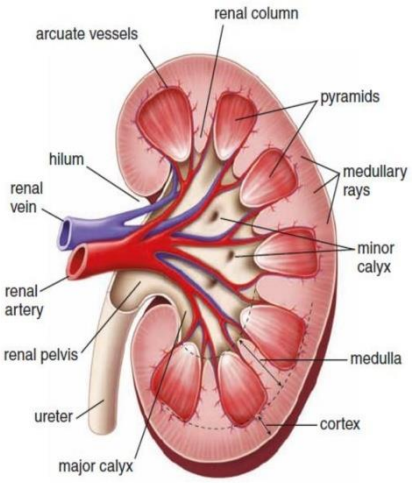

- The kidney is composed of an **outer cortex** and **inner medulla.**
- The medulla is arranged into pyramids, and these pyramids have an **apex** (the tip of the pyramids) and it is called **renal papillae** and these renal papillae open into **minor calyx** and this minor calyx opens into **major calyx** which opens into the **renal pelvis** that opens into the **ureter.**
- The area at the **base** of the renal pyramid makes extensions into the cortex and they are called **medullary rays.**
- Between the renal pyramids there is another extension from the cortex and it's called **renal column**.

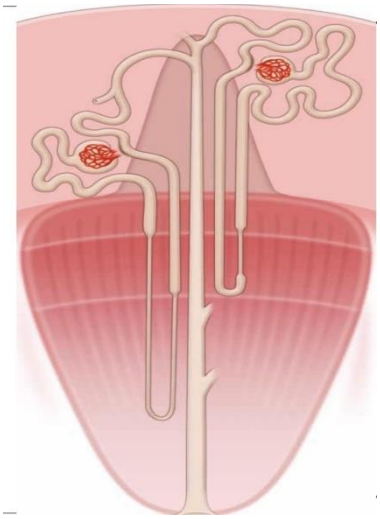

- The **renal lobe** is composed of the renal pyramid and renal column, while the **renal lobule** is composed of medullary rays and the overlying cortex.

Uriniferous tubule:

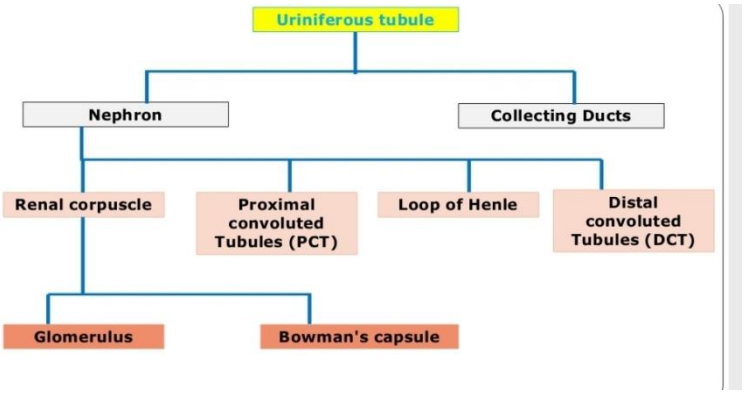

- It's composed of two main parts: the **Nephron & the Collecting Ducts.**
- The nephron is composed of 4 parts which are: **Renal corpuscle, Proximal convoluted Tubules (PCT), Loop of Henle & Distal convoluted Tubules (DCT).**
- The renal corpuscle is composed of: **Glomerulus and Bowman's capsule.**

- Bowman's capsule is attached to PCT which in turn is attached to the thick descending loop of Henle and continues as the thin descending part of loop of Henle which is continuous with the ascending thin part which is also continuous with the thick ascending part which will attach to the DCT that ends into collecting tubule which terminates as the collecting duct.
- In the **cortex** we will find renal corpuscle, PCT and descending thick loop of Henle, while in the **medulla** we will find the descending and ascending loops of Henle.
- DCTs are located in the cortex.

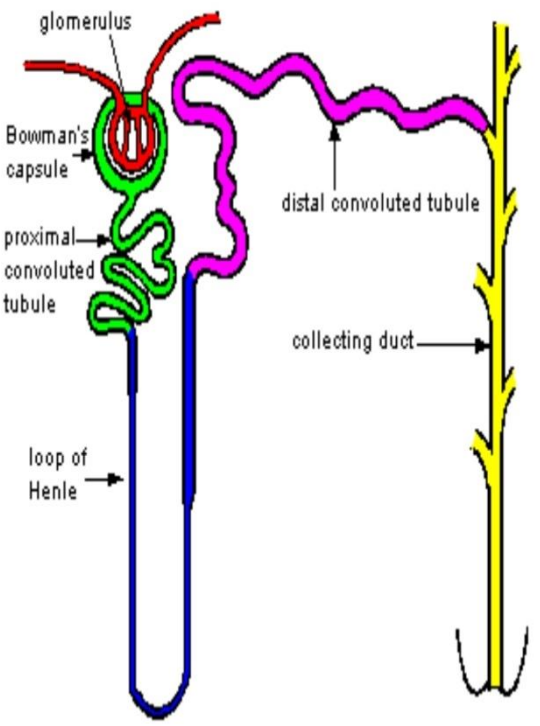

<u>The Nephrone:</u>

The nephrones have two types according to their position:

1- Cortical:

Mainly found in the cortex and loop of Henle here is short.

2- Juxtamedullary:

It's found at the border between the cortex and medulla, so, it has very long loop of Henle.

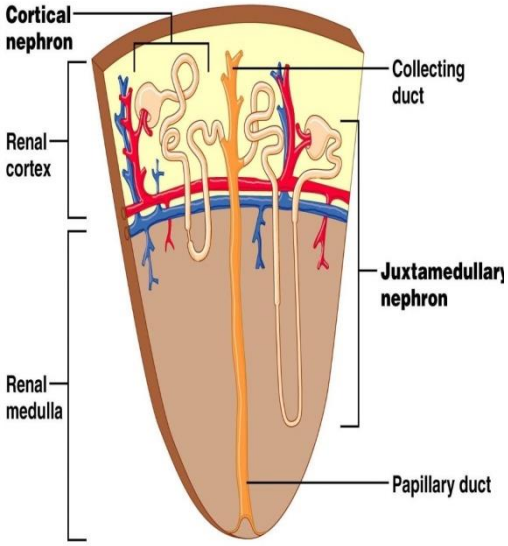

- The number of nephrons decreases slightly in older adults, a process accelerated by high blood pressure.
- In case of (unilateral nephrectomy), as in kidney donation for transplant the remaining kidney undergoes compensatory growth with cellular hypertrophy in the proximal parts of the nephron tubules and an increase in the rate of filtration, which allow normal renal function to continue.

Renal corpuscle:

It's formed mainly by 2 parts:

1- Bowman's capsule.
2- Glomerulus.

Function: Filtration of the blood and formation of urine.

Bowman's capsule:

It is composed of 2 poles:

1- A urinary pole that is attached to the PCT.
2- A vascular pole directed towards the capillaries (afferent and efferent arterioles).

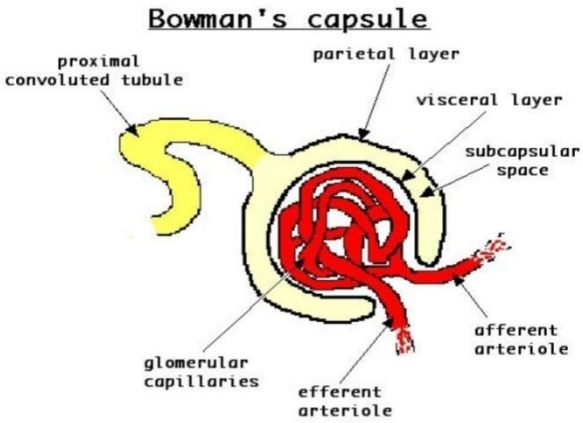

It's lined by 2 layers:

1- **An Outer Parietal layer (capsular epithelium):**
It is lined by **simple squamous epithelium**.
2- **An inner Visceral layer (glomerular epithelium):**
It is lined by specialized epithelial cells called **podocytes.**

- In between of the two layers, there is the **capsular space** which receives the fluid filtered through the capillary wall and visceral layer.

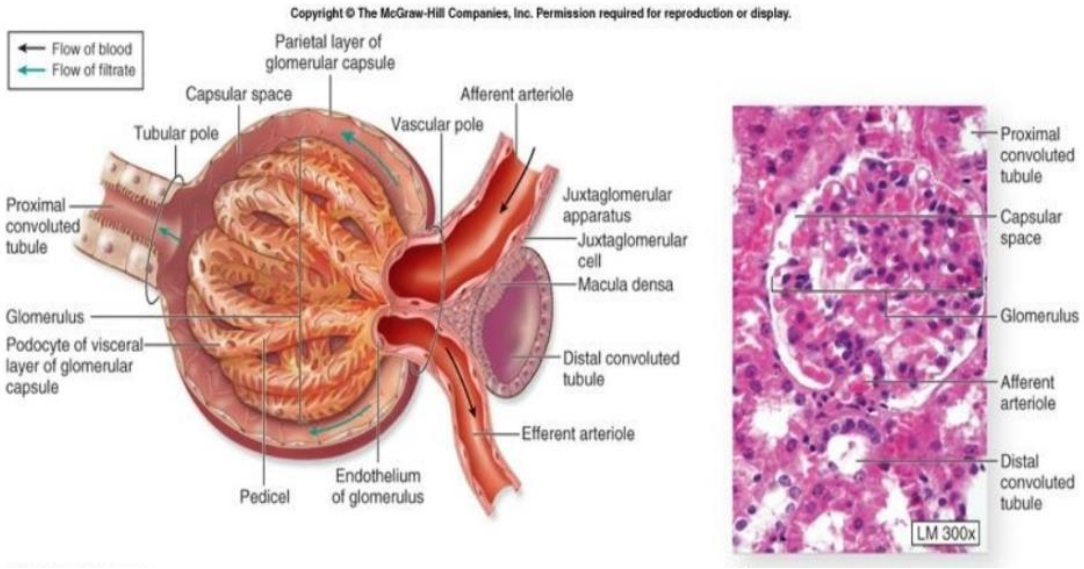

Podocytes:

- Podocytes are modified epithelial cells that have numerous **long primary cytoplasmic (major) processes**, and each primary process has many **secondary processes** called **pedicels** which:
  1- Completely envelop the glomerular capillaries.
  2- Terminate around BM of glomerular capillaries.
- The spaces between the minor processes are called **filtration slits** which are closed by **slit diaphragm**
- The secondary processes and the filtration diaphragm are lined with the **basal lamina** of the blood capillaries, which are lined from the inside with **fenestrated endothelium.**

  Function of Podocytes:
  1- Play an important role in filtration.
  2- Renewal of glomerular capillaries BM.

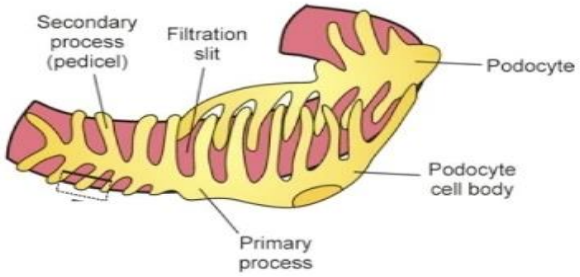

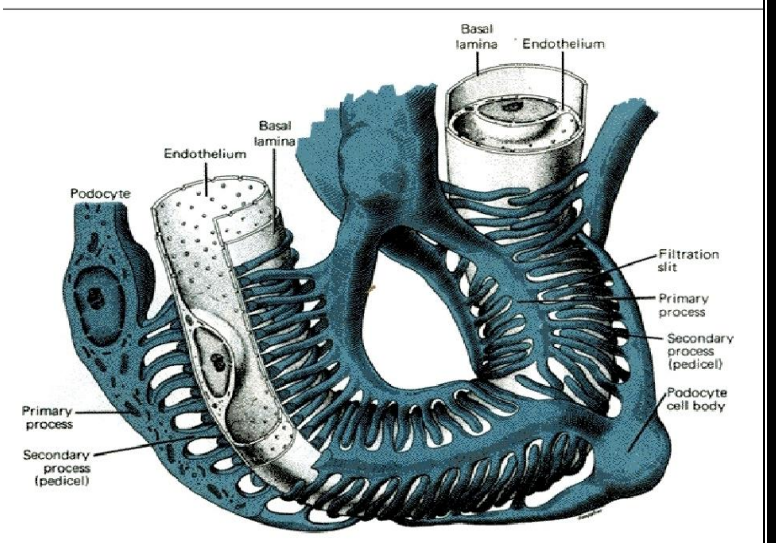

Glomerulus:

It is composed of tortuous capillary loops & it has efferent and afferent arterioles.

Capillaries are lined with fenestrated endothelium and has a thick basement membrane.

Mesangial Cells:

They appear in two regions:

1- Intraglomerular :

- Between the capillaries.

2- Extraglomerular:

- At the vascular pole between the efferent and afferent arterioles.

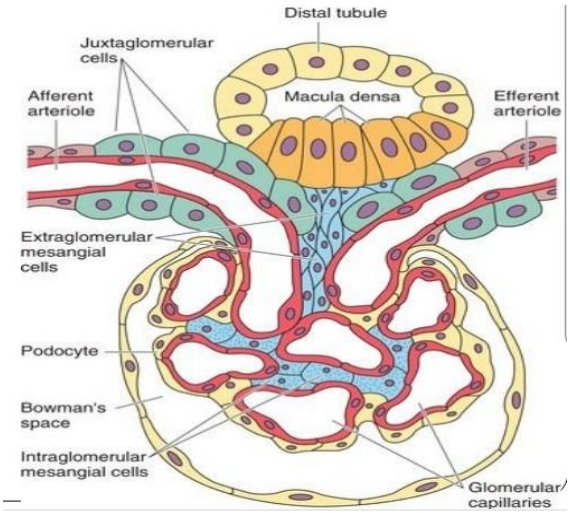

- Function :
  1- Participate in maintenance of basement membrane through phagocytosis and structural support.
  2- Physical support of capillaries within the Glomerulus.
  3- Has a role in immune defence and repair in the Glomerulus.
  4- Adjusted contractions in response to blood pressure changes, which help maintain an optimal filtration rate.
- Now we will start with the second part of the lecture which is about the renal blood barrier.

Renal blood barrier (Filtration barrier):

It's between the **Podocytes** lining the visceral layer of Bowman's capsule and the **blood capillaries** in the Glomerulus.

- As we said before, the blood capillaries have thick basement membrane and it is lined by fenestrated endothelium.
- The Podocytes have large processes and small pedicles that have small spaces in between called filtration slits and it's covered with slit diaphragm.

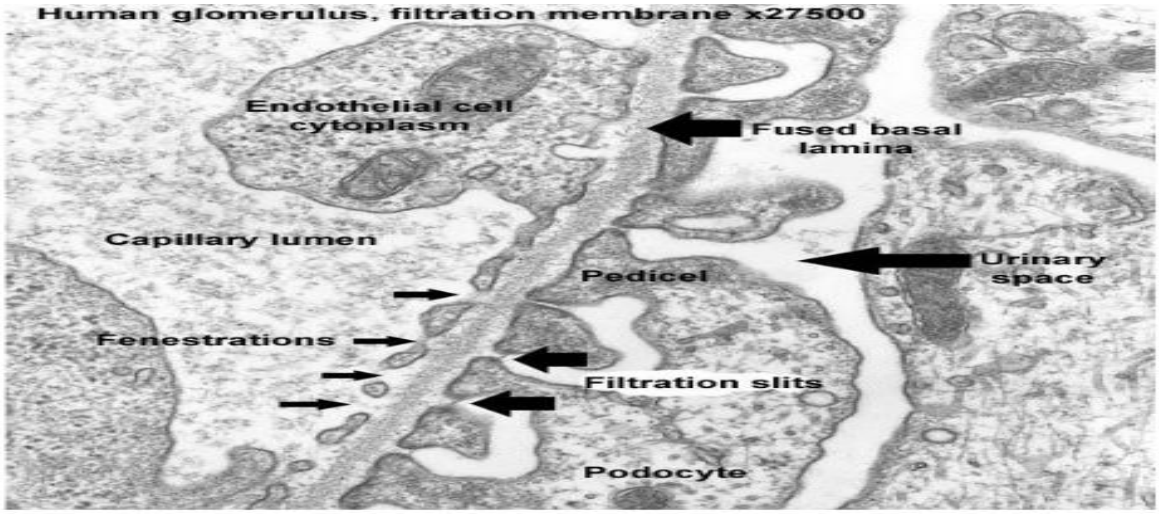

- Layers of the BRB:

  1- Fenestrated endothelium:

  It prevents the passage of RBCs, but anything less than the RBCs diameter can pass through it.

  2- **Basement membrane** that has 3 layers:
     1- Lamina rara interna→ towards the endothelium.
     2- Lamina rara externa→ towards the Podocytes.
     3- Lamina densa in between the interna and externa.
- Both laminae; interna and externa appear light, while lamina densa appears darker.

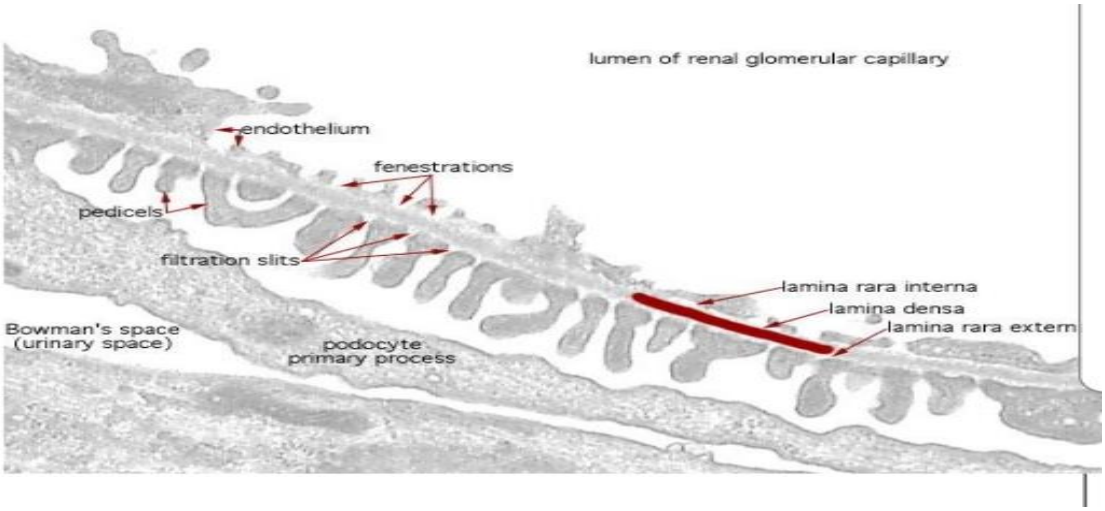

  3- **Filtration slits and slit diaphragm:**

  - Are modified occluding or tight junctions composed of **nephrins**, other proteins, glycoproteins, and proteoglycans important for renal function.
  - A thick glomerular basement membrane lies between the highly fenestrated endothelial cells of the capillaries and the covering podocytes
  - This basement membrane restricts passage of proteins larger than 70 kDa (Kilodalton)
  - Smaller proteins that are filtered from plasma are degenerated , and the amino acids reabsorbed

- Functions of the filtration barrier:
  1- Filters blood plasma.
  2- Allows water, ions & small molecules to enter the capsular space.

3- Prevents large plasma proteins from entering the capsular space.

- In case of Diabetes mellitus and glomerulonephritis :
  The glomerular filter is altered and becomes much more permeable to proteins, so the patient has **(proteinuria).**

  <u>Renal Tubules:</u>

  1- PCT is found mainly in the cortex.
  2- Loop of Henle has two parts: thick & thin loops.

- The thick loop is found in the junction between the cortex and the medulla (medullary rays).
- The thin loop is found mainly in the medulla

  3- DCT is found mainly in the cortex and it opens into the collecting tubules in the medullary rays and the collecting tubule continues its way to the collecting duct in the medulla.

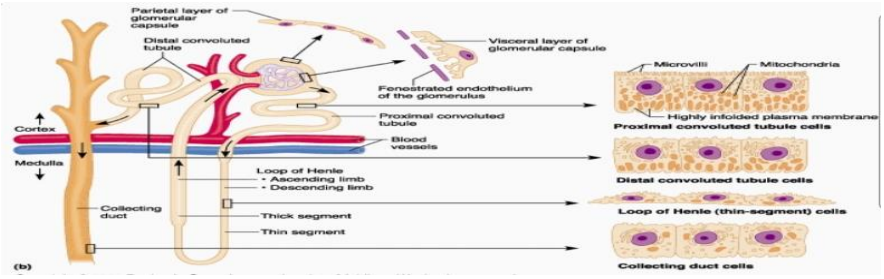

- The following table is for memorization sadly but you can look at the pics on the right at first to make it easier:

Region of Tubule	Histological Features	Locations Major	
PCT	Simple cuboidal epithelium; cells well-stained, with numerous mitochondria, prominent basal folds and long microvilli, lumens often occluded	Cortex	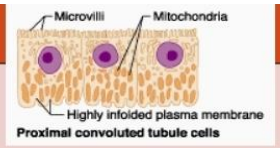
Loop of Henle Thick limbs	Simple cuboidal epithelium; no microvilli, but many mitochondria	Medullary rays and Medulla	
Loop of Henle Thin limbs	Simple squamous epithelium; few mitochondria	Medulla	
DCT	Simple cuboidal epithelium; cells smaller than in PCT, short microvilli and basolateral folds, more empty lumens	Cortex	
Collecting system **Principal cells**	Cuboidal to columnar pale-staining, distinct cell membranes	Medullary rays and medulla	
Intercalated cells	Few and scattered; slightly darker staining		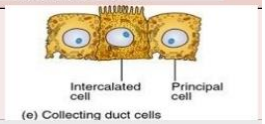

- In the collecting system: the part of epithelium that is directed away from DCT is columnar epithelium.

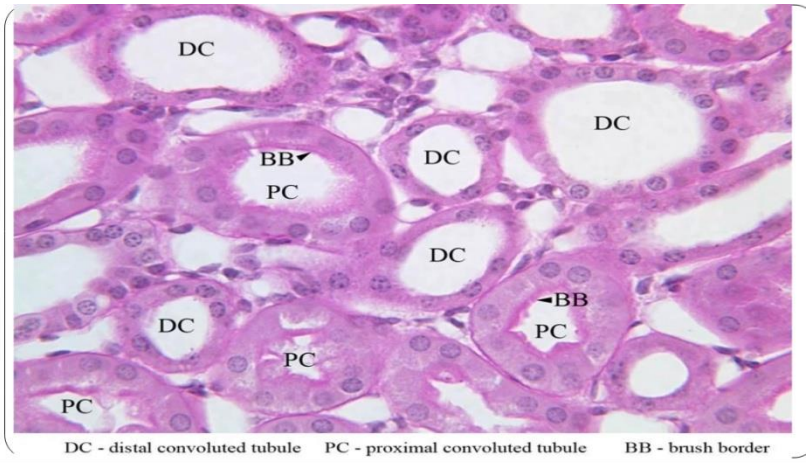

- Some notes to make identification easier:
  1- PCTs have a very obvious brush border unlike DCTs.
  2- PCTs have narrow lumen in comparison with the DCTs.

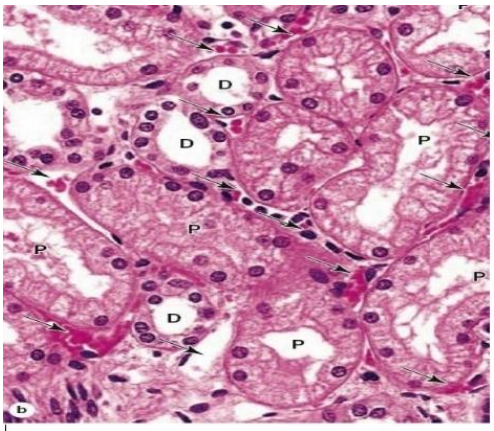

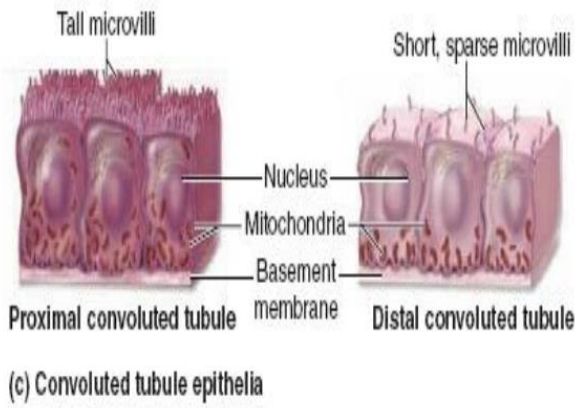

Abundant peritubular capillaries and draining venules (arrows)
Proximal (P) Distal (D) convoluted tubules

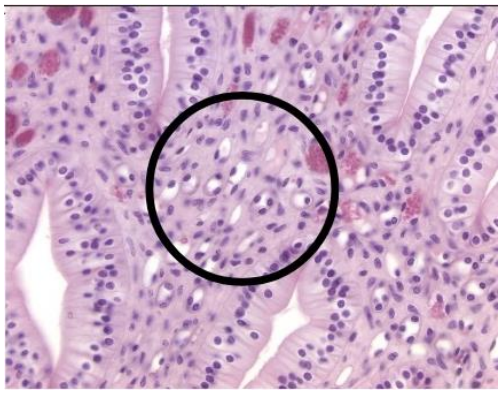

Loop of Henle:

- Present between the proximal and distal convoluted tubules.
- A U-shaped structure with;
  1- A thick descending limb.
  2- A thin descending limb.
  3- A thin ascending limb.
  4- A thick ascending limb (TAL) with simple cuboidal epithelium.
- The thin parts are lined by simple squamous epithelium.
- The nuclei of the cells lining the thin limbs bulge into the lumen of the tubule; these limbs resemble capillaries in cross section.

The collecting system:

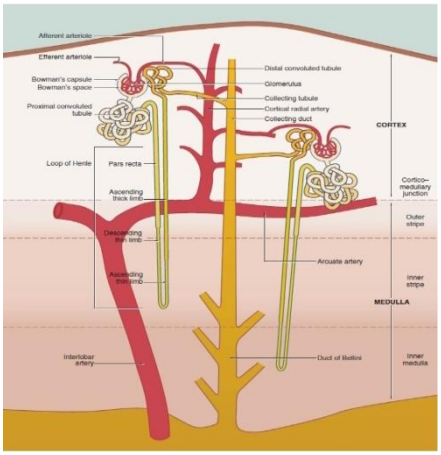

- It is mainly composed of **collecting tubules and collecting ducts.**
- The collecting tubules are found in the cortex and they connect the DCT with the collecting ducts.
- The collecting ducts have 2 parts, one in the medullary rays lined with **simple cuboidal** epithelium, and the other is the **medullary collecting ducts** with the transformation of the epithelium into **columnar**.
- The medullary collecting ducts are parallel to the loop of Henle.
- Finally they reach the papillae of the pyramids to open into the minor calyx through **ducts of Bellini**.
- Collecting ducts **have prominent cell borders** unlike the PCT & DCT.

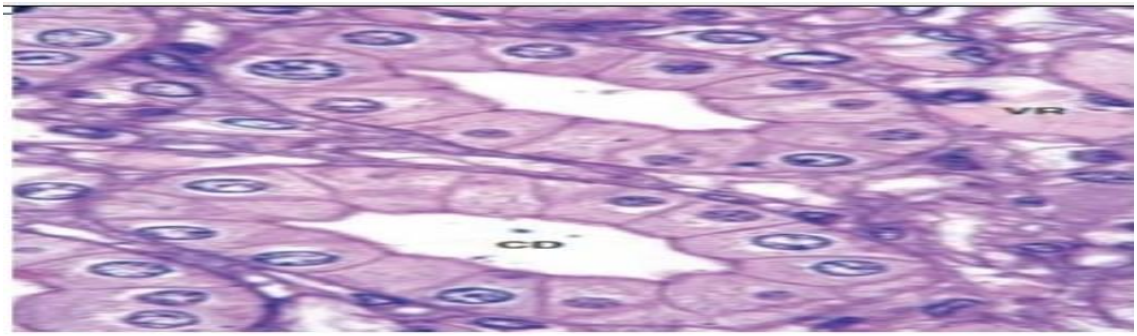

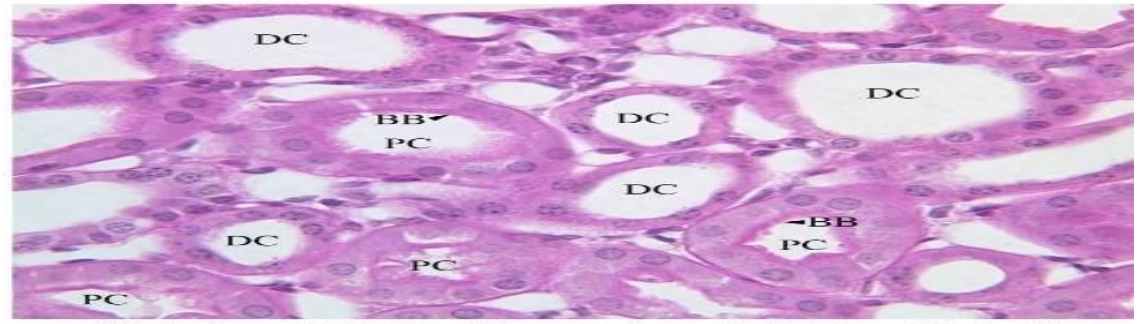

DC - distal convoluted tubule PC - proximal convoluted tubule BB - brush border

- Collecting tubules have 2 types of cells:

1- Principal (light) cells:

- Cuboidal, then increase in tall distally to become columnar.
- Central round nuclei.
- Light cytoplasm.
- Basal infoldings.
- Short microvilli.

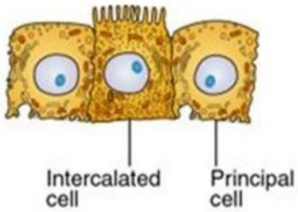

Function:

1- Reabsorption of Na+ and secretion of K+.
2- Respond to aldosterone and ADH to control the volume of the urine (the main function).

2- Dark (intercalated) cells:

- Rich in organelles.
- Well developed microvilli.
- No basal infoldings.

Function: Maintain acid-base balance by secreting either H+ (from type A or α intercalated cells) in case of **alkalosis,** or HCO3 – (from type B or β intercalated cells) in case of acidosis.

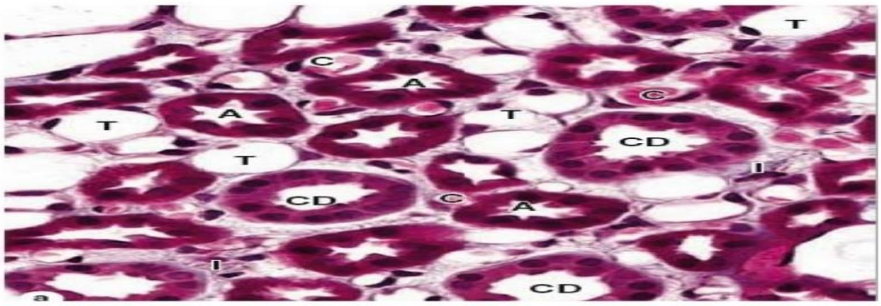

A micrograph of a medullary renal pyramid cut transversely
Thin descending and ascending limbs (**T**)
Thick ascending limbs (**A**),
Vasa recta capillaries containing blood (**C**)
Collecting ducts (**CD**).

JuxtaGlomerular apparatus:

- Function: It is involved in the regulation of systemic blood pressure.
- It is located between glomerular afferent arteriole and distal convoluted tubule of corresponding Nephron.
- It is composed of 3 structures:

1- Macula densa:

- It is an area of closely packed, specialised cells lining the DCT close to the vascular pole.
- They are columnar, crowded with prominent deeply stained nuclei.
- It is sensitive to the concentration of sodium ions in the fluid within the DCT.

2- Juxta-glomerular (JG) cells (Renin producing cells):

- They are modified smooth muscle cells found in the afferent arterioles mainly but sometimes they're found in the efferent arterioles.
- They have features of myoepithelial cells with rounded nuclei and granular cytoplasm.

- Contain mature and immature membrane –bound granules of the enzyme renin.

3- Extraglomerular mesangial cells (Lacis cells):

- Formed of a mass of small cells with pale nuclei.
- Found in the triangular region between the afferent and efferent arterioles at sides and macula densa at the base.
- The apex of the triangle is formed by the glomerular mesangial cells at the vascular pole.

The three structures of the JG complex are in direct contact with each other.

Functions of the JG complex:

1- Secretion of erythropoietin.
2- Secretion of renin to regulate blood pressure.
3- Regulation of Glomerular filtration rate by controlling the contraction of the JG cells in the efferent and afferent arterioles.

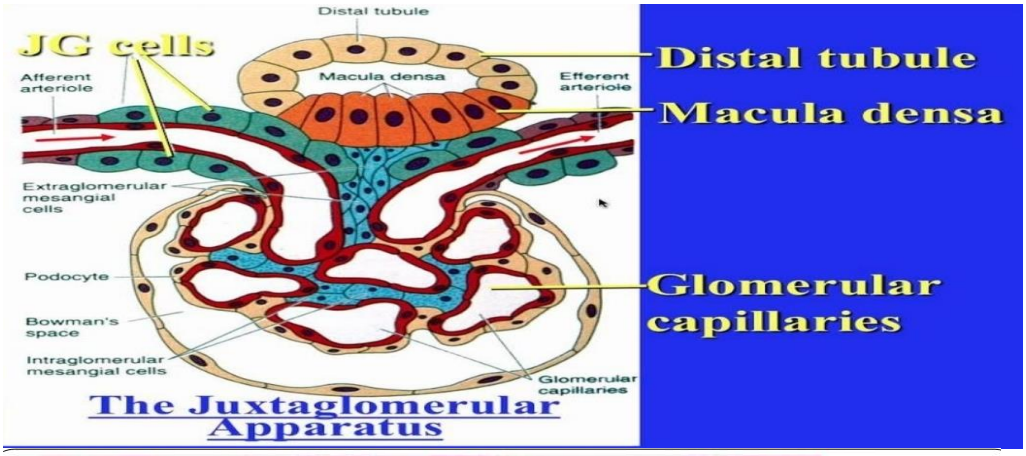

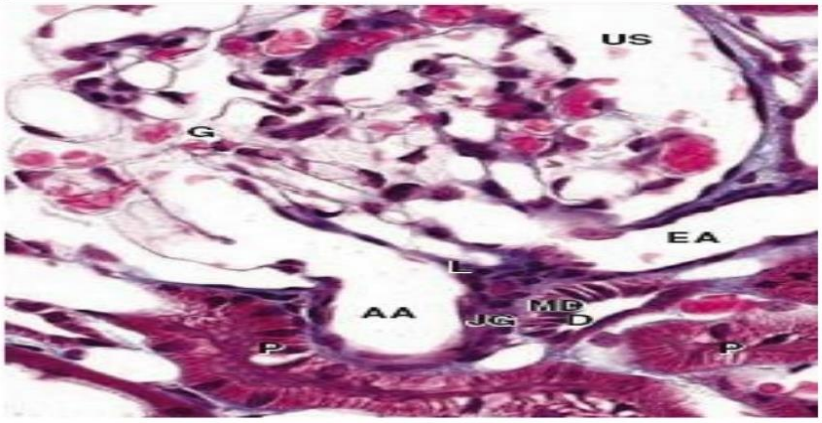

Distal tubule (D) Vascular pole of its glomerulus (G)
Macula densa (MD) Afferent arteriole's (AA)
juxtaglomerular granule cells (JG) Efferent arteriole (EA)
Lacis cells (L), which are extraglomerular mesangial

Mechanisms of urine formation:

1- Filtration involves the transfer of soluble components, such as water and waste, from the blood into the glomerulus.
2- Reabsorption involves the absorption of molecules, ions, and water that are necessary for the body to maintain homeostasis from the glomerular filtrate back into the blood.
3- Secretion involves the transfer of hydrogen ions, creatinine, drugs, and urea from the blood into the collecting duct, and is primarily made of water.

•Blood and glucose are **not normally** found in urine.

Urothelium or transitional epithelium:

It is composed of 3 layers:

1- A layer of basal small cells resting on a very thin basement membrane.
2- An intermediate region containing from one to several layers of cuboidal or low columnar cells.
3- A superficial layer of large elliptical umbrella cells, highly differentiated to protect the underlying cells against cytotoxic effects of hypertonic urine. (Well developed in the bladder).

- Umbrella cells have extensive intercellular junctional complexes surrounding unique apical membranes.
- This membrane containing integral membrane proteins called **uroplakins** that accumulate into arrays of stiffened plaques
- The membranous plaques, together with the tight junctions serve as an **osmotic barrier protecting against hypertonic urine** and **preventing dilution** of the stored urine.

The Ureter:

It is composed of 3 layers:

1- Mucosa that consists of transitional epithelium and loose CT (lamina propria).
2- Muscularis which consists of two layers:
   a) Outer circular
   b) Inner longitudinal

3- Adventitia: it is composed of connective tissues and has nerve fibers and blood vessels.

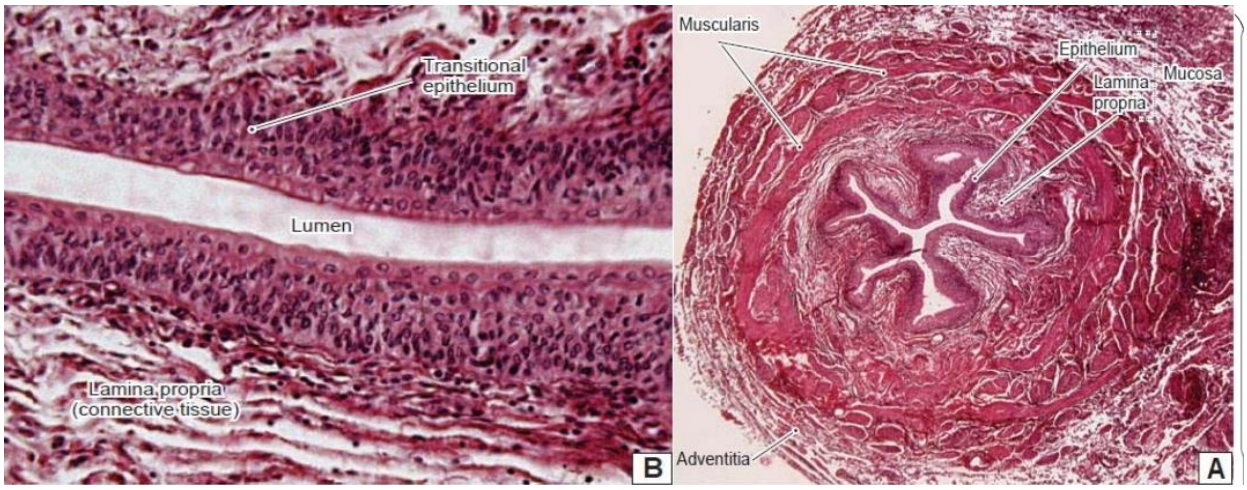

<u>The Urinary bladder:</u>

- It is composed of 3 layers: (mucosa, muscularis, and adventitia/serosa).
- The mucosa is composed of: transitional epithelium and lamina propria.
- The muscularis consists of three smooth muscle layers collectively called the **<u>detrusor muscle</u>**: These are the inner **<u>longitudinal, middle circular, and outer longitudinal</u>** smooth muscle layers.
  These three smooth muscle layers are arranged in two different orientations to help the urinary bladder contract to empty urine efficiently.
- Adventitia (connective tissue) the outer layer: its superior (free) surface is covered by **<u>serosa</u>** (due to the presence of peritoneum), which is a layer of connective tissue with a lining of **<u>mesothelium.</u>**

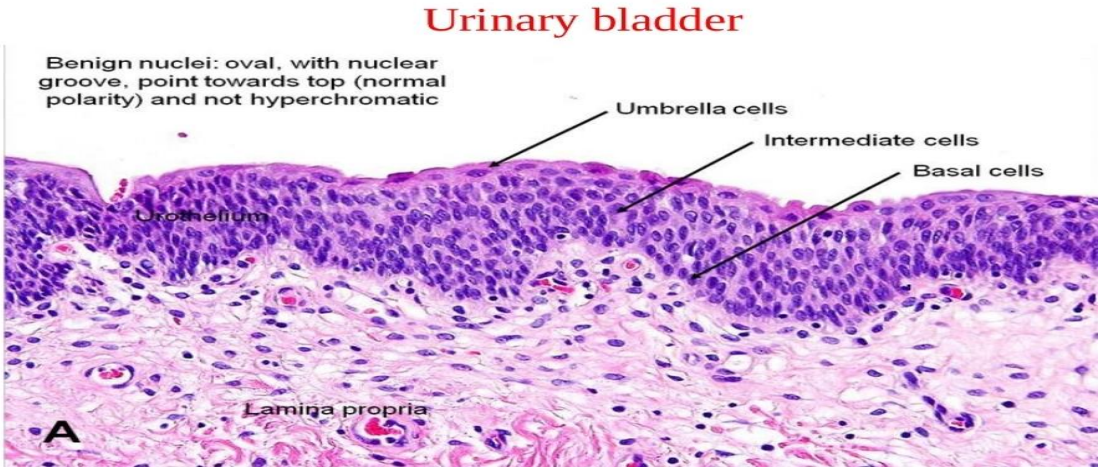

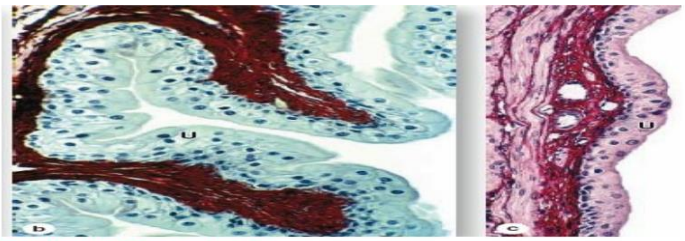

(b) When the bladder is empty, the mucosa is highly folded the urothelium (**U**) has umbrella cells.
(c) When the bladder is full, the mucosa is pulled smooth, the urothelium (**U**) is thinner, and the umbrella cells are flatter.

- In the previous photo:
  When the bladder is empty the transitional epithelial cells are inflated and enlarged, while when the bladder is full they shrink and become thinner.

Male urethra:

It is composed of 4 parts:

1- **The preprostatic part**.

2- **The prostatic urethra**:

- Extends through the prostate gland and is lined by **urothelium** (transitional epithelium).

3- **The membranous urethra:**

- Passes through an external sphincter of striated muscle of the deep perineal pouch.
- Lined by **stratified columnar and pseudostratified columnar epithelium**.

4- **The spongy urethra:**

- Enclosed within the erectile tissue of the penis.
- Lined by **stratified columnar and pseudostratified columnar epithelium**, **except** the terminal part (the tip) which is lined by stratified squamous epithelium.

Female urethra:

- The urethra is short, measuring 3 to 5 cm in length from the bladder to the vestibule of the vagina.
- The lining epithelium is initially transitional epithelium, a continuation of the bladder epithelium, but changes to **stratified squamous** epithelium before its termination.
- The lamina propria is a highly vascularized layer of connective tissue.
- The urethra penetrates the urogenital diaphragm whose striated muscle forms the external urethral sphincter.

Sorry for any mistakes
Best of luck Inshallah