The Special Senses

Auditory

The Nature of Sound

- All waves have basic characteristics:
  - Amplitude
  - Frequency
  - Wavelength
- These properties have particular names with reference to sound
  - Amplitude = loudness
  - Frequency = pitch

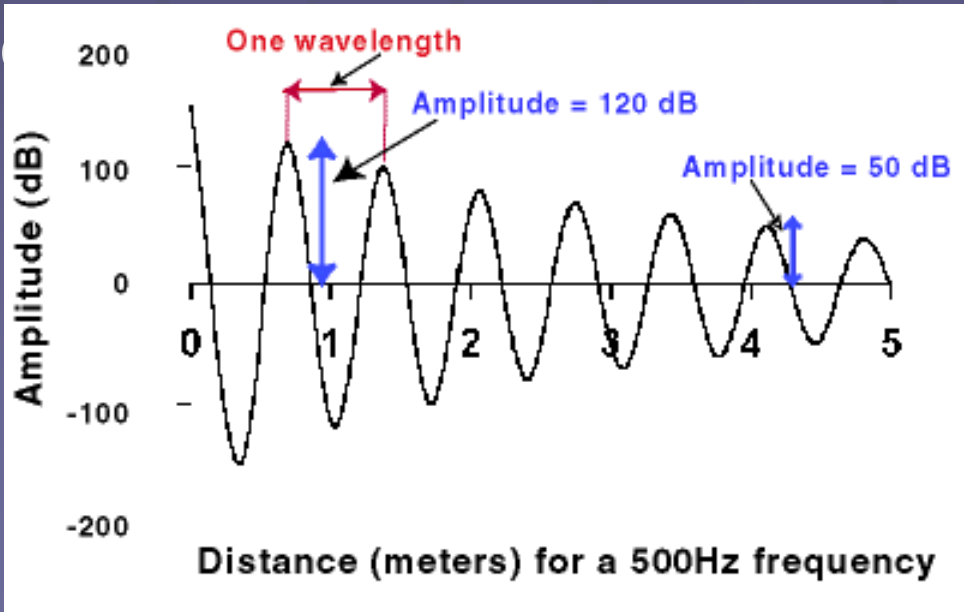

The Nature of Sound

- Sound
  - Range: 20 Hz to 20,000 Hz
  - Pitch: High pitch = high frequency; low frequency = low pitch
  - Intensity: High intensity louder than low intensity

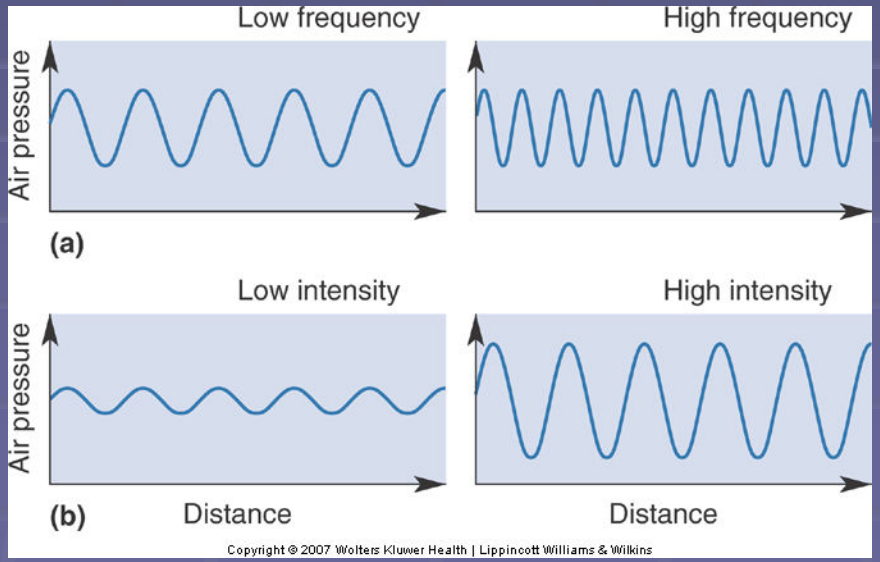

Anatomy of the ear

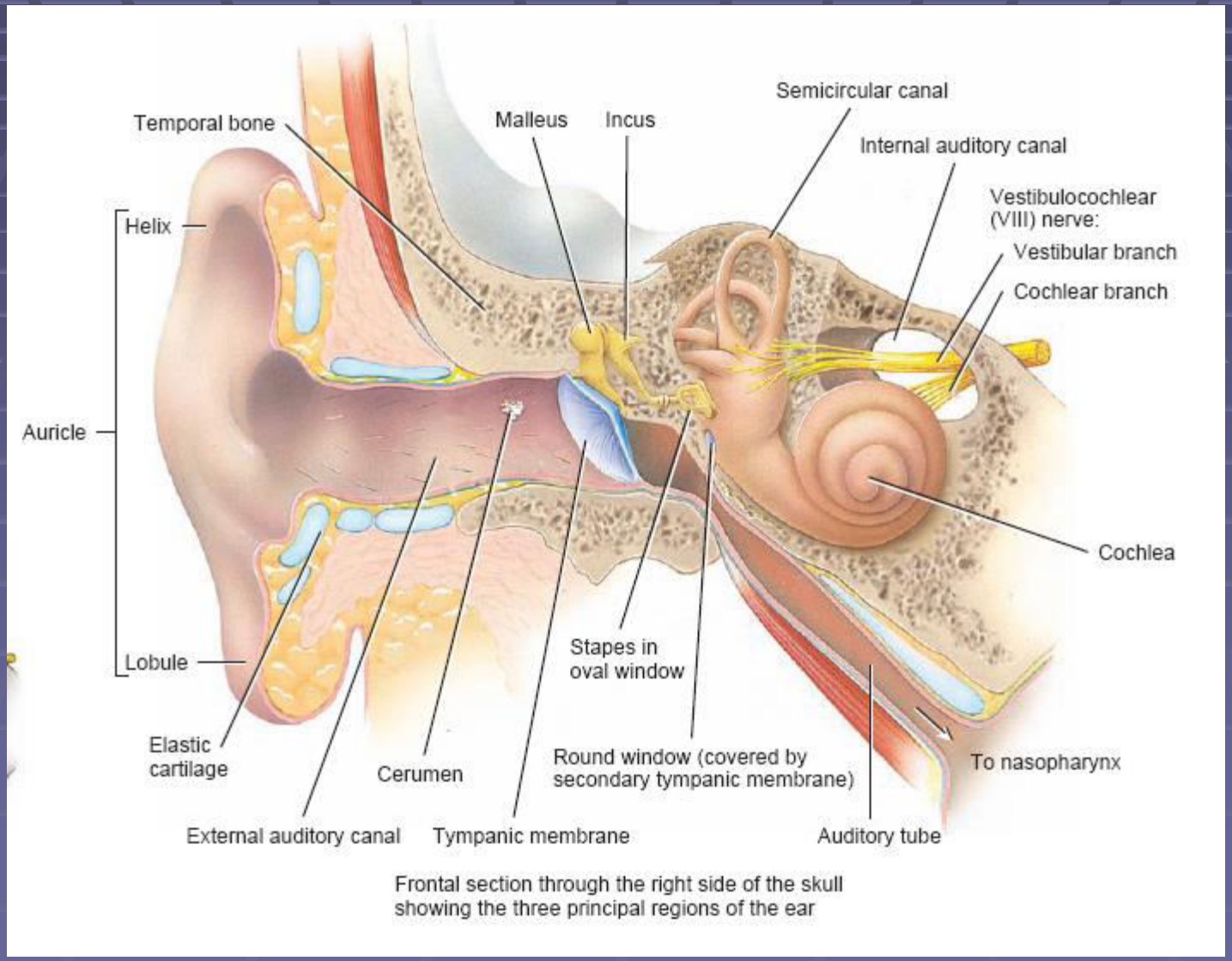

Frontal section through the right side of the skull showing the three principal regions of the ear

Anatomy of the ear

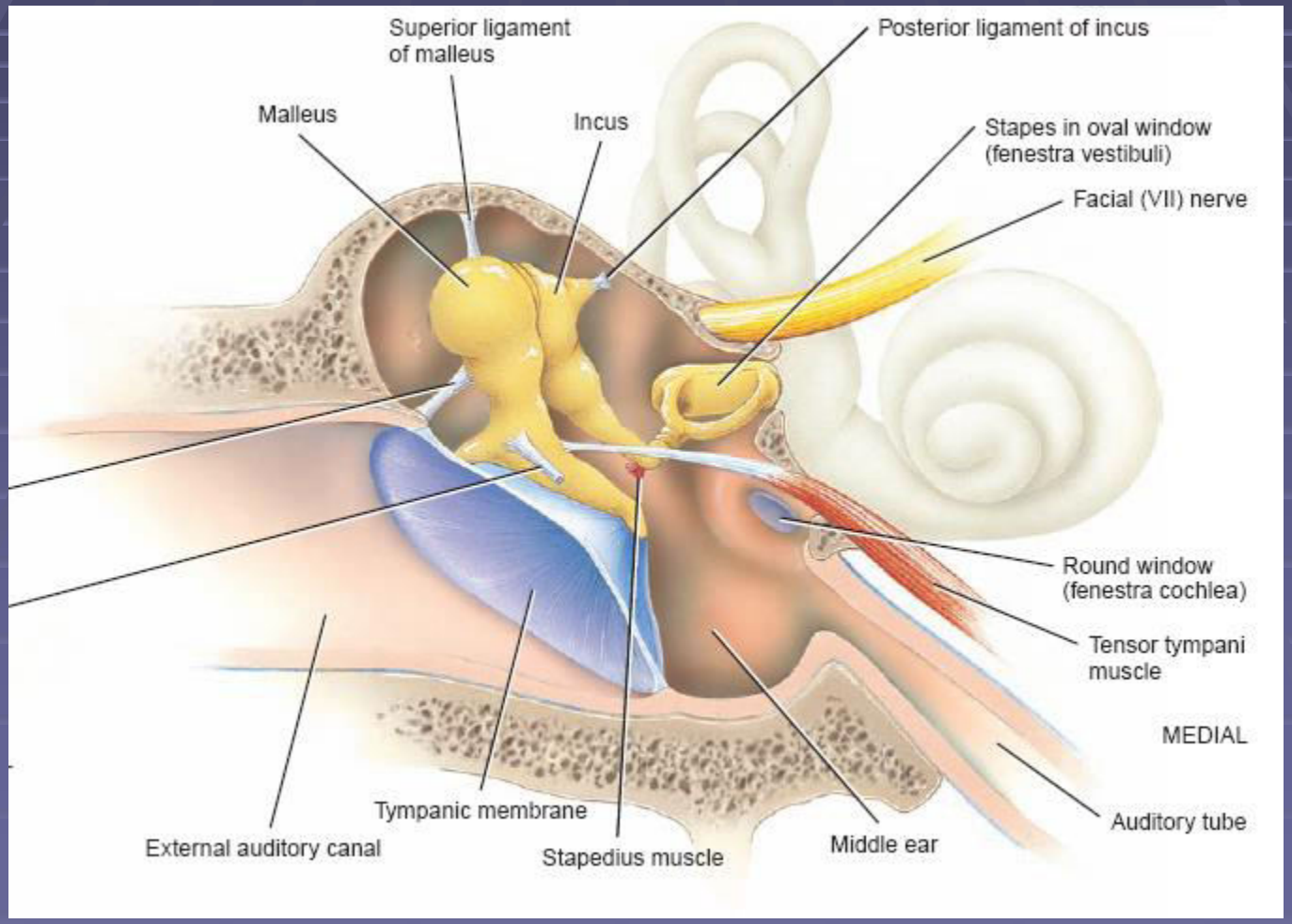

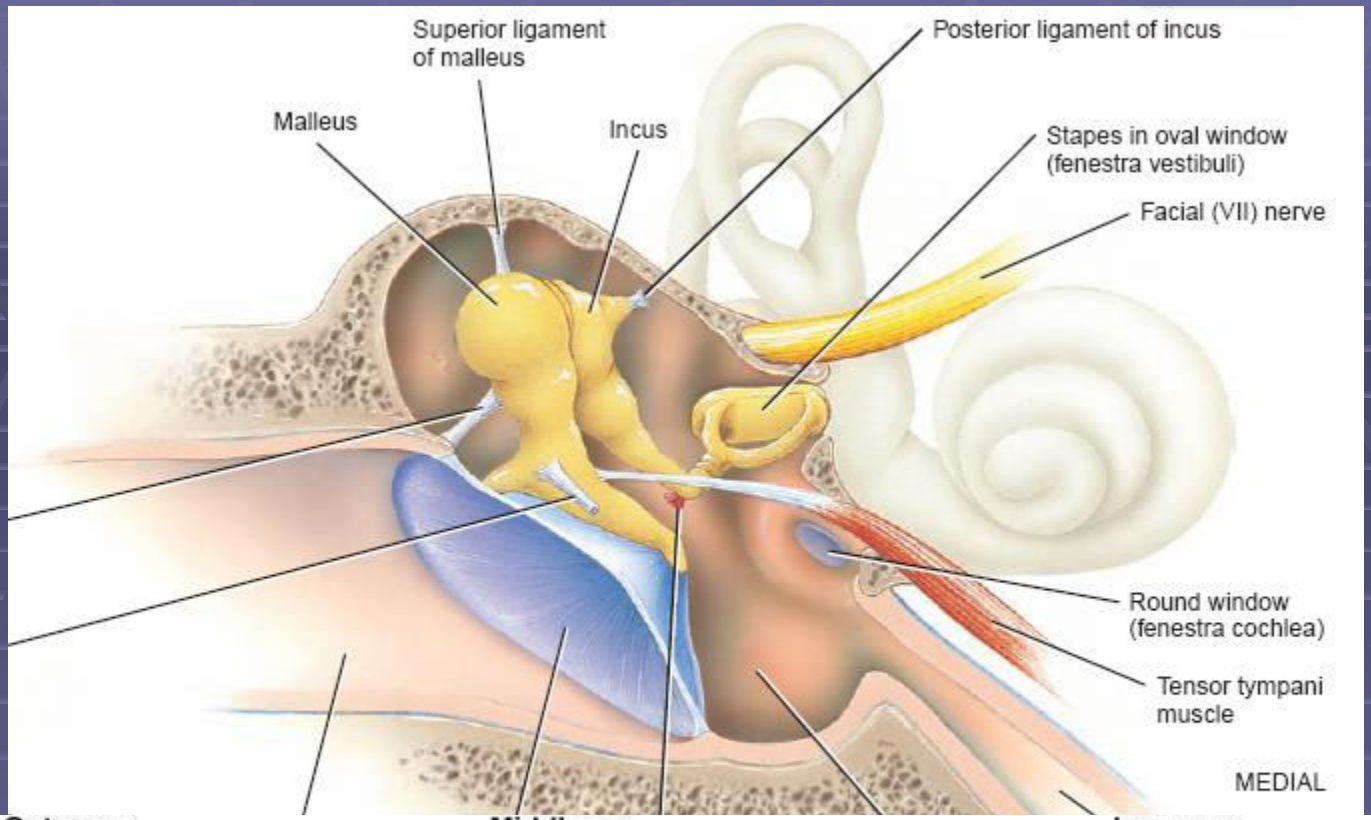
Superior ligament of malleus
Posterior ligament of incus
Malleus
Incus
Stapes in oval window (fenestra vestibuli)
Facial (VII) nerve
Round window (fenestra cochlea)
Tensor tympani muscle
MEDIAL

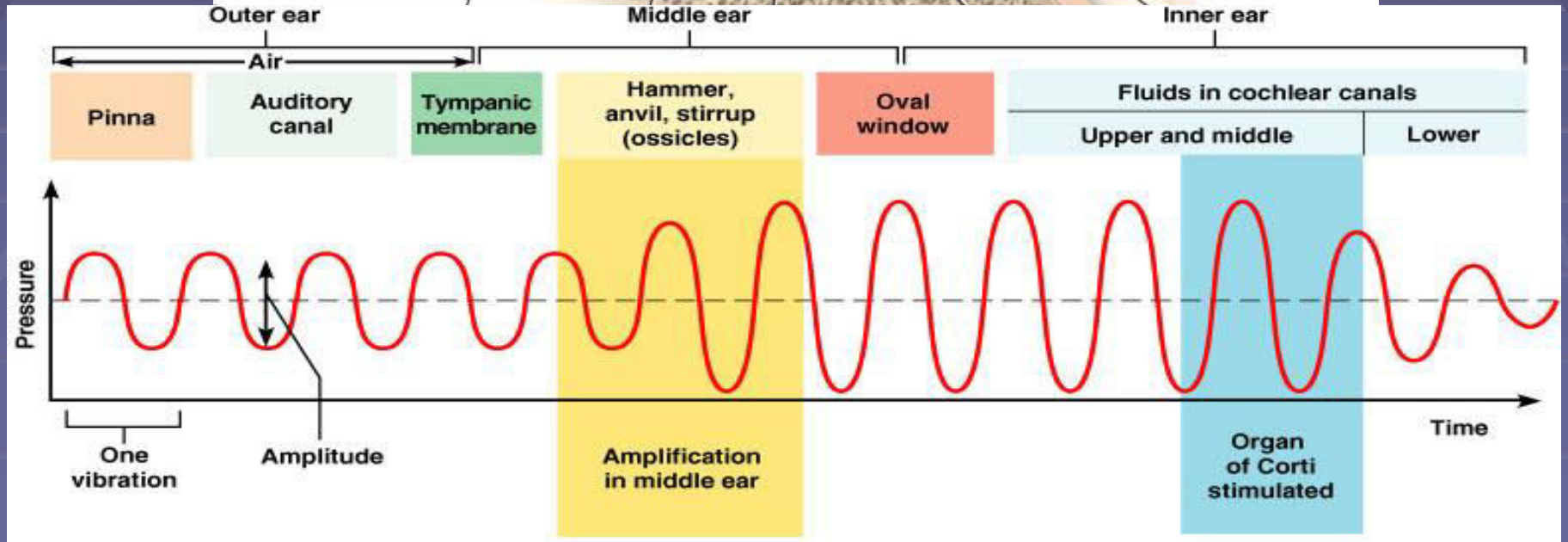
Outer ear
Middle ear
Inner ear
Air
Pinna
Auditory canal
Tympanic membrane
Hammer, anvil, stirrup (ossicles)
Oval window
Fluids in cochlear canals
Upper and middle
Lower
Pressure
Time
One vibration
Amplitude
Amplification in middle ear
Organ of Corti stimulated

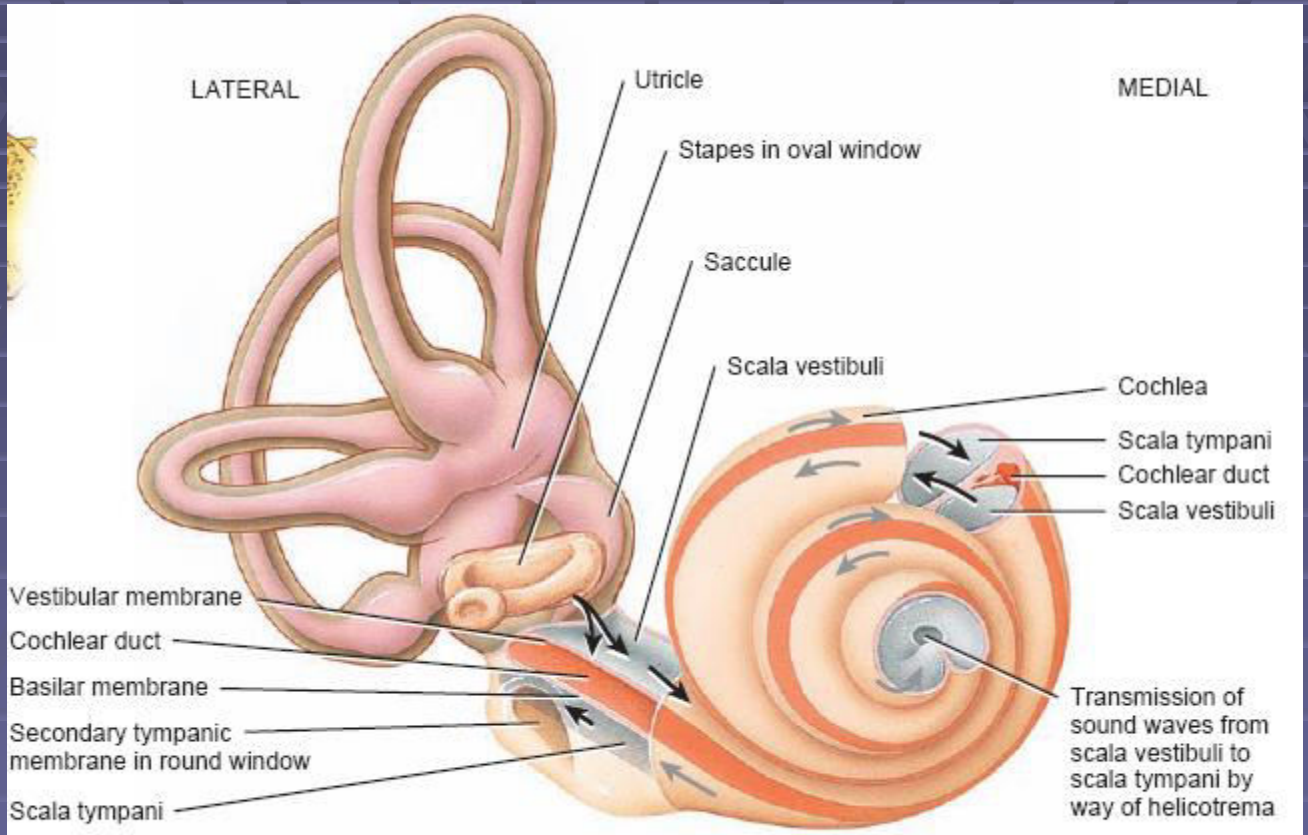

(a) Sections through the cochlea

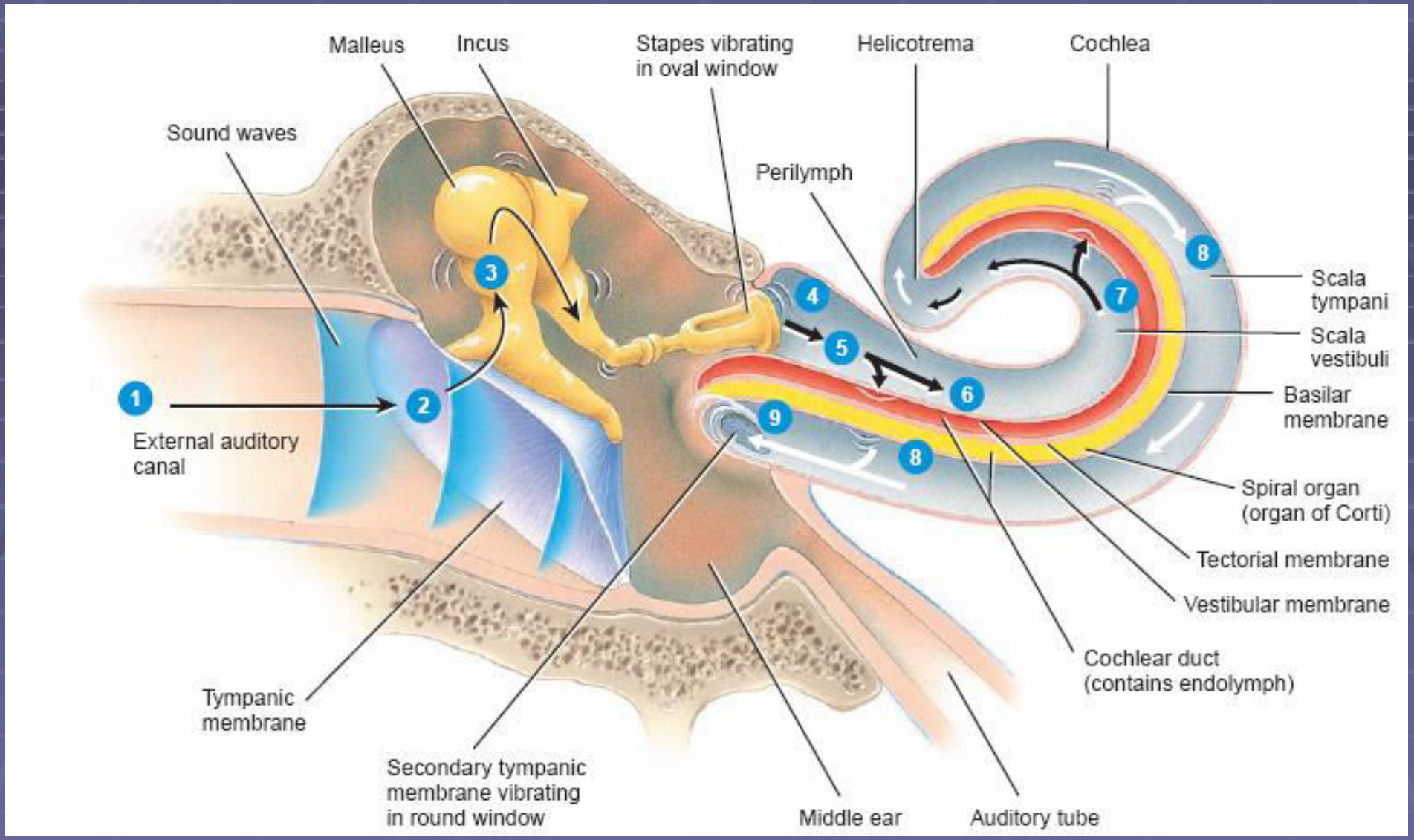
Malleus
Incus
Stapes vibrating in oval window
Helicotrema
Cochlea
Sound waves
Perilymph
Scala tympani
Scala vestibuli
Basilar membrane
Spiral organ (organ of Corti)
Tectorial membrane
Vestibular membrane
Cochlear duct (contains endolymph)
External auditory canal
Tympanic membrane
Secondary tympanic membrane vibrating in round window
Middle ear
Auditory tube
1
2
3
4
5
6
7
8
9

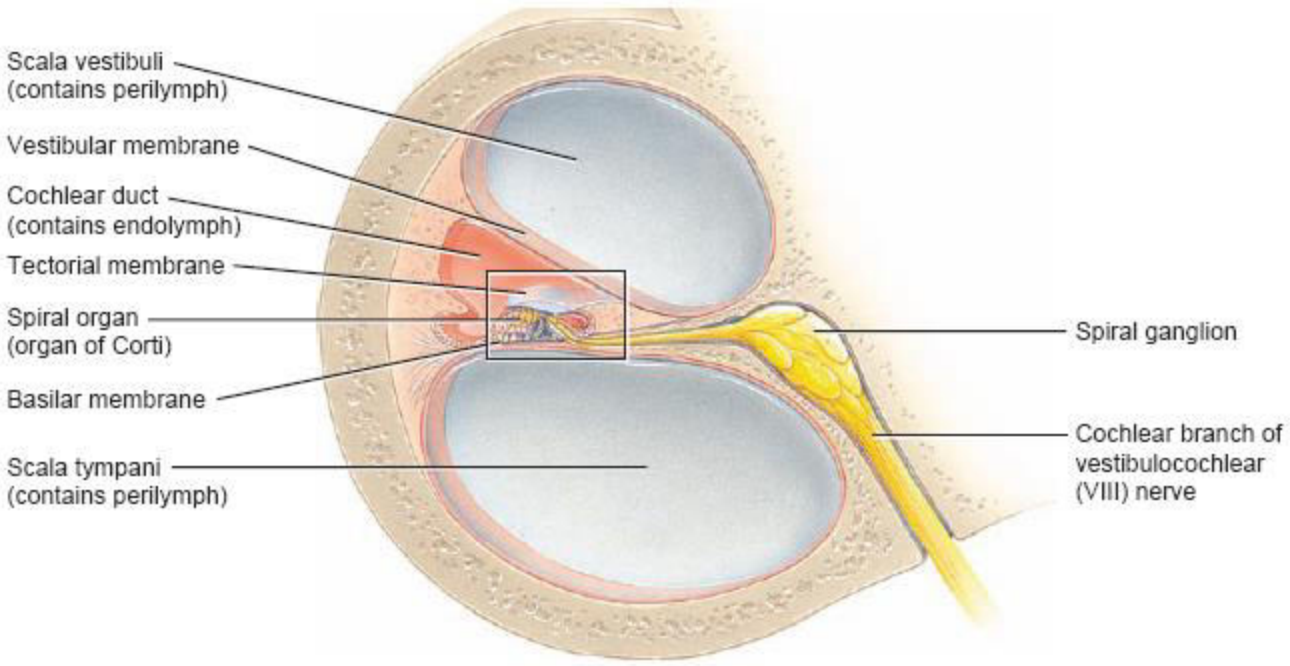

(c) Section through one turn of the cochlea

(c) Section through one turn of the cochlea

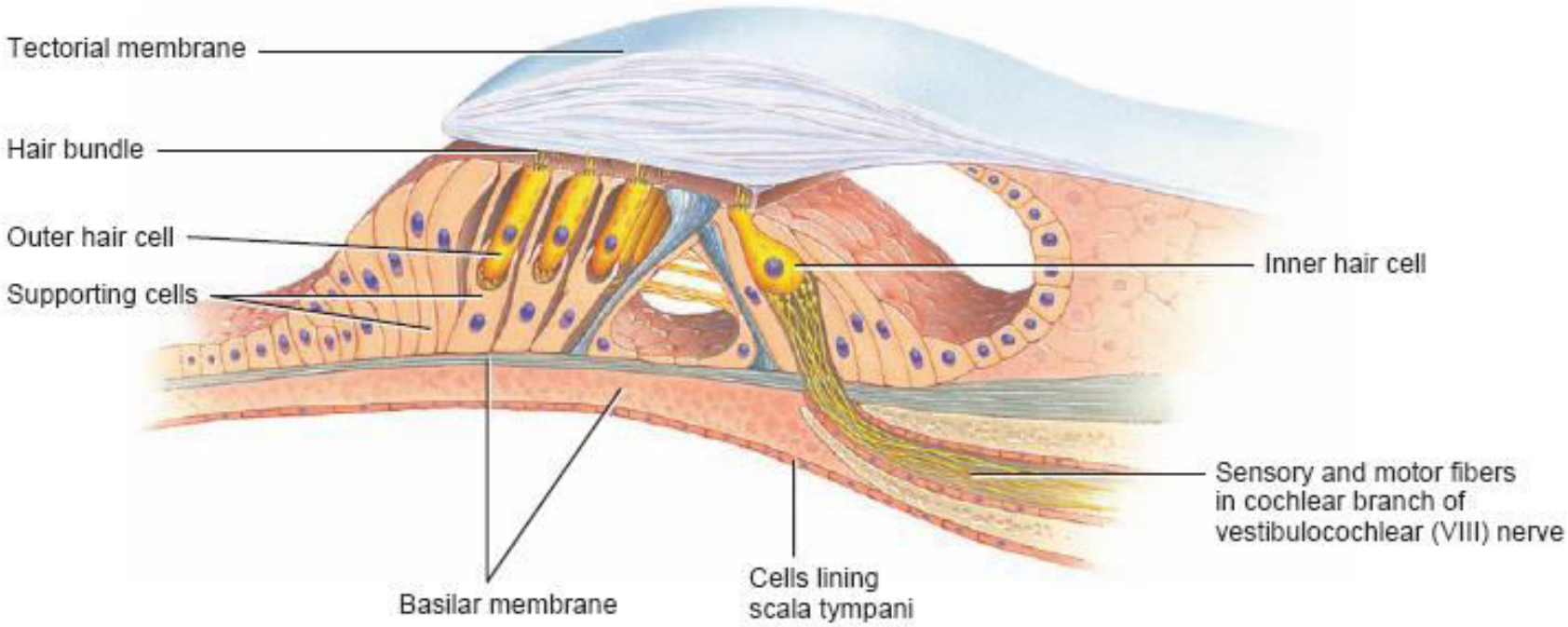

(d) Enlargement of spiral organ (organ of Corti)

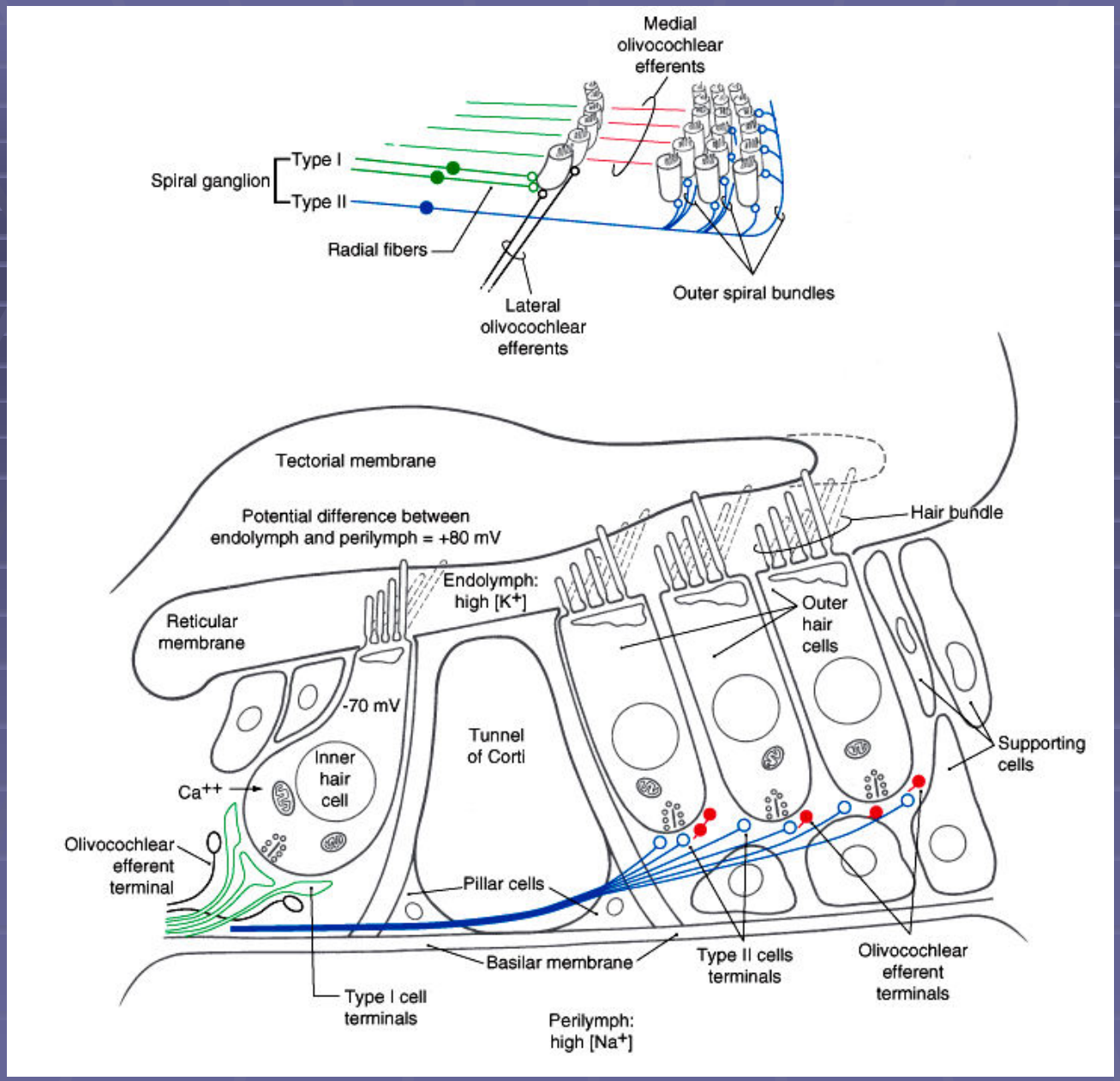
Medial olivocochlear efferents
Spiral ganglion
Type I
Type II
Radial fibers
Lateral olivocochlear efferents
Outer spiral bundles
Tectorial membrane
Potential difference between endolymph and perilymph = +80 mV
Hair bundle
Endolymph: high [K+]
Reticular membrane
Outer hair cells
-70 mV
Tunnel of Corti
Supporting cells
Inner hair cell
Ca++
Olivocochlear efferent terminal
Pillar cells
Basilar membrane
Type II cells terminals
Olivocochlear efferent terminals
Type I cell terminals
Perilymph: high [Na+]

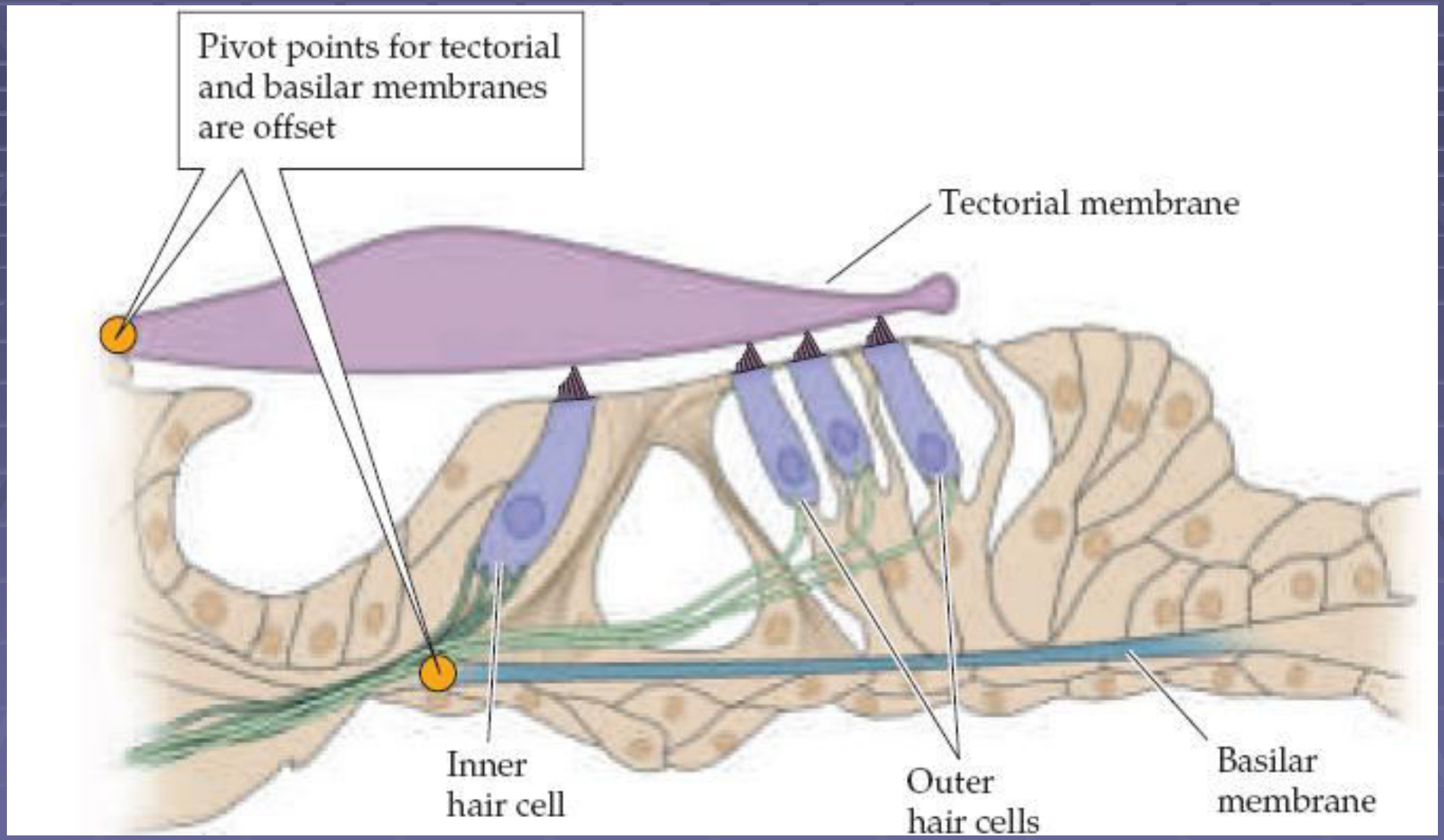
Pivot points for tectorial and basilar membranes are offset
Tectorial membrane
Inner hair cell
Outer hair cells
Basilar membrane

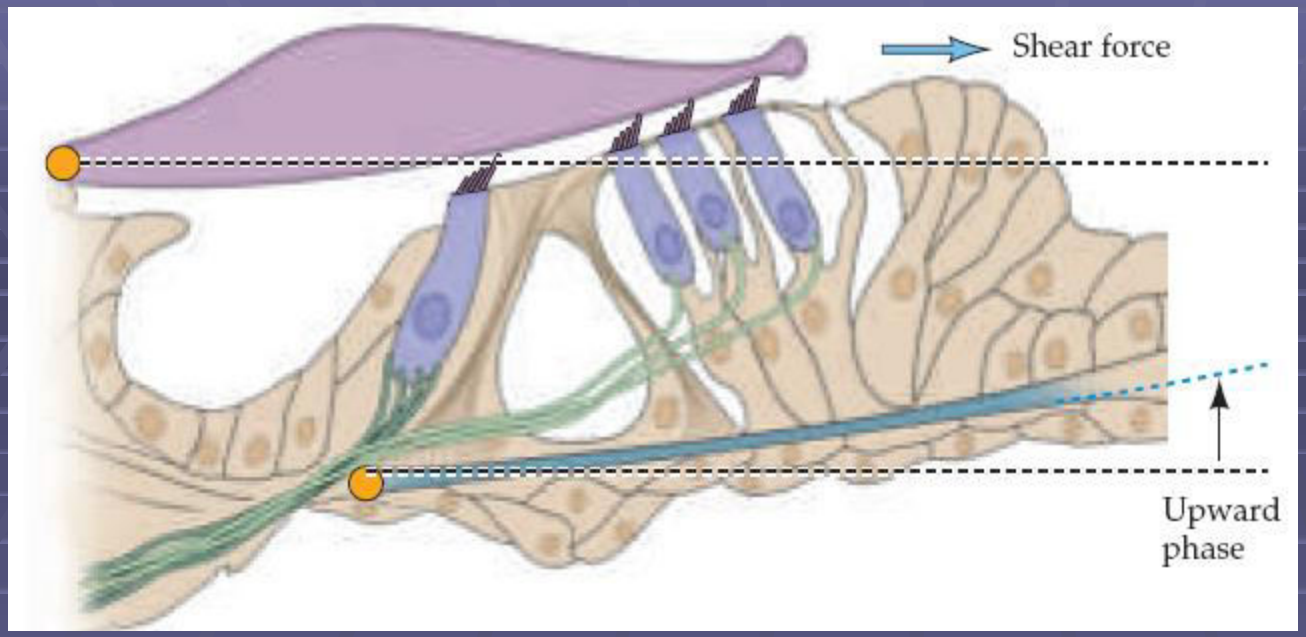
Shear force
Upward
phase

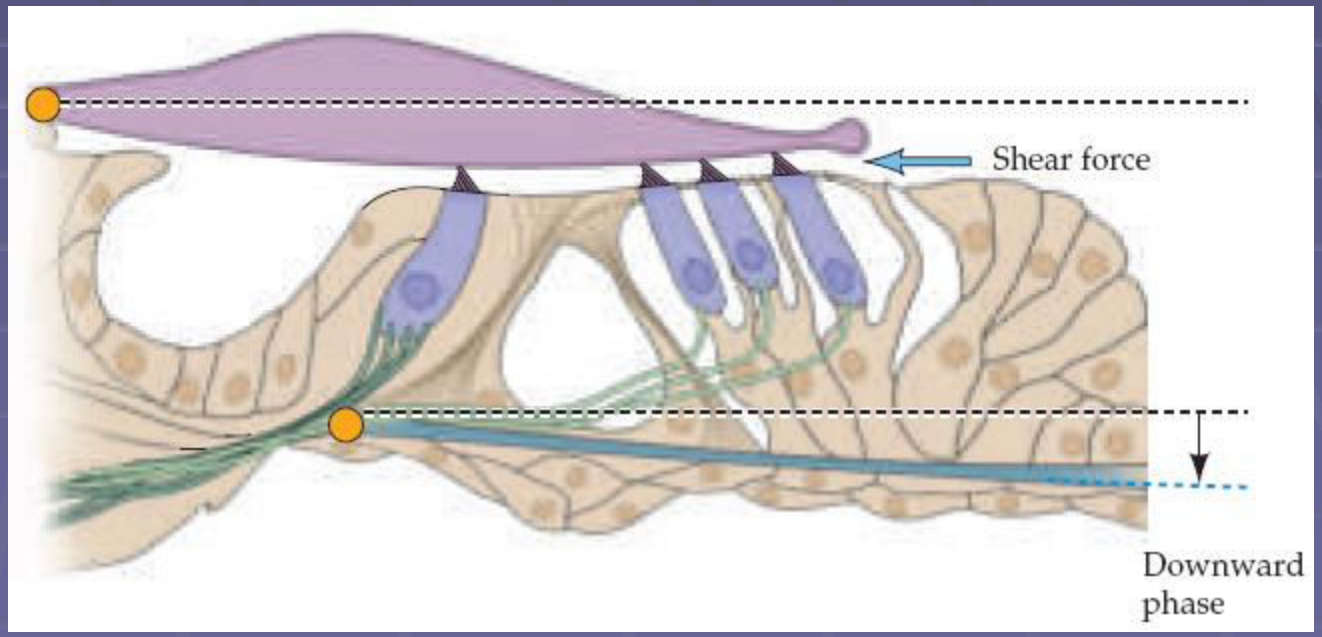
Shear force
Downward
phase

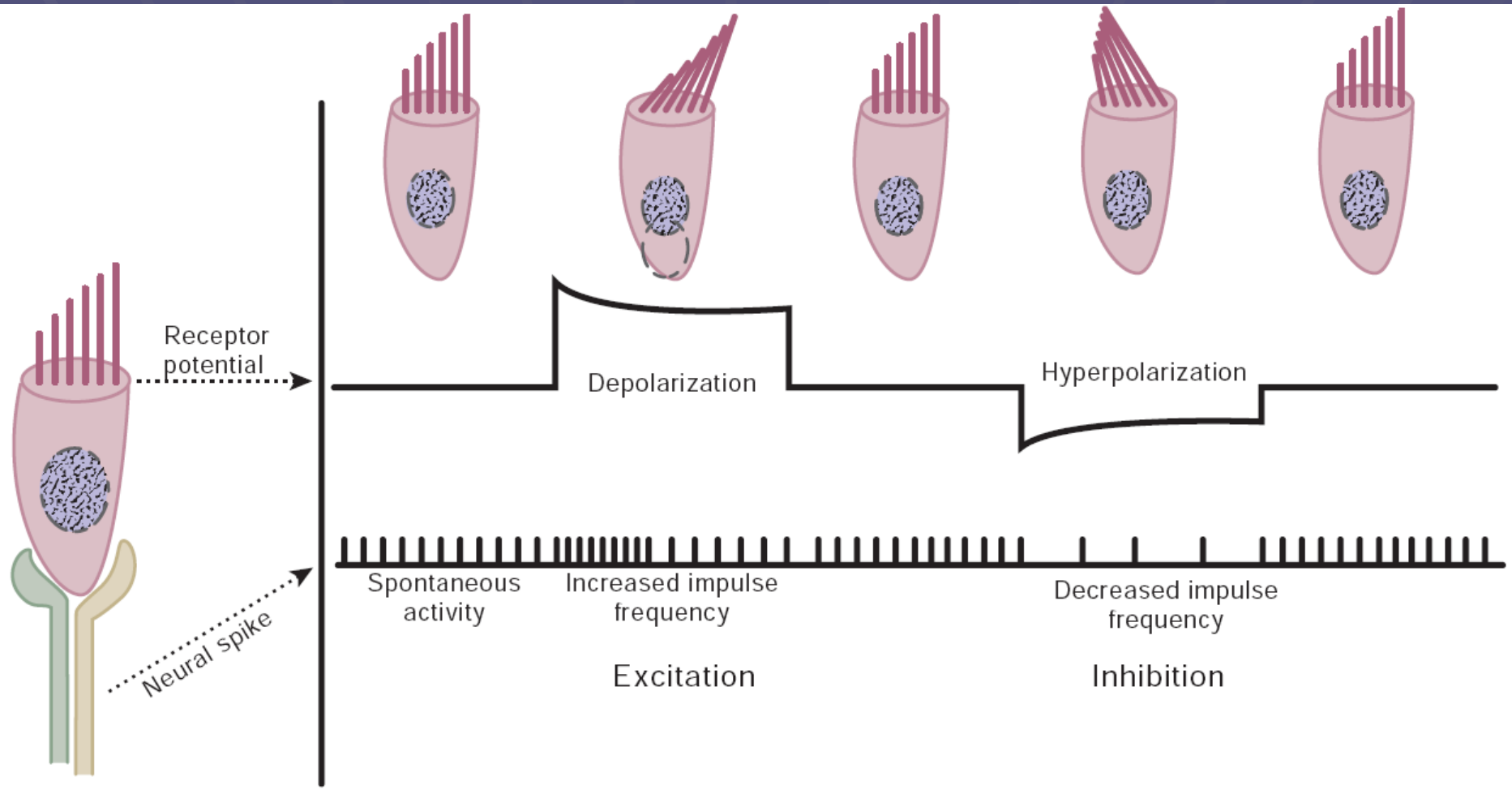
Receptor potential
Depolarization
Hyperpolarization
Neural spike
Spontaneous activity
Increased impulse frequency
Decreased impulse frequency
Excitation
Inhibition

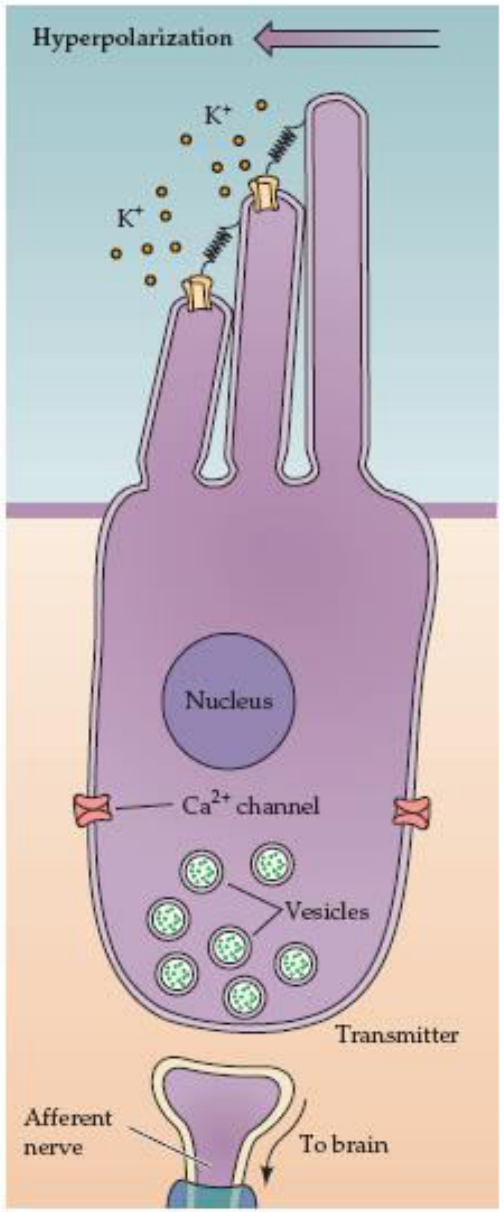
Hyperpolarization
K+
K+
Nucleus
Ca2+ channel
Vesicles
Transmitter
Afferent nerve
To brain

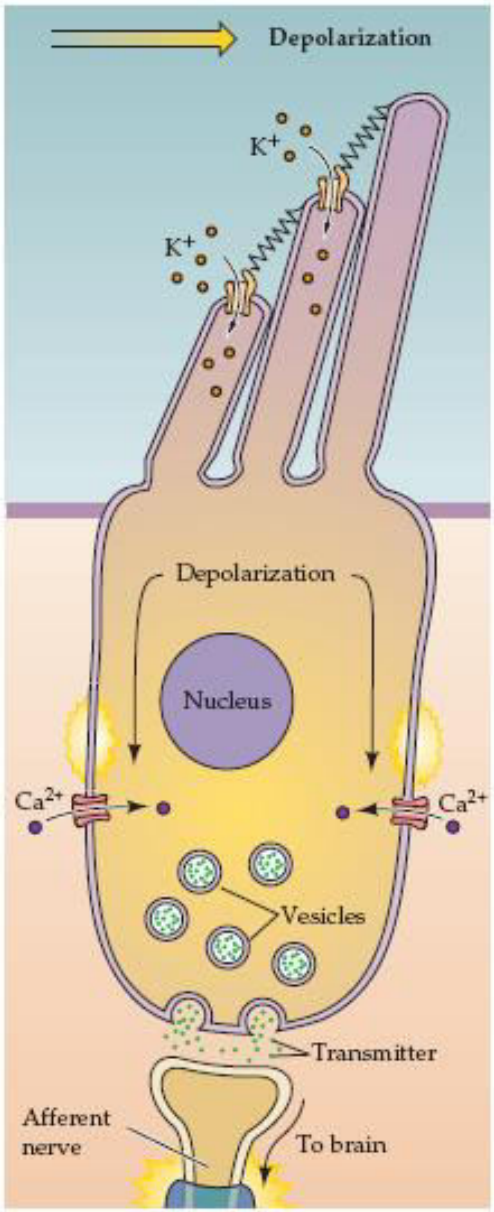
Depolarization
K+
K+
Depolarization
Nucleus
Ca2+
Ca2+
Vesicles
Transmitter
Afferent nerve
To brain

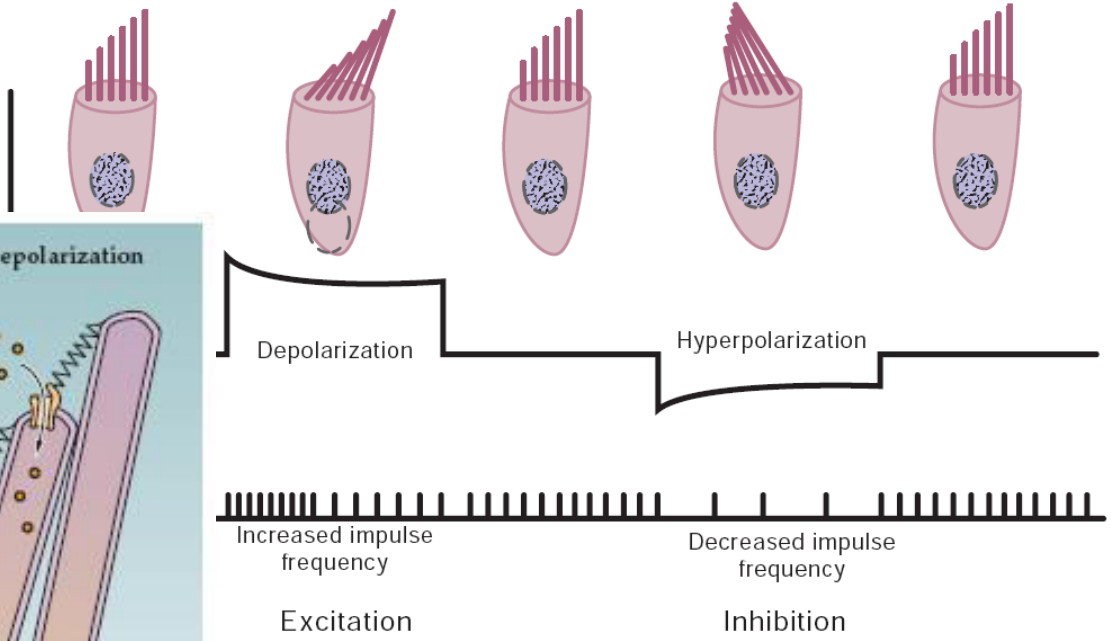
Depolarization
Hyperpolarization
Increased impulse frequency
Decreased impulse frequency
Excitation
Inhibition

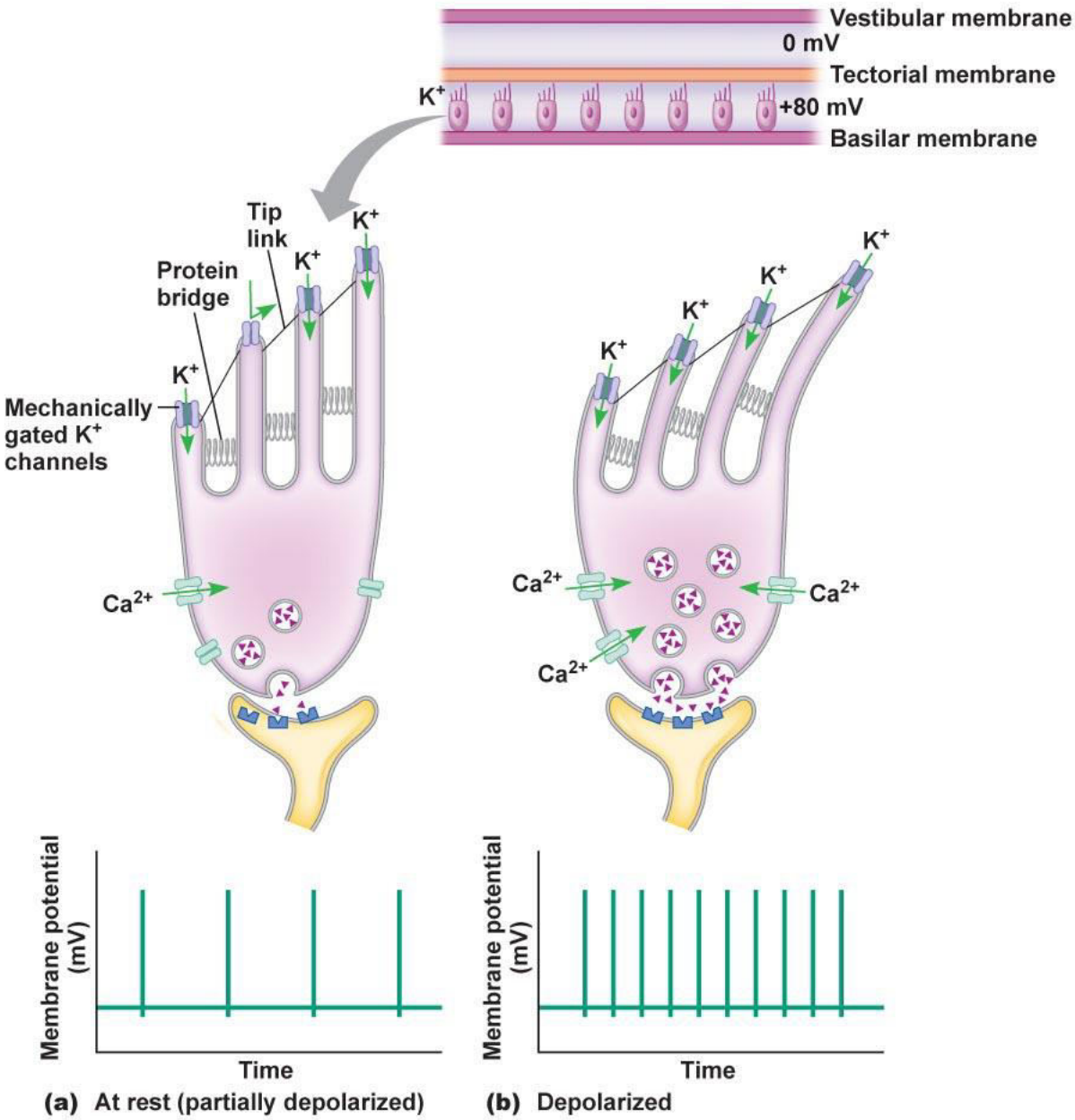

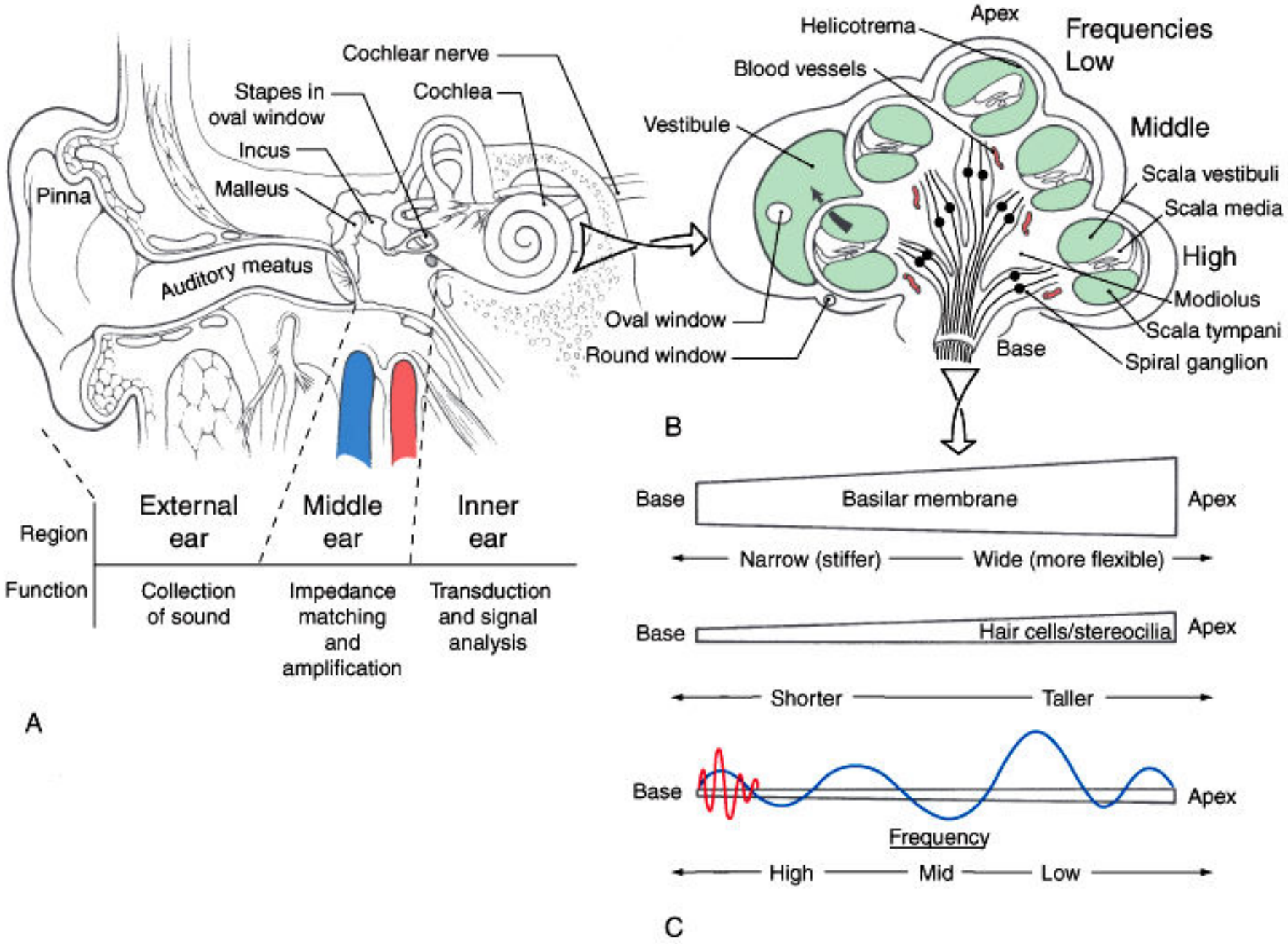
Cochlear nerve
Stapes in oval window
Cochlea
Incus
Malleus
Pinna
Auditory meatus
Region
External ear
Middle ear
Inner ear
Function
Collection of sound
Impedance matching and amplification
Transduction and signal analysis
A
Helicotrema
Apex
Frequencies
Low
Blood vessels
Vestibule
Middle
Scala vestibuli
Scala media
High
Modiolus
Scala tympani
Spiral ganglion
Oval window
Round window
Base
B
Base
Basilar membrane
Apex
Narrow (stiffer)
Wide (more flexible)
Base
Hair cells/stereocilia
Apex
Shorter
Taller
Base
Apex
Frequency
High
Mid
Low
C

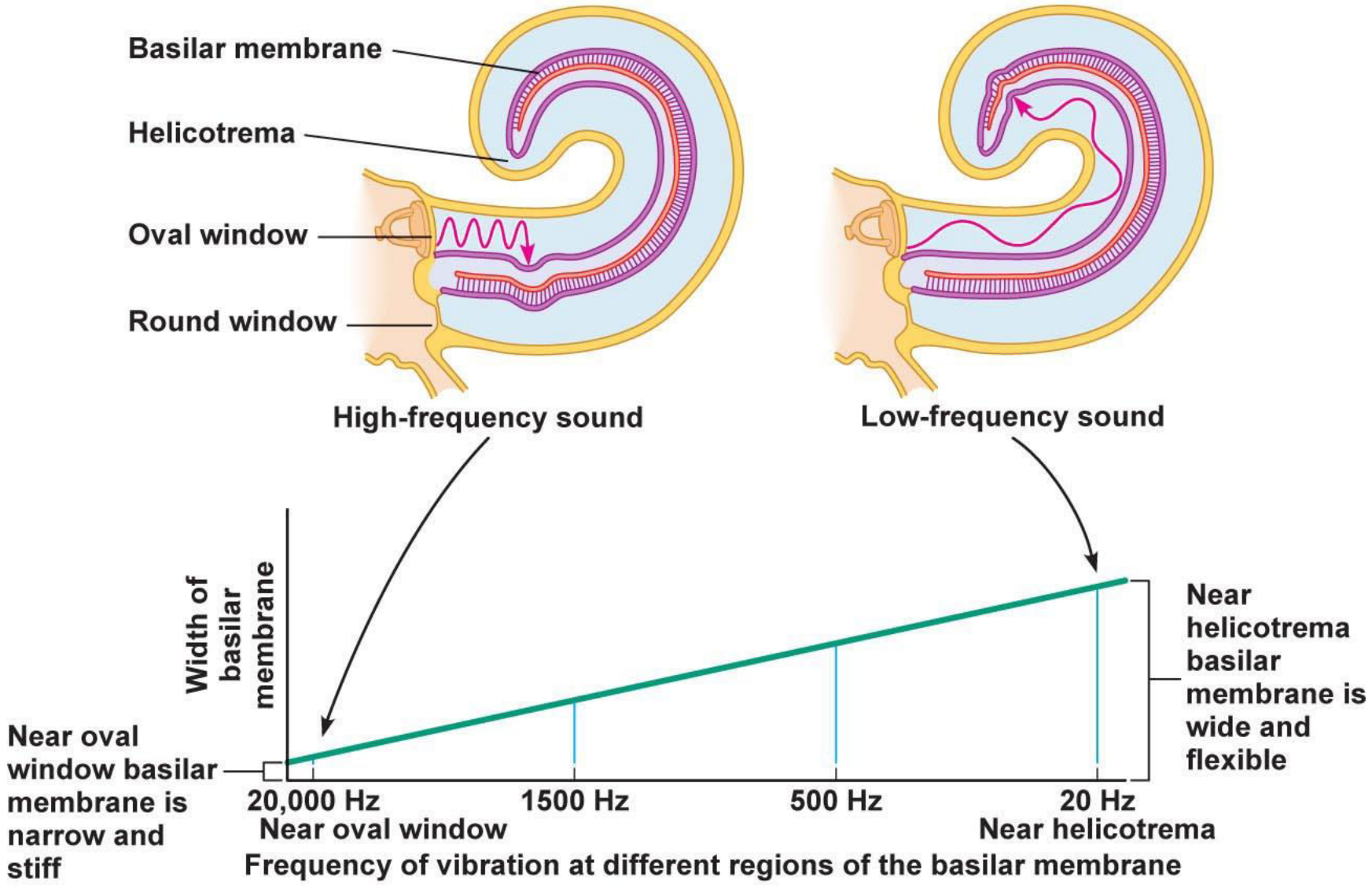

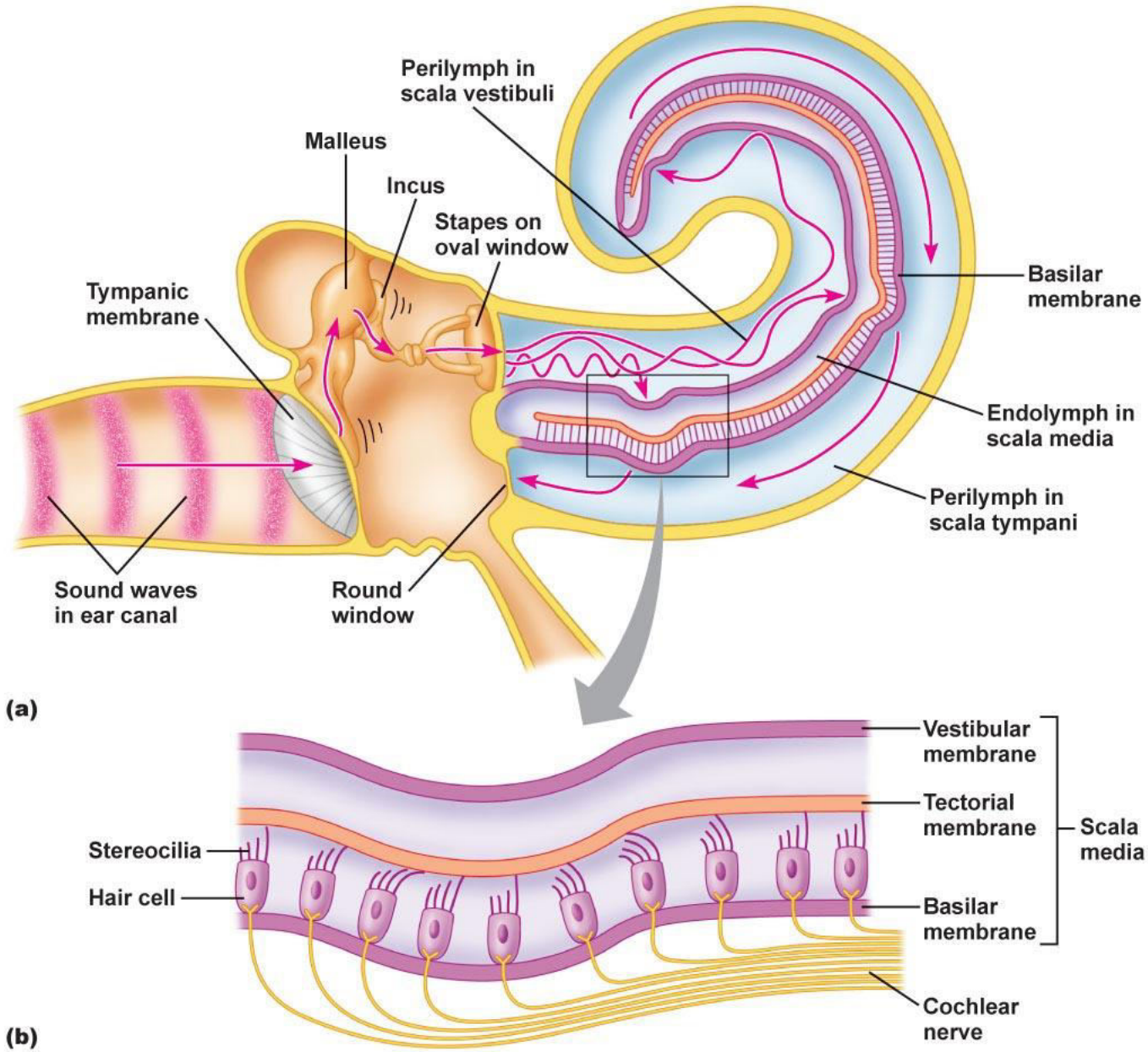

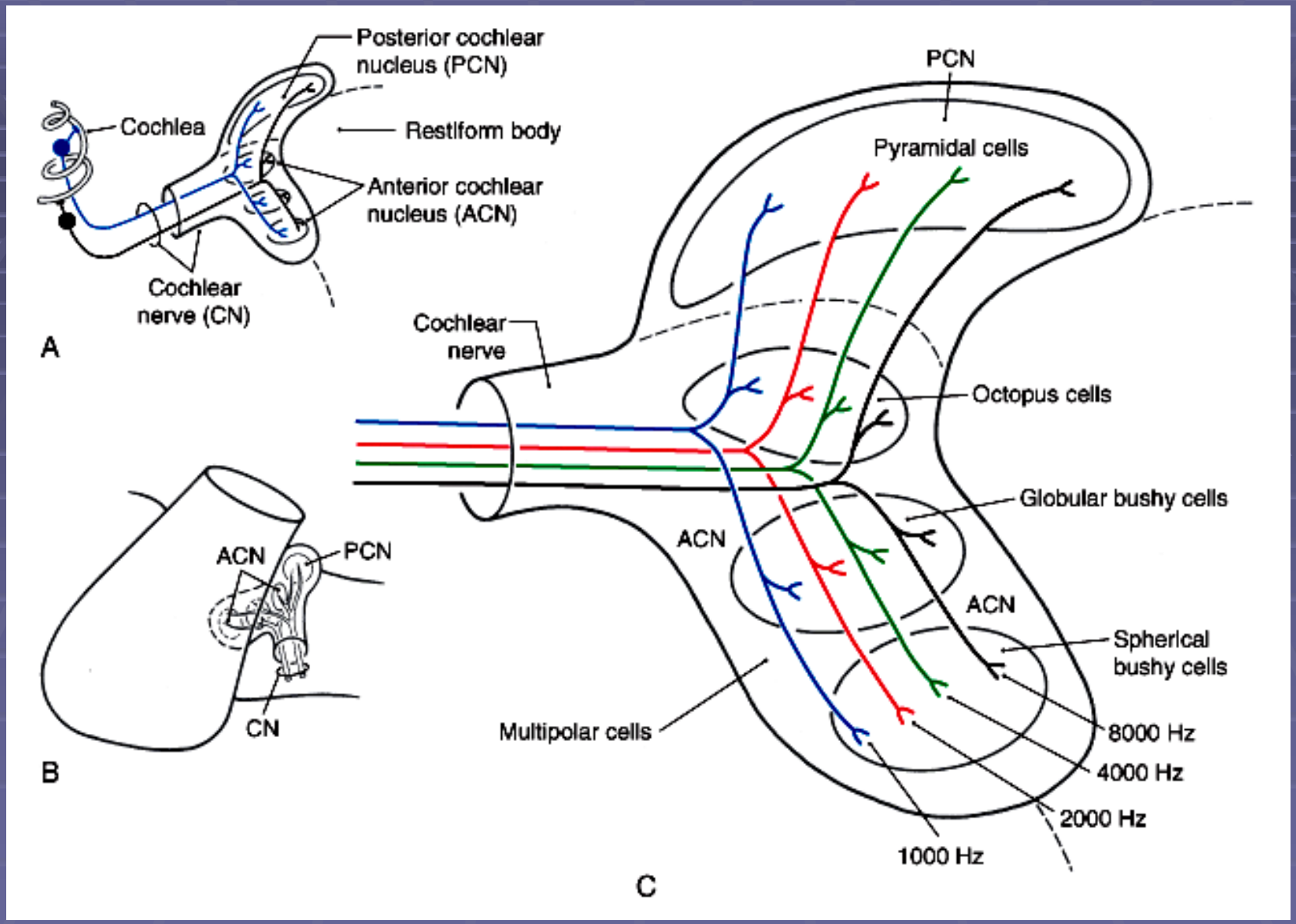
Posterior cochlear nucleus (PCN)
Cochlea
Restiform body
Anterior cochlear nucleus (ACN)
Cochlear nerve (CN)
A
ACN
PCN
CN
B
PCN
Pyramidal cells
Cochlear nerve
Octopus cells
Globular bushy cells
ACN
ACN
Spherical bushy cells
Multipolar cells
8000 Hz
4000 Hz
2000 Hz
1000 Hz
C

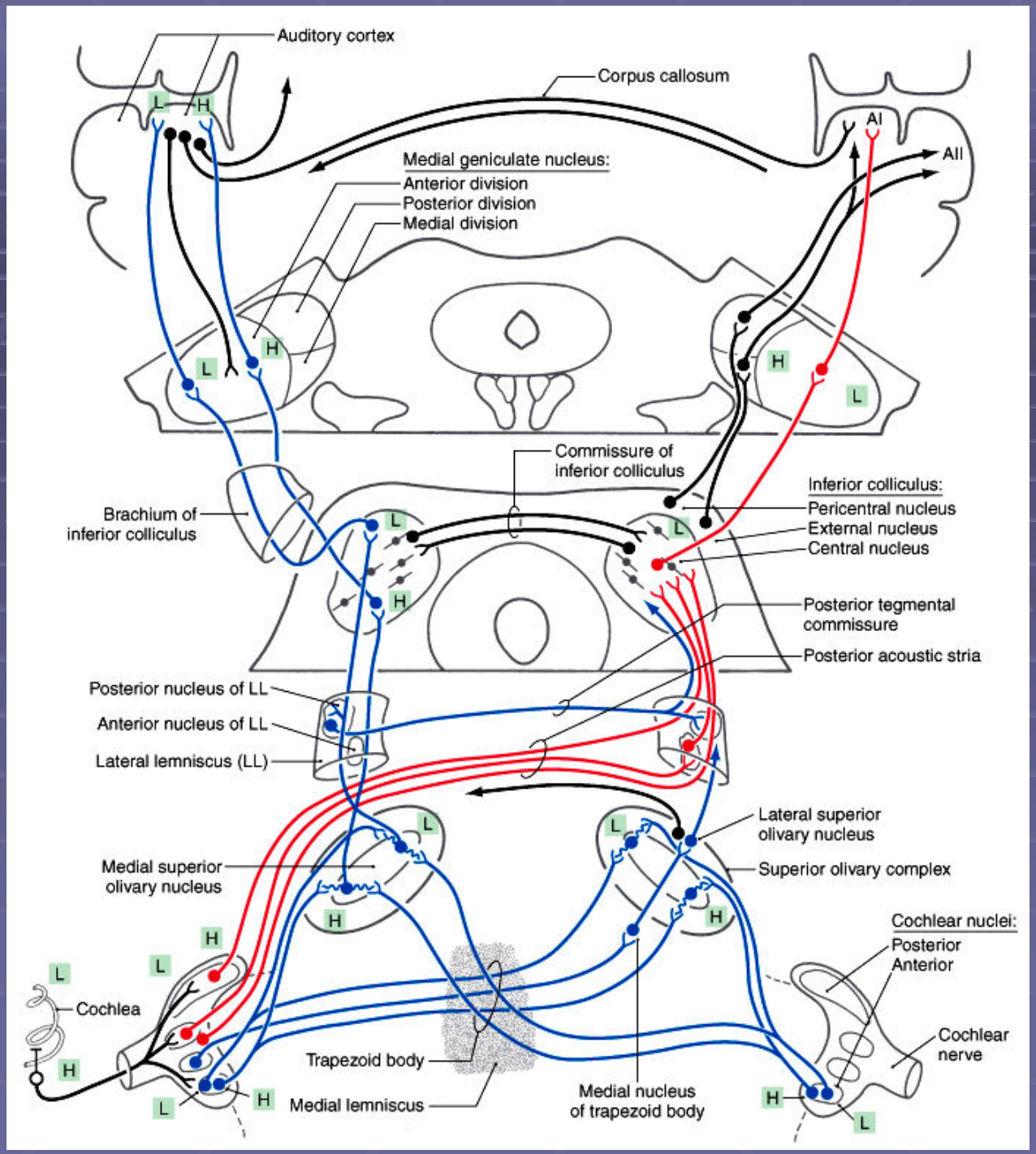
Auditory cortex
Corpus callosum
AI
AII
Medial geniculate nucleus:
Anterior division
Posterior division
Medial division
L
H
Commissure of inferior colliculus
Inferior colliculus:
Pericentral nucleus
External nucleus
Central nucleus
Brachium of inferior colliculus
Posterior tegmental commissure
Posterior acoustic stria
Posterior nucleus of LL
Anterior nucleus of LL
Lateral lemniscus (LL)
Lateral superior olivary nucleus
Superior olivary complex
Medial superior olivary nucleus
Cochlear nuclei:
Posterior
Anterior
Cochlea
Cochlear nerve
Trapezoid body
Medial lemniscus
Medial nucleus of trapezoid body

Auditory cortex
Corpus callosum
AI
AII
Medial geniculate nucleus:
Anterior division
Posterior division
Medial division
Commissure of inferior colliculus
Inferior colliculus:
Pericentral nucleus
External nucleus
Central nucleus
Brachium of inferior colliculus
Posterior tegmental commissure
Posterior acoustic stria
Posterior nucleus of LL
Anterior nucleus of LL
Lateral lemniscus (LL)
Lateral superior olivary nucleus
Superior olivary complex
Medial superior olivary nucleus
Cochlear nuclei
Posterior
Anterior
Cochlea
Cochlear nerve
Trapezoid body
Medial lemniscus
Medial nucleus of trapezoid body
L
H

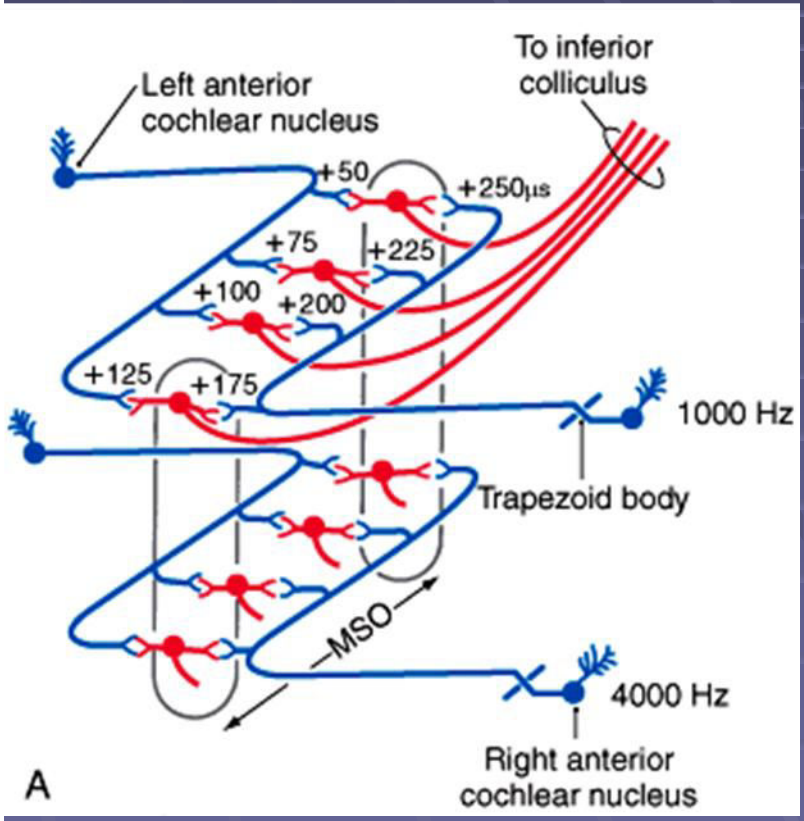

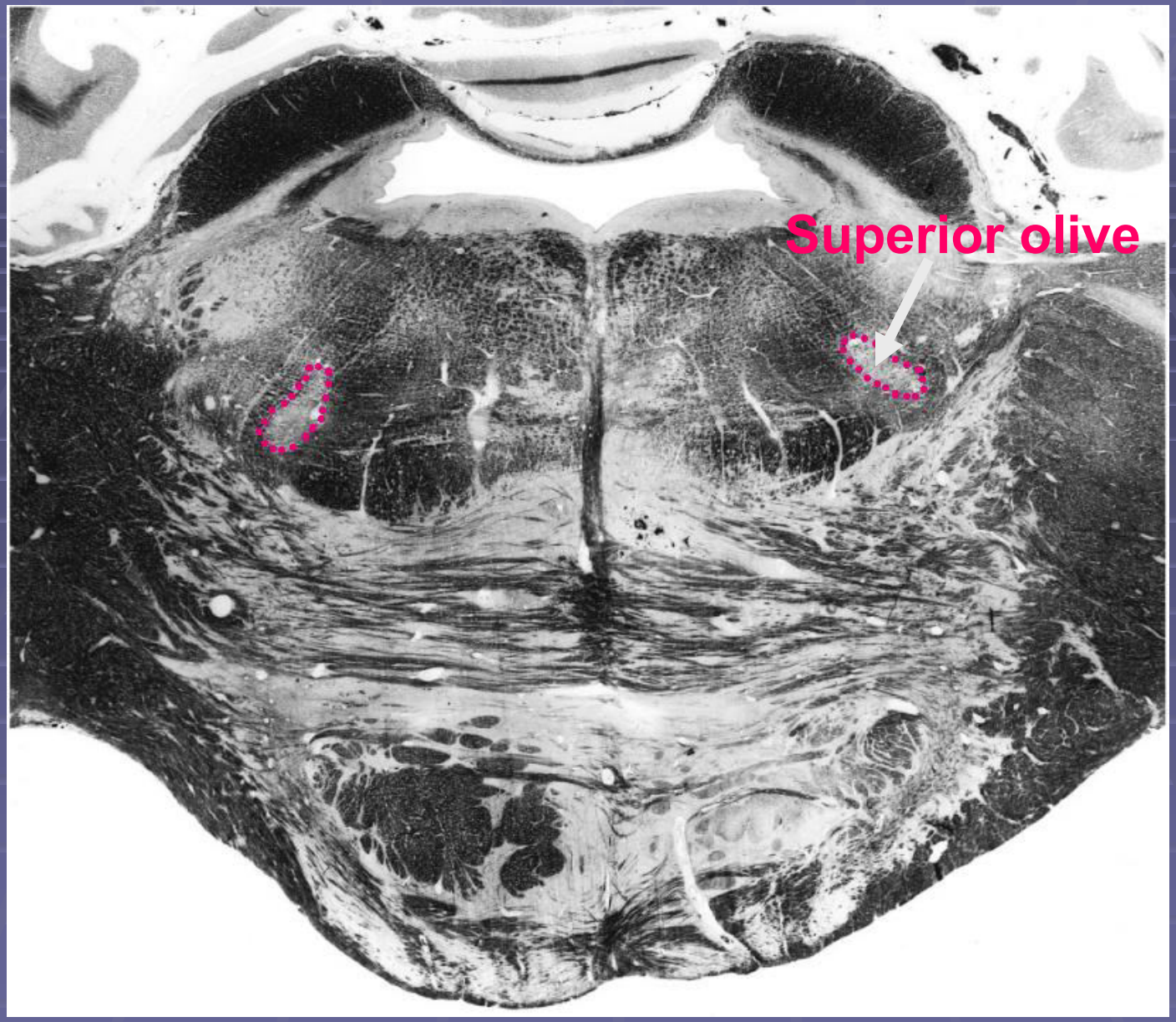
Superior olive

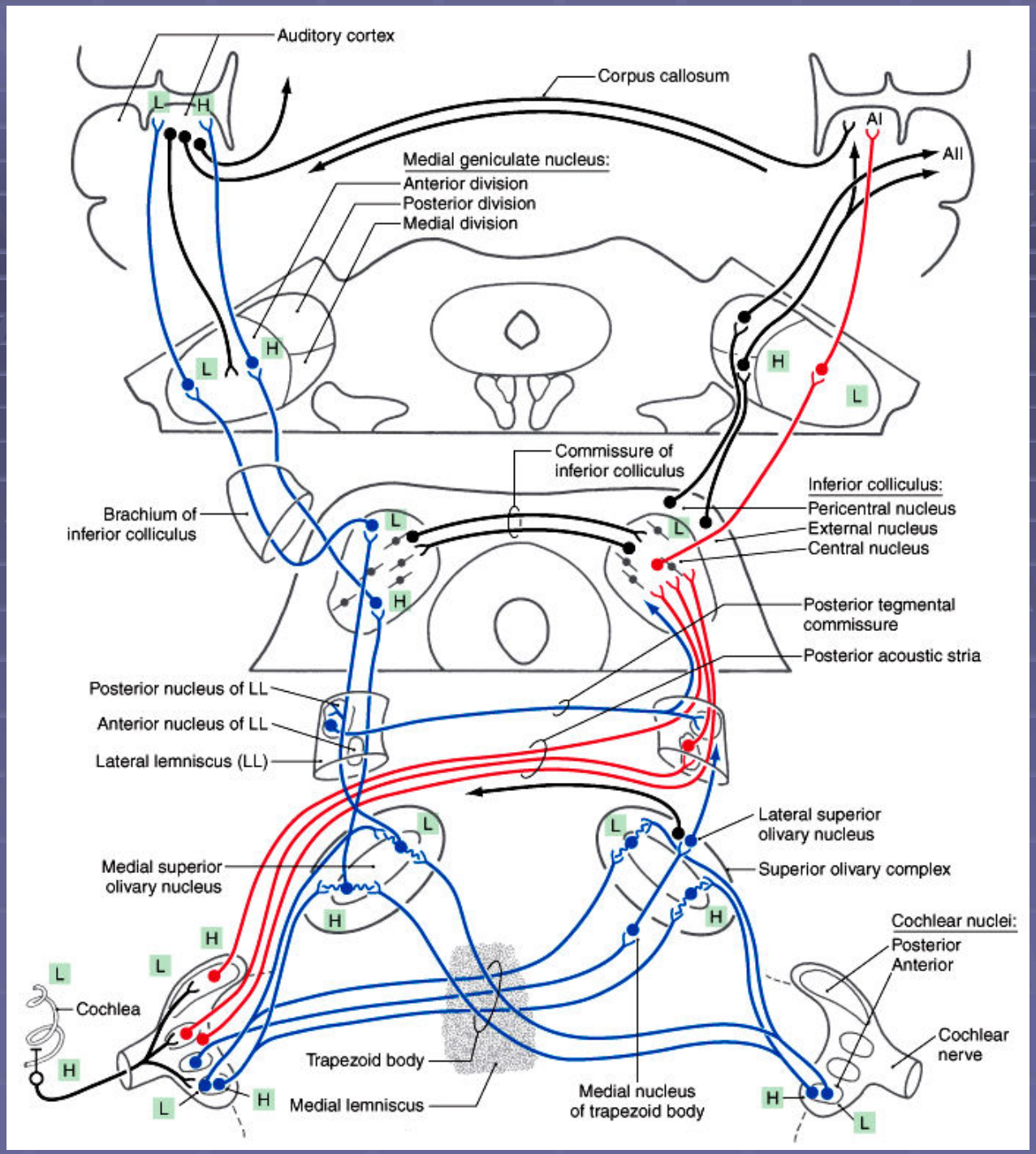
Auditory cortex
Corpus callosum
AI
AII
Medial geniculate nucleus:
Anterior division
Posterior division
Medial division
L
H
Commissure of inferior colliculus
Inferior colliculus:
Pericentral nucleus
External nucleus
Central nucleus
Brachium of inferior colliculus
Posterior tegmental commissure
Posterior acoustic stria
Posterior nucleus of LL
Anterior nucleus of LL
Lateral lemniscus (LL)
Lateral superior olivary nucleus
Superior olivary complex
Medial superior olivary nucleus
Cochlear nuclei:
Posterior
Anterior
Cochlea
Cochlear nerve
Trapezoid body
Medial lemniscus
Medial nucleus of trapezoid body

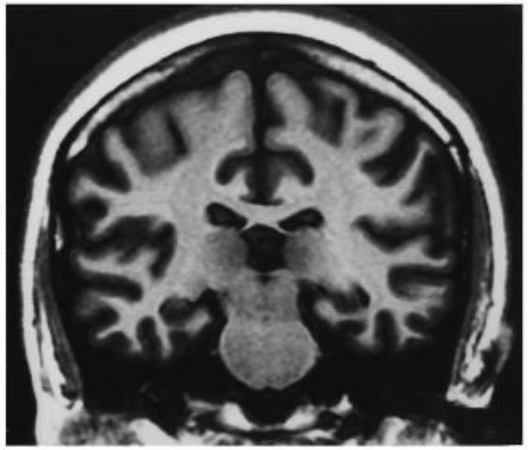

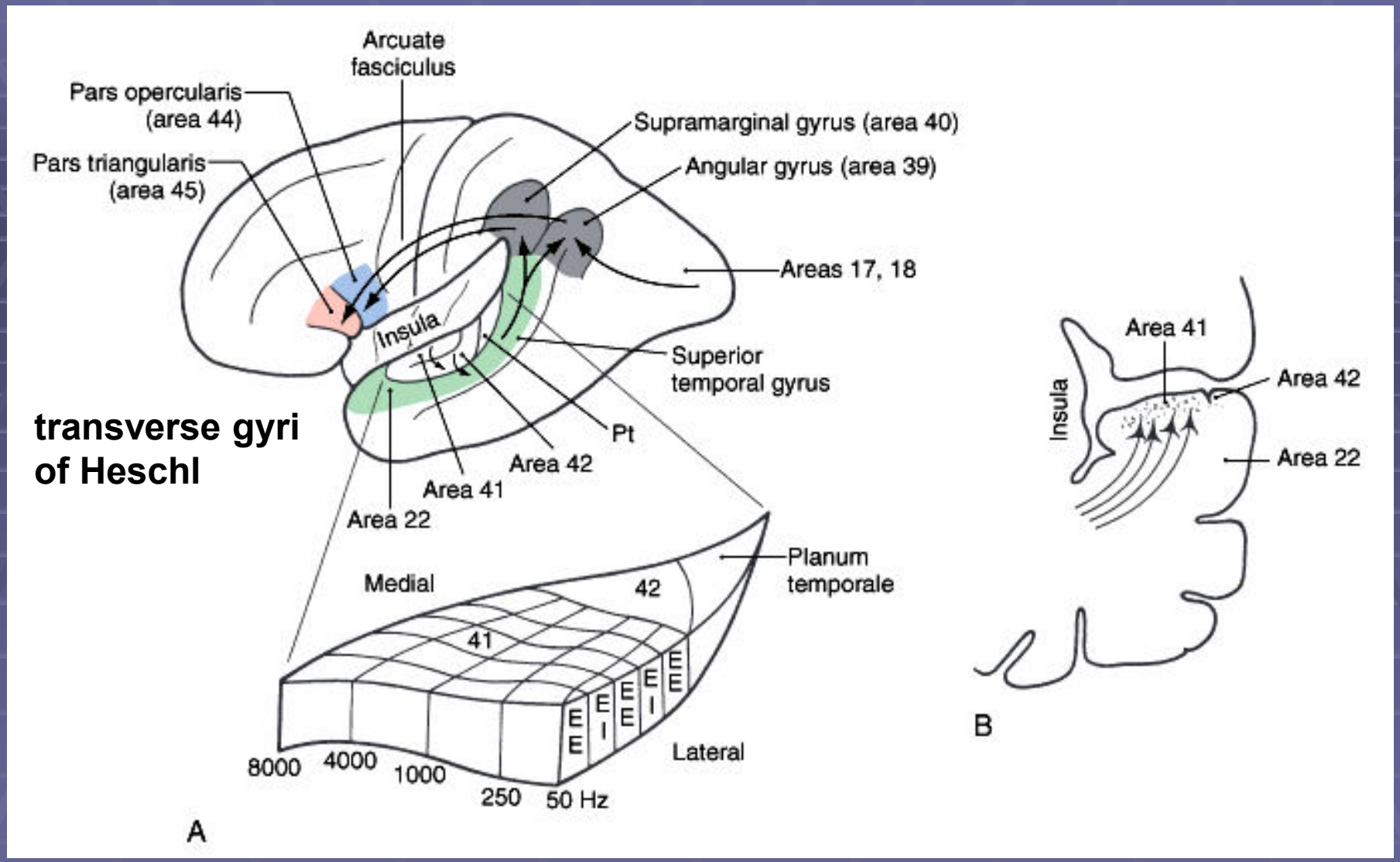
Arcuate fasciculus
Pars opercularis (area 44)
Pars triangularis (area 45)
Supramarginal gyrus (area 40)
Angular gyrus (area 39)
Areas 17, 18
Insula
Superior temporal gyrus
Pt
Area 42
Area 41
Area 22
transverse gyri of Heschl
Planum temporale
Medial
42
41
E
E
E
I
E
E
E
I
E
E
Lateral
8000
4000
1000
250
50 Hz
A
Area 41
Area 42
Insula
Area 22
B

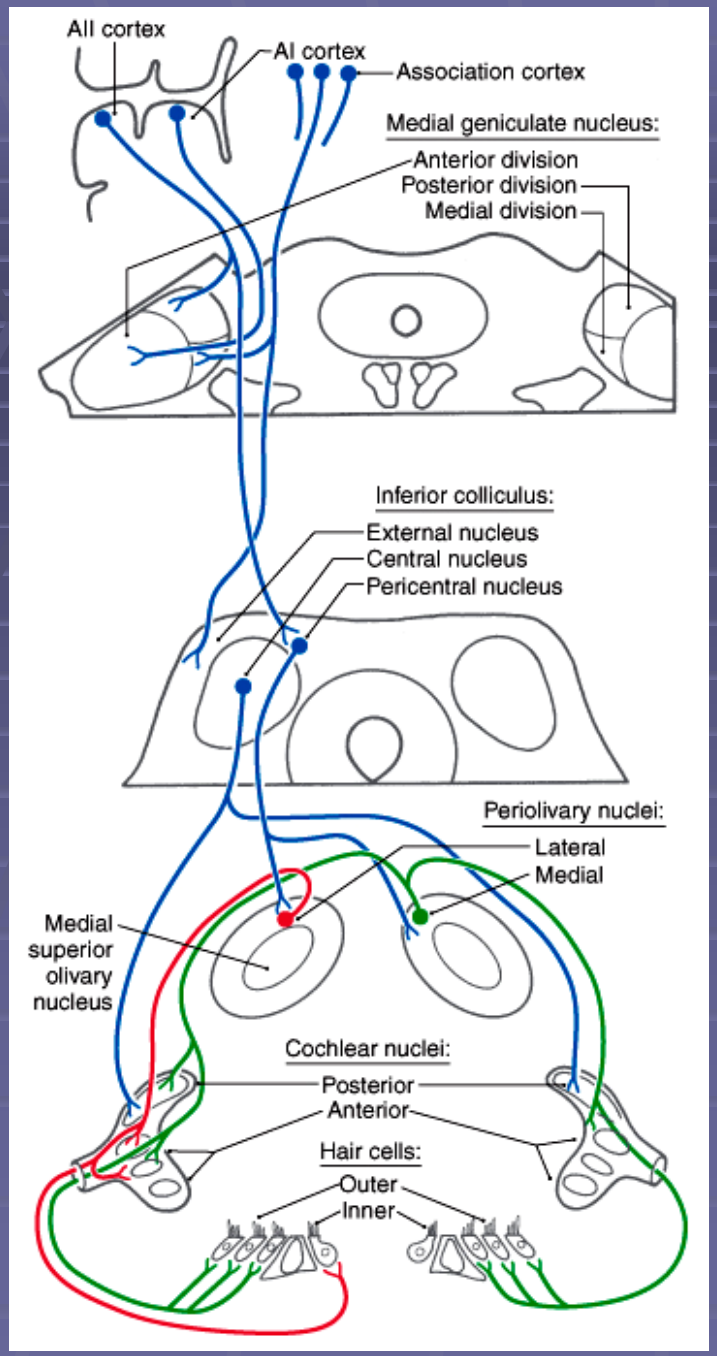

Olivocochlear descending feedback loop

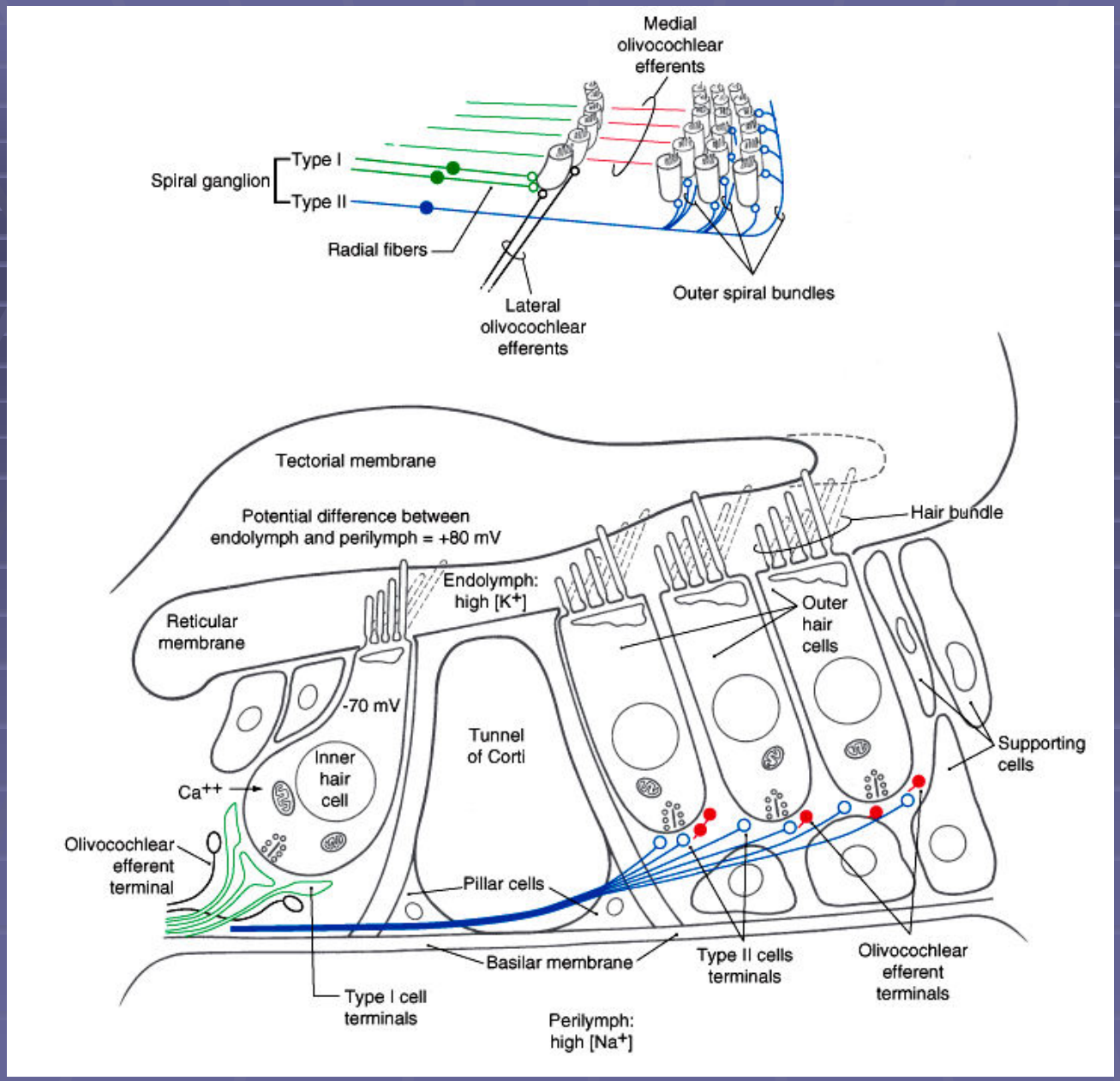
Medial olivocochlear efferents
Spiral ganglion
Type I
Type II
Radial fibers
Lateral olivocochlear efferents
Outer spiral bundles
Tectorial membrane
Potential difference between endolymph and perilymph = +80 mV
Hair bundle
Endolymph: high [K+]
Reticular membrane
Outer hair cells
-70 mV
Tunnel of Corti
Supporting cells
Inner hair cell
Ca++
Olivocochlear efferent terminal
Pillar cells
Basilar membrane
Type II cells terminals
Olivocochlear efferent terminals
Type I cell terminals
Perilymph: high [Na+]

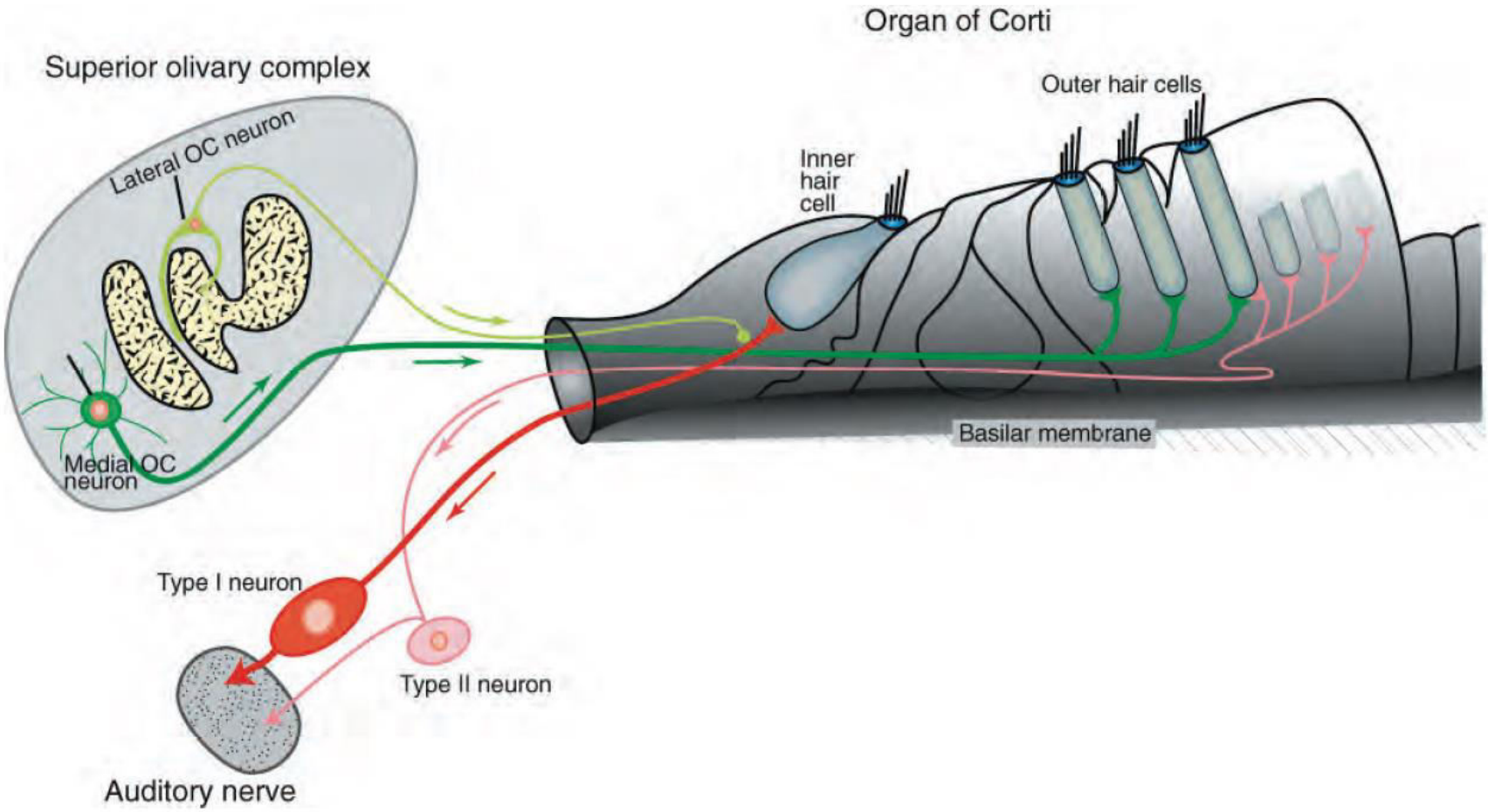
Organ of Corti
Superior olivary complex
Outer hair cells
Lateral OC neuron
Inner
hair
cell
Medial OC
neuron
Basilar membrane
Type I neuron
Type II neuron
Auditory nerve

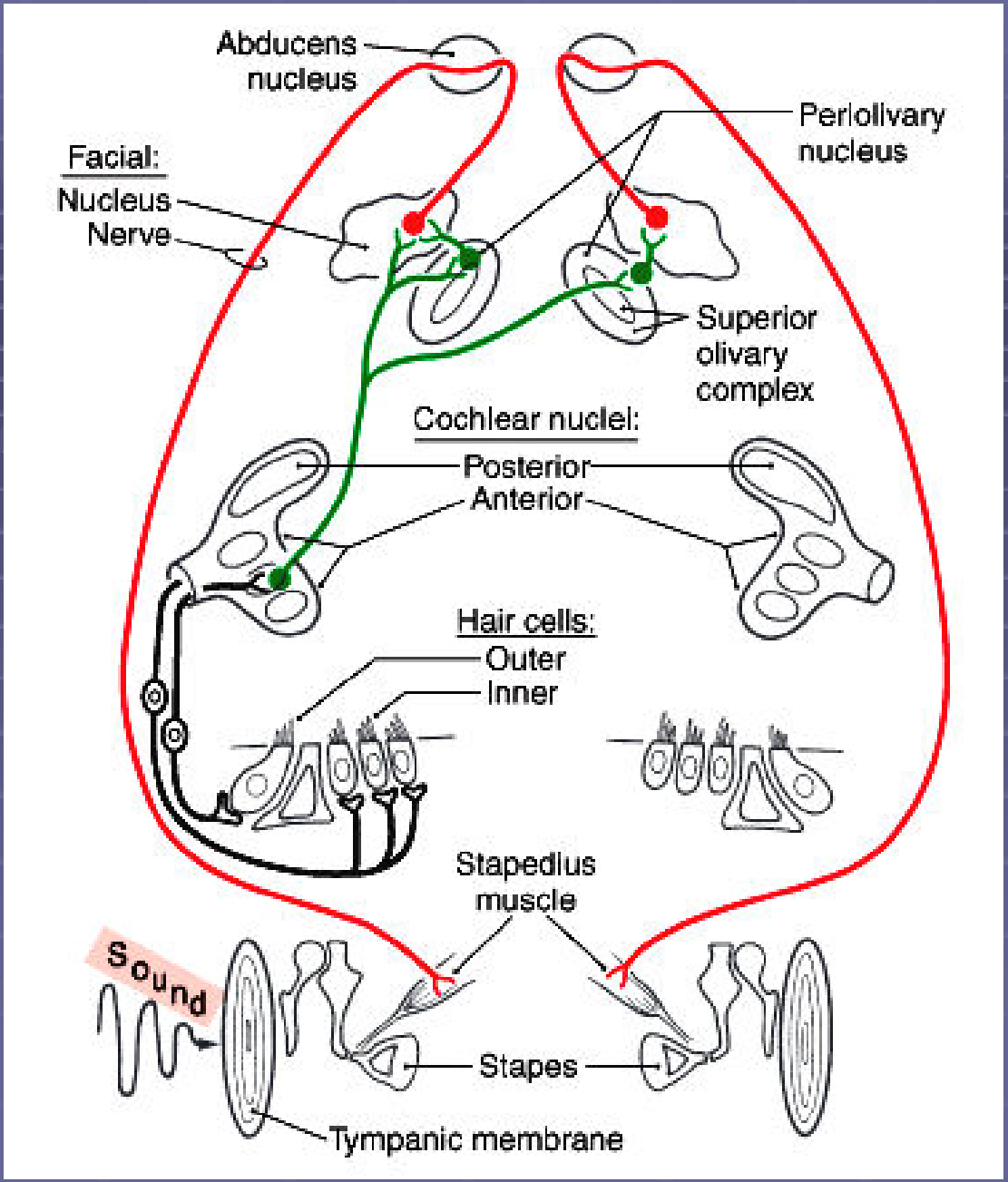

Middle ear reflex arc

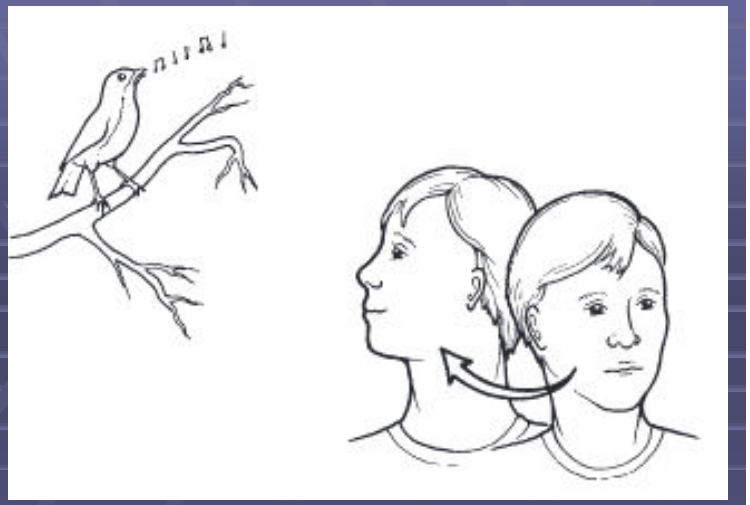

Acoustic startle reflex

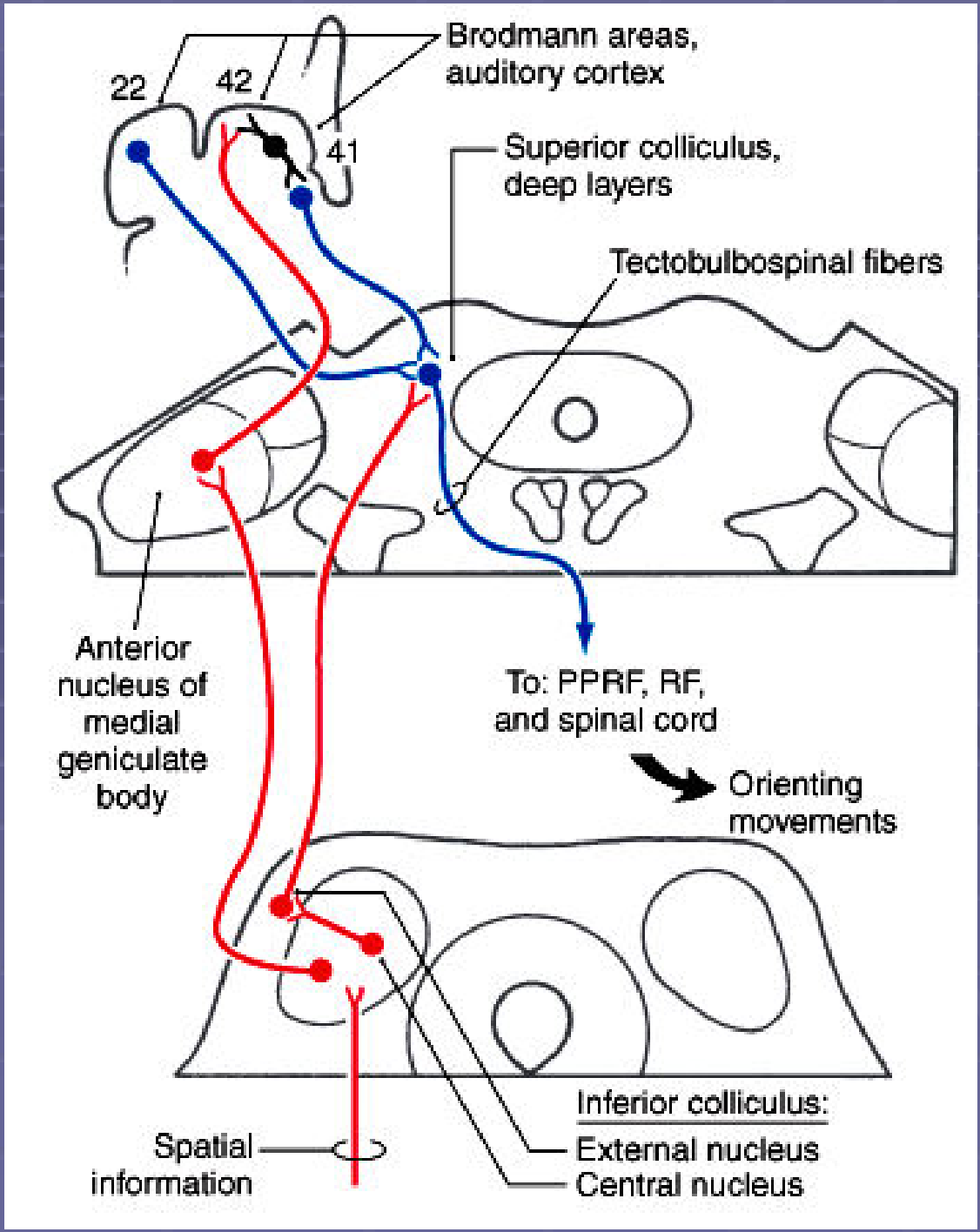

Types of Deafness

- **Conductive Deafness**
  - Due to impaired sound transmission in external and middle ear
  - Impacts all sound frequencies
  - Causes:
    - Plugging of the EAC with cerumen or foreign body
    - Otitis externa and otitis media
    - Perforation of eardrum
    - osteosclerosis

Types of Deafness

- **Sensorineural Deafness**
  - Due to loss of cochlear hair cells
  - Problems with CN VIII
  - Lesions within the Central Auditory Pathway
  - Impairs the ability to hear certain pitches (permanent)
  - Causes:
    - Aminoglycosides
    - Prolonged exposure to noise
- Tumors and vascular damage (presbyacusis)

Tinnitus

Some of these causes include
high blood pressure,
diabetes,
listening to loud music,
a tumor,
thyroid conditions,
and medications / antidepressants,
sedatives, antibiotics, anti-inflammatories,
and aspirin.

Pontine auditory hallucinosis

- an orchestra out of tune, buzzing insects, or strands of music. These perceived auditory events are accompanied by more typical symptoms of pontine lesions of auditory , such as cranial nerve deficits and long tract signs. A perception of noise or sounds may also be experienced by patients with temporal lobe seizures or a temporal lobe lesion that damages auditory cortices

Rinne and Weber Tests

Rinne's test

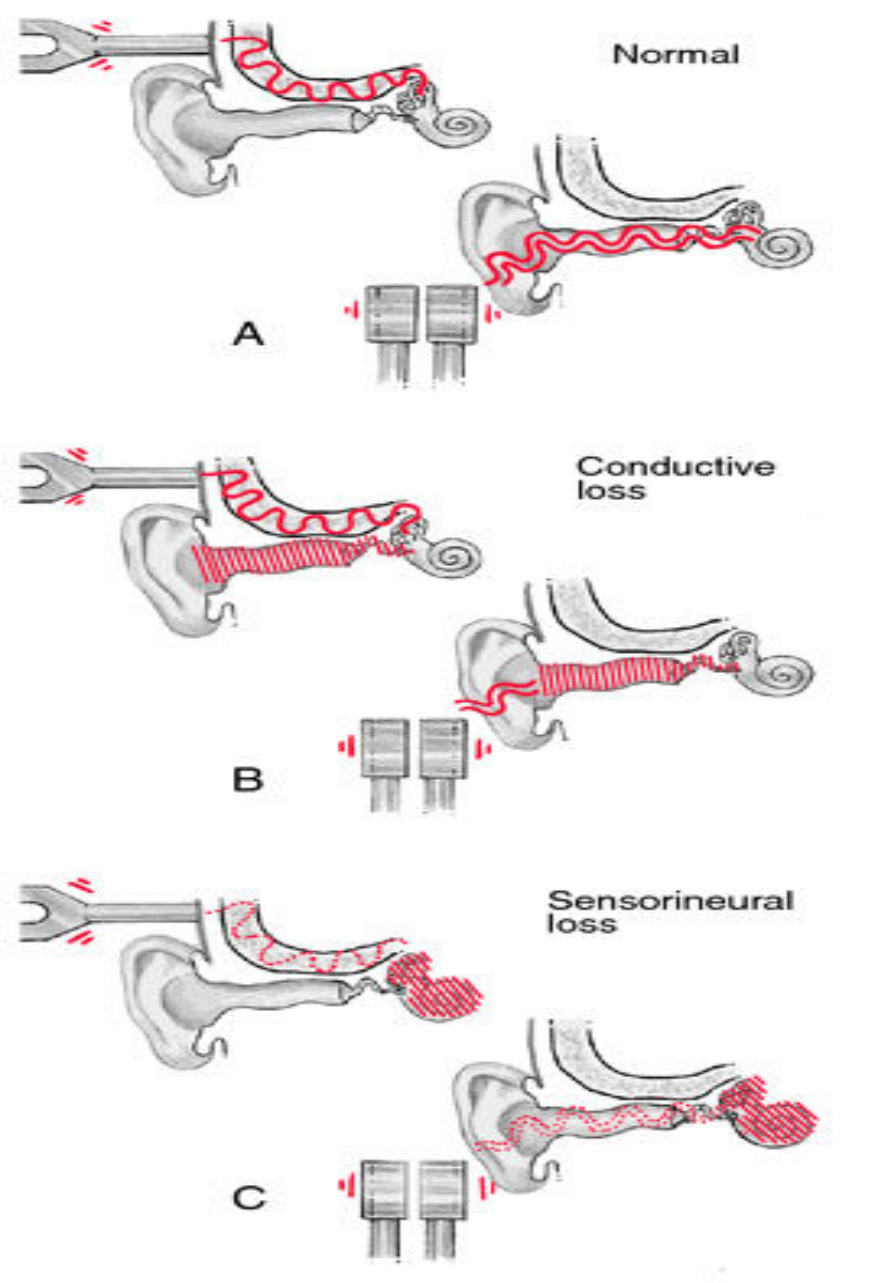

Weber’s test

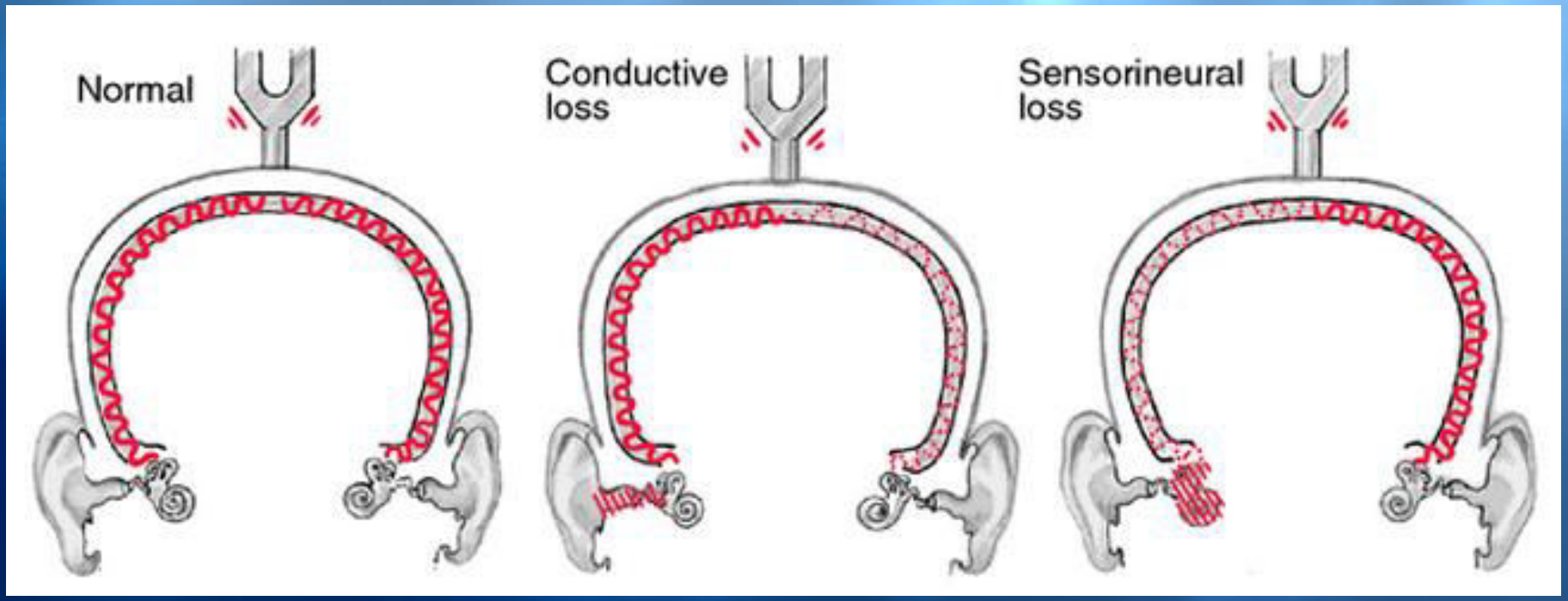

Table 13–1 Common Tests with a Tuning Fork to Distinguish between Sensorineural and Conduction Deafness.

	Weber	Rinne	Schwabach
Method	Base of vibrating tuning fork placed on vertex of skull.	Base of vibrating tuning fork placed on mastoid process until subject no longer hears it, then held in air next to ear.	Bone conduction of patient compared with that of normal subject.
Normal	Hears equally on both sides.	Hears vibration in air after bone conduction is over.	
Conduction deafness (one ear)	Sound louder in diseased ear because masking effect of environmental noise is absent on diseased side.	Vibrations in air not heard after bone conduction is over.	Bone conduction better than normal (conduction defect excludes masking noise).
Sensorineural deafness (one ear)	Sound louder in normal ear.	Vibration heard in air after bone conduction is over, as long as nerve deafness is partial.	Bone conduction worse than normal.