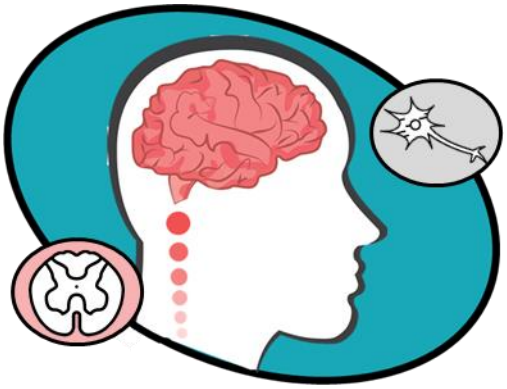

CNS

Anatomy

Sheet Slide

Number

1

Done by:

Dana Alrafaiah

Corrected by:

Raghad Abu Jebbeh

Doctor:

Maha Albeltagy

The nervous system

The nervous system is divided into two major divisions: the central nervous system (CNS) and the peripheral nervous system (PNS).

1- Central Nervous System: Brain & Spinal cord

It's named so because it's found in the center (middle) of the body: in the skull in which houses the brain, and the vertebral column which houses the spinal cord.

2- Peripheral Nervous System

The PNS is further divided into two divisions: autonomic and somatic.

- Autonomic nervous system (ANS)

The ANS is involuntary and controls your mood and state during stress and relaxation. It is present in nerves and is divided into sympathetic and parasympathetic.

The sympathetic is activated during stressful situation or in the *fight or flight response*. It increases the heart rate (>100-120 BP/min), secretion of sweat glands, causes **tachypnea** and flushing of the face.

The parasympathetic is activated during relaxation "*rest and digest*", has an opposite effect to the sympathetic: decreases the heart rate and blood pressure, no flushing of the face or activation of the sweat gland.

The effects of both divisions are facilitated by **neurotransmitters**. During stress **adrenaline** is released and it increases the activity of the body and causes the effects of the sympathetic system, while during relaxation, **serotonin** and **histamine** are released decreasing the activity and leading to the effects of the parasympathetic system.

- Somatic nervous system: cranial & spinal nerves

Cranial nerves: 12 pairs (24 in total) that originate from the brain and brainstem:

1- Olfactory nerve
2- Optic nerve
3- Oculomotor nerve
4- Trochlear nerve
5- Trigeminal nerve
6- Abducent nerve
7- Facial nerve
8- Vestibulocochlear nerve
9- Glossopharyngeal nerve
10-Vagus nerve
11-Spinal accessory nerve
12-Hypoglossal nerve

Spinal nerves: 31 pairs (one on each side) that originate from the spinal cord and correspond to vertebral segments. However, we know that there are 33 vertebral segments so where does this difference come from?

Remember the vertebral segments: 7 cervical, 12 thoracic, 5 lumbar, 5 sacral and 4 fused coccygeal segments.

The fused coccygeal segments give one nerve instead of four, cutting the number down to *30* spinal nerve pairs. The cervical segments give 8 instead of just 7 nerves; the additional nerve originates between foramen magnum and C1(also known as atlas). This is how we end up with 31 pairs of spinal nerves.

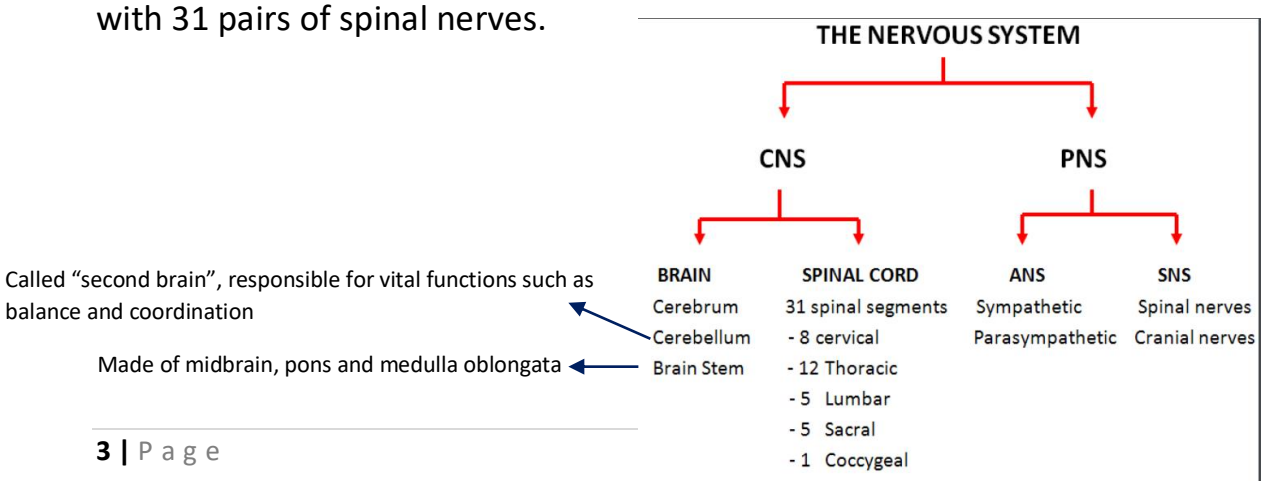

Histology of the nervous tissue

By studying the histology and structure of the nervous tissue, we can understand how synapse occurs and how the signal is transmitted.

The functional unit of the nervous tissue is the **neuron** (nerve cell). The classic nerve cell is formed of a cell body and its processes: a long process known as the **axon**, and short, hair like projections known as the **dendrites**.

The role of the dendrites is to bring the impulse from a distant site ***towards*** the cell body, they're therefore **afferent** and afferent fibres must be **sensory**. The axon takes the impulse ***away*** from the cell body and delivers it to a distant site or the effector organ, which can be a muscle -resulting in its contraction- or a gland -resulting in its secretion-. The axons are **efferent** and must be **motor**.

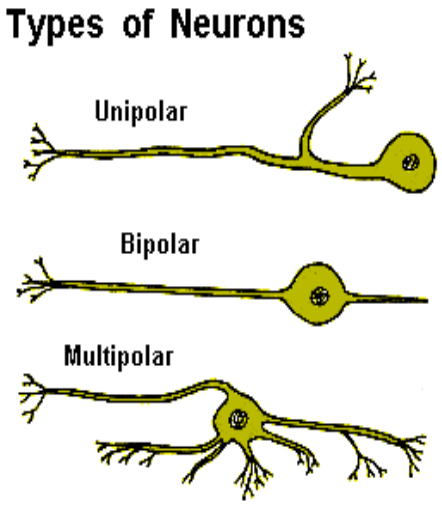

The neurons can take different shapes:

- Unipolar or pseudounipolar Unipolar:

Both the axon and the dendrites arise from the same point. We differentiate between them through their lengths: the axon is the longer projection and the dendrites are the shorter ones.

- Bipolar"classical nerve cells":

The axon and dendrites are at opposite ends of the cell body.

- Multipolar:

On one end: a single axon that ends with axon terminals into the effector organ. On the other end are many dendrites.

Functional classification of neurons

- Afferent (sensory) neurons: convey information from tissues and organs into the central nervous system (CNS).

- Efferent (motor) neurons: transmit signals from the CNS to the effector organs (muscles & glands).

For example: in order to lift a certain object up, a motor signal is delivered through certain tracts that are efferent to the muscles of the arm.

Another example: when someone is pinched by a needle, they reflexively move their finger away because a sensory impulse was delivered through the afferent fibers to the spinal cord. Through the spinal cord, this impulse is delivered to a certain region in the parietal lobe of the brain. Then a motor impulse is delivered from a motor region in the brain through efferent fibers to the effector muscle.

- Interneurons: those neurons connect other neurons (afferent or efferent) to the CNS. The greater the number of these neurons the more synapses will take place, resulting in higher intelligence and better high functions of the brain, such as: increased ability to learn, better thinking and judgment.

Contents of the cell body of the neurons:

The cell body is similar to that of other cells; it is composed of a nucleus and cytoplasm.

The nucleus is large, rounded and central with a prominent nucleolus. The nucleolus synthesizes ribosomes which synthesize proteins.

The cytoplasm contains organelles such as: ER, Golgi apparatus, mitochondria, lysosomes. However, it has no centrioles. The centrioles are responsible for the formation of mitotic spindles and division of cells, and nerve cells do not divide, so naturally they wouldn't be present. This is true of the mature cells "neurocytes", however immature cells "neuroblasts" are capable of dividing and so have centrioles.

Generally, we say that neurons don't regenerate, and that once the cell body is dead the nerve cell is lysed. However, it was found recently that in certain areas in the brain, we find the neurons able to regenerate or undergo *neurogenesis*. These areas include: the lateral ventricles and cells of the dentate gyrus (small part of the hippocampus at the base of the brain).

The following table compares between the dendrites and axons:

Dendrites	**Axon**
multiple	Single
Carry impulse to the cell body (afferent and sensory)	Carries impulse from the cell body to effector organs (efferent and motor)
Shape: wide base and tapering ends	Same diameter in all parts
Gives many branches	Gives few collaterals, it is mainly a single process surrounded by a **myelin sheath**
Contain neurofibrils and Nissl granules	Contains neurofibrils but no Nissl granules

Notes on the table:

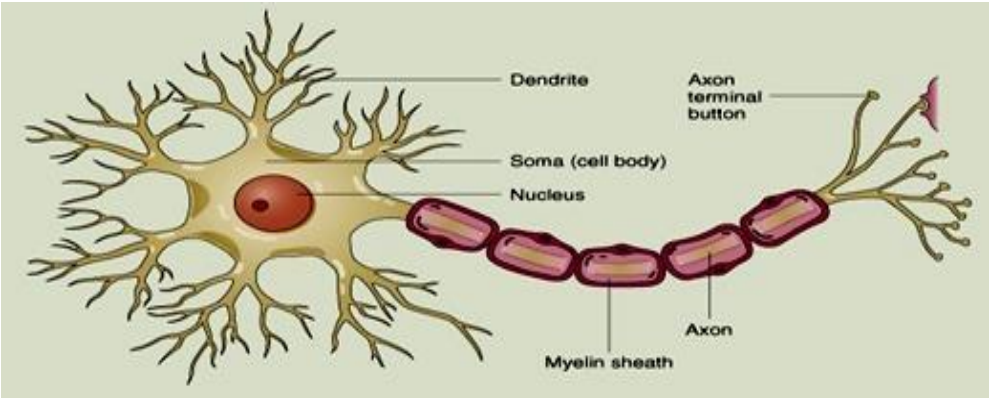

The cytoplasm of the dendrites is continuous and similar to the cytoplasm of the cell body.

Nissl granules are structures that are special to a nerve cell. They are present in the cell body and the dendrites but not the axons. They are responsible of protein synthesis.

The nerve fibres

This name refers to both axons and dendrites.

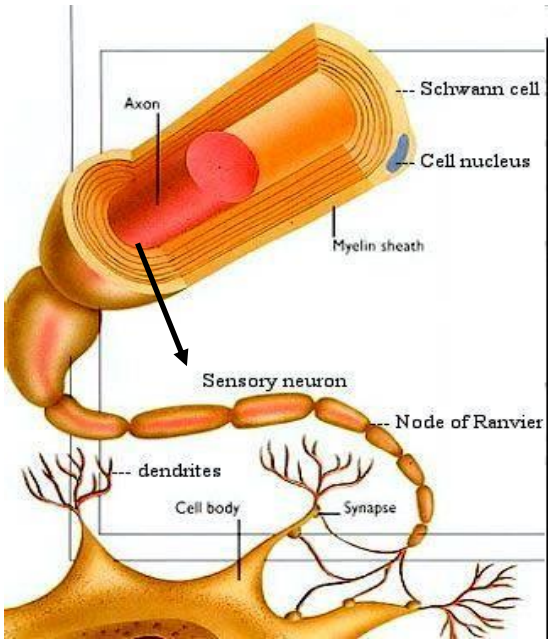

In the image below, the arrow points at the inner material of the nerve fibre. We find it to be surrounded by two sheaths for protection and insulation purposes as well as facilitating the transmission of the impulse.

The two sheaths are:

- <u>myelin sheath</u>

a thin layer of lipoprotein with constrictions along the axon every few millimetres. Those constrictions are called Nodes of Ranvier. This sheath is synthesized by **Shwann cells** outside the CNS and **Oligodendrocytes** inside it. Oligodendrocytes can synthesize myelin at multiple parts of the axon at same time through its multiple processes.

The formation of the myelin sheath is known as myelination. It starts before birth and can be completed before two years old or by the time walking occurs.

Unlike oligodendrocytes, which can synthesize myelin at multiple areas through its multiple processes in the CNS, Shwann cells can synthesize myelin at only one segment of the nerve cell. It encircles the axon and moves clockwise until it is completely surrounded by myelin.

Myelination is also known as regeneration; when the cell is damaged, Schwann cells attach to the site of injury and start rotating to form the myelin. Full repair is possible, but it takes time (usually 6 weeks) and also depends on the extent of the injury.

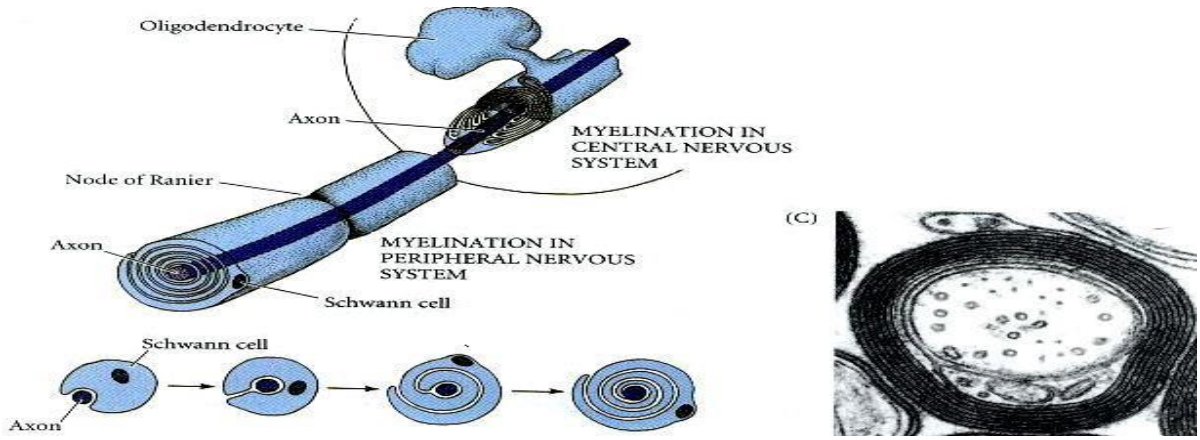

- <u>Neurilemma (Shwann) sheath</u>

It is the outermost covering. It looks like tubes. In myelinated nerve fibers it forms & envelops myelin segments. It is important for nerve regeneration after injury.

Some nerve fibres have the myelin sheath without the neurilemma sheath, such as neurons within the CNS, others have neurilemma without myelin sheath and some have both. It depends on the location of those fibres.

The nerve trunk

The trunk is composed of bundles of nerve fibres. There are three connective tissue covering for the nerve trunk. First: the nerve cells are directly covered by the **endoneurium**. They align together side by side and form *fascicles*, which are then surrounded by the **perineurium**. Finally, all the fibres in the nerve trunk are surrounded by the epineurium, the outermost covering.

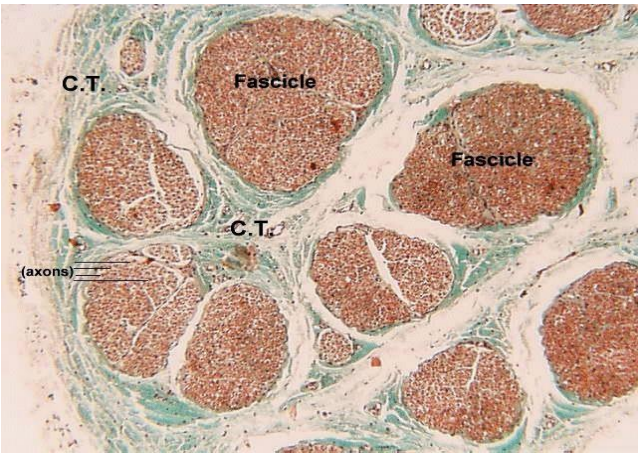

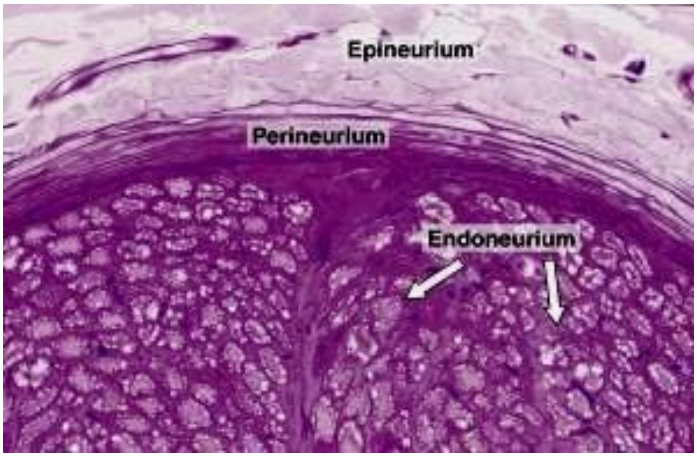

From outside to inside: epineurium, perineurium and endoneurium.

Nerve ganglia

A ganglion is a collection of nerve cells and nerve fibres surrounded by a connective tissue capsule **outside the CNS**. It is found along the course of the nerve.

Types:

- Spinal ganglia: related to the spinal cord, example: dorsal root ganglia which is located near the posterior horn of the spinal cord.
- Autonomic ganglia: Afferent fibres will rely impulse in it then efferent fibres will leave it to deliver the impulse to an effector organ. According to the location we can determine if it is sympathetic or parasympathetic. Example: the four parasympathetic ganglia in the head: ciliary, otic, pterypalatine and submandibular ganglia.
- Cranial ganglia

*Note: collections of nerve cells and nerve fibers **inside the CNS** are known as **nuclei.***

Glial cells

In addition to the neurons, the nervous tissue contains supportive cells known as glial cell.

Type	Origin (not required)	Location	Main Function
Oligodendrocyte	Neural tube	CNS	Myelin production, electric insulation
Schwann cell	Neural tube	Peripheral nerves (the only one)	Myelin production, electric insulation
Astrocyte	Neural tube	CNS	Blood-brain barrier, metabolic exchange, structural support, repair processes

Ependymal cell	Neural tube	CNS	Lining cavities of central nervous system
Microglia	Bone marrow	CNS	Phagocytic cells (protection)

Notes on the table:

Astrocytes attach to blood vessels that supply the CNS and its foot processes (extensions) connect to each other to form a border known as the **Blood Brain Barrier**. This barrier prevents toxins that can be circulating in the blood from entering the CNS and thus protects it from their effect. (more on these cells as we go)

Ependymal cells line spaces found within the membrane known as the ventricles, for example: we have two lateral ventricles in each hemisphere, third ventricle in the midline and the fourth ventricle between the cerebellum and brainstem.

These spaces contain cerebrospinal fluid (CSF), which circulates within them then moves to the subarachnoid space (space between the pia matter and the arachnoid matter) and circulates there as well. The circulation of the CSF will be further explained later in the course.

Astrocytes (Astron= star)

Remember: a cross section of the spinal cord would appear H-shaped, with dark areas called grey matter which has the nuclei, and pale areas called white matter which has the axons.

There are two types of astrocytes; fibrous and protoplasmic. The fibrous are found in the white matter, are less branched and less condensed. The protoplasmic are the opposite: they are more branched and more condensed, and they are found in the grey matter. Both types attach to

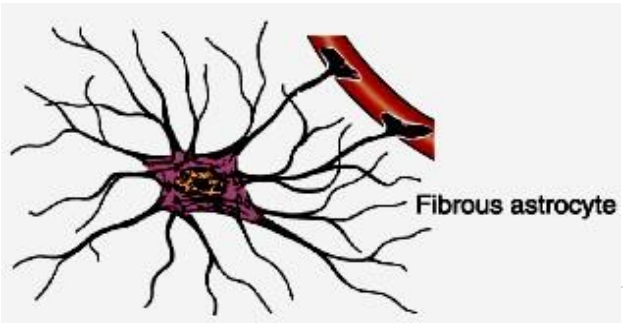

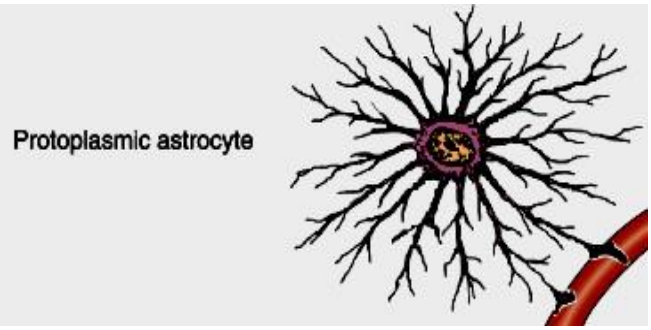

blood vessels to form the blood brain barrier.

Anatomy of the central nervous system

Consists of:

The brain within the skull, composed of three parts: the cerebrum, below it the cerebellum, also known as the second brain and involved in balance, coordination and planning, and at the bae of the brain and anterior to the cerebellum is the brainstem. The brainstem has three parts: midbrain, pons, medulla oblangata.

The spinal cord within the vertebral canal; the medulla oblangata passes foramen magnum into the vertebral canal and continues as the spinal cord.

The brain

- Cerebrum

Made of two hemispheres that are separated from each other by a longitudinal median fissure. The space between the two hemispheres contains a dural fold called **falx cerebri,** this fold is attached interiorly to the skull vault.

The two hemispheres are not completely separate (not all the way down), in the lower part there are fibres that connect them together, those fibres are called **corpus callosum**.

There different types of fibres in the brain: **commissural** fibres which connect the same places on the right and left hemisphere, **association fibres** that are present within the brain itself and connect two different places and **projection fibres**. *Corpus callosum is the biggest commissural fibre in the brain.*

In the absence of corpus callosum, there would be no connection between the two hemispheres, resulting in a very strange condition where one half of the body doesn't recognize the other due to this

dissociation. This condition is called **apraxia**. (further discussed in the lesions lecture)

if we were to cut the corpus callosum and separate the two hemispheres completely (a sagittal section), we would be able to see the parts of the corpus callosum. Anteriorly to posteriorly: Rostrum, Genu, Body and splenium.

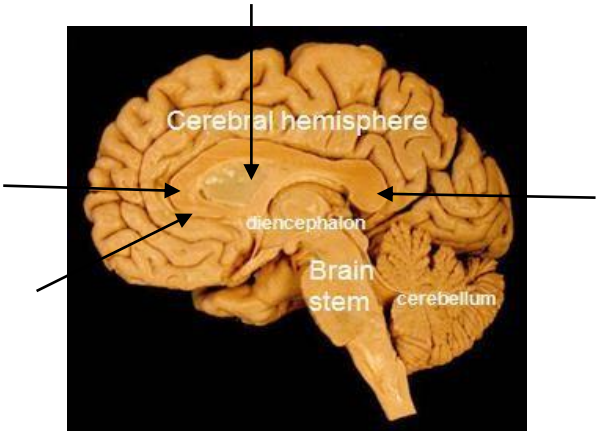

Behind the corpus callosum, we find a structure that appears like a membrane, called **septum pellucidum**. If we remove it a space appears, this is the **lateral ventricle**, there is one in each hemisphere.

Below the corpus callosum is a commissural fibre called the **fornix**. Below the fornix is a very important structure called the **thalamus**. The thalamus is known as the *secretary of the brain*. All sensation from the body (smell, vision, taste etc) gather here before it distributes them to the corresponding region in the brain. The thalamus then is a rely station to all sensation.

Below the thalamus we find the **hypothalamus**, and associated to it also are the **epithalamus**, **subthalamus** and **metathalamus**. All of those together are called the **dienencephalon** or **interbrain**- due to its location between the right and left hemispheres.

There's a space between the two diencephalon parts that is slit shaped (not large), it is called the **third ventricle**, which communicates from below with the forth ventricle and from above with the lateral ventricles.

- Brainstem

1. Midbrain
2. Pons
3. Medulla: last part that continues as the spinal cord after leaving through foramen magnum.

- Cerebellum

Has two hemispheres; right and left. The two hemispheres are connected by a structure known as the **vermis**. The vermis carries vital information from the cerebrum to the cerebellum then to the spinal cord. This is extremely important in planning and motor coordination and without it the cerebellum is of no use. As a result, the vermis is often called *the tree of life*.

Between the cerebrum and the cerebellum is a space called the fourth ventricle.

Embryology of the central nervous system

Development of the CNS begins early in the intrauterine life. During fourth week of development the neural tube is formed and gives three vesicles: the forebrain, midbrain and hind brain.

- Forebrain

Forms a “ball” on either sides, which give the **two hemispheres**, and one “ball” in the middle which gives the **diencephalon**.

- Midbrain

Gives only the **Midbrain**: the second part of the brainstem.

- Hindbrain

Gives everything else: the pons, medulla oblangata and the cerebellum.

Note: the table in slide 18 in not required now and will be explained completely in the embryology lecture(lect.10).

Don’t forget to refer to the slide

The End