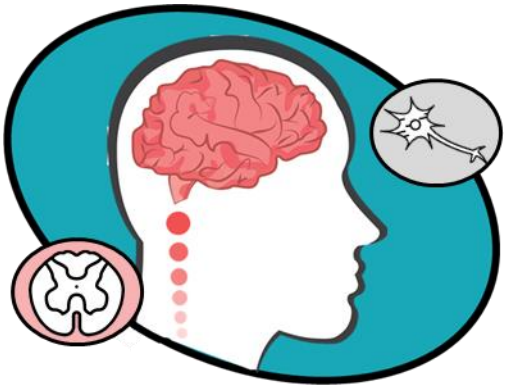

CNS

Anatomy

Sheet Slide

Number

-3

Done by:

-Zeina Assaf

Corrected by:

-Omar Odeh

Doctor:

- Maha Beltagy

The Inferior Surface Of The Brain

The inferior surface of the brain is divide by the stem of the lateral fissure into 2 parts : The orbital surface and the tentorial surface .

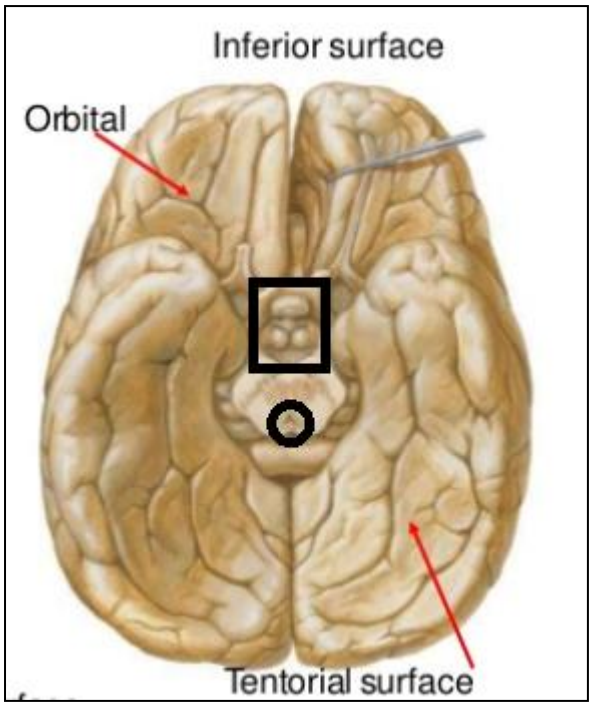

-The orbital surface , which is anterior to the stem of the lateral fissure, is named so because it is laying on the orbital plate of the frontal bone .

-The tentorial surface ,which is posterior to the stem of the lateral fissure , is named so in relation to the tentorium cerebelli; which separates the occipital lobes of the cerebrum superiorly from the cerebellum inferiorly.

The circled structure is known as the cerebral aqueduct which connects the third ventricle in the diencephalon and the fourth ventricle .

While the square represents the interpeduncular fossa . This fossa contains circle of Willis which supplies blood to the brain and the surrounding structures.

The cerebral peduncles are structures at the front of the midbrain which arise from the front of the midbrain connecting the cerebrum with the midbrain .

The orbital surface's sulci and gyri :

Sulci:
1-Olfactory sulcus : It is overlapped by the olfactory bulb & tract.
The olfactory bulb is a collection of sensory neurons involved in olfaction ,initially those nerves pass through the cribriform plate which continues as the olfactory bulb then olfactory tract and then it divides into medial and lateral olfactory stria.
Between the medial and lateral olfactory stria is the anterior perforated substance from which the anterior and middle cerebral arteries pass to supply the brain.

While the posterior perforated substance is situated in the interpeduncular fossa allowing the posterior cerebral artery to supply the brain, and it is the last branch of the brain's blood supply.

2-Orbital sulci (H-shaped) divide the remaining part into anterior, posterior, lateral and medial orbital gyri.

Gyri:
1-Gyrus rectus : lies medial to the olfactory sulcus, continuous with superior frontal gyrus on the superolateral surface.

2-Orbital gyri, which are named respectively according to their location in relation to the orbital sulci; anterior, posterior, lateral and medial.

The tentorial surface's sulci and gyri:
Sulci:
1-Hippocampal sulcus : separates the parahippocampal gyrus from the midbrain . The hippocampus is found in the parahippocampal guyrus and is associated with short-term memory .

2-Collateral sulcus

3- Occipito-temporal sulcus

These 3 sulci separate the tentorial surface into 3 gyri; parahippocampal, medial occipitotemporal, and lateral occipitotemporal

4-Rhinal sulcus which is the anterior part of the collateral sulcus separates the temporal pole from the uncus.

Uncus is the anterior part of the parahippocampal gyrus ,within it there is a nucleus known as amygdala this nucleus is part of the limbic system which is associated with memory, sexual behaviour, smell, personality , and it is also a part of the basal nuclei. There are 4 basal nuclei; caudate, lentiform, amygdala, and claustrum nuclei, and they are associated with regulating motor functions by the release of excitatory and inhibitory neurotransmitters.

Important: The uncus and the anterior part of the parahippocampal gyrus form the Rhinencephalon or the pyriform fossa which is responsible of smell sensation.

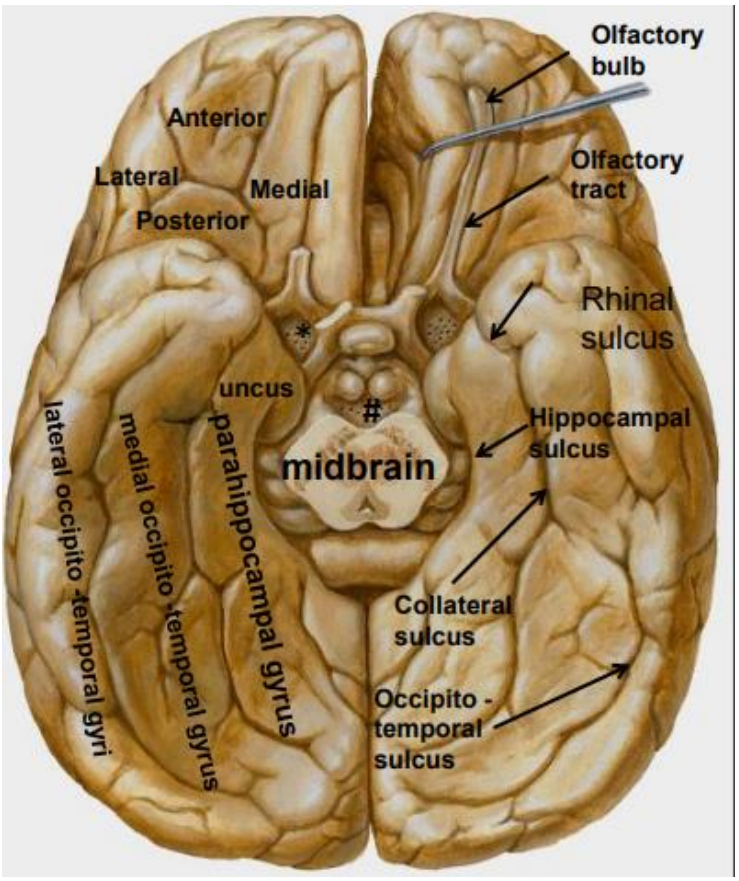

(*) represents the anterior perforated substance

(#) represents the posterior perforated substance

The Functional Areas Of The Brain

The most popular classification is Brodmann's classification. (47 areas)

The cerebral cortex is divided into 3 areas; motor, sensory, and association. These areas are subdivided into primary motor areas, primary sensory areas, secondary motor or sensory areas. Association areas are responsible for understanding received signals, and they are usually present around primary centers.

Motor areas:

1-Primary Motor Area (M I) area 4:

Site: precentral gyrus of lateral surface of the brain

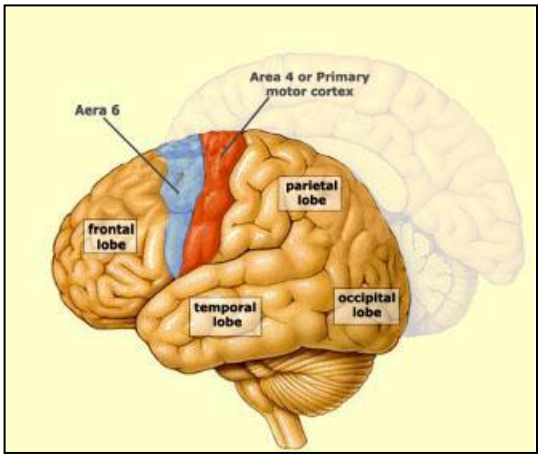

Giant pyramidal cell of Betz (5th layer) is well-developed in this motor area forming the pyramidal tract which is responsible of carrying motor impulses that are responsible of regulating fine specific discrete movements of the extremities (hands and feet) on the contralateral side of the body. Excitatory to muscle tone .

Afferent to the primary motor area is the premotor area 6 (40%). It is located in front of the precentral gyrus which is responsible of coordinating coarse movements of the trunk, hips and shoulders. This area contains the extra-pyramidal tract and sends afferent fibres to motor area 4 to coordinate the fine specific movements with coarse movements, this allows us to perform functions which require both fine and coarse movements such as sitting straight and writing.

Other areas in the brain are also responsible of coordinating the coarse movements and sequential movements, those areas include: basal nuclei, extrapyramidal pathway of the cerebellum plus premotor area 6

as mentioned above.

Lesion: contralateral hemiplagia, paralysis of the opposite side of the body. Also known as the upper motor neuron syndrome

Upper motor neuron means motor neurons that originate in the motor region of the brain which send fibers through a specific pathway that will eventually reach the nucleus of the anterior horn of the spinal cord .

Lower motor neuron which are the neurons that supply skeletal muscle fibers .Example: cranial and spinal nerves

So the nucleus of the anterior horn of the spinal cord discriminates the upper motor neuron and the lower motor neuron .
Before the nucleus :UMN after the nucleus :LMN

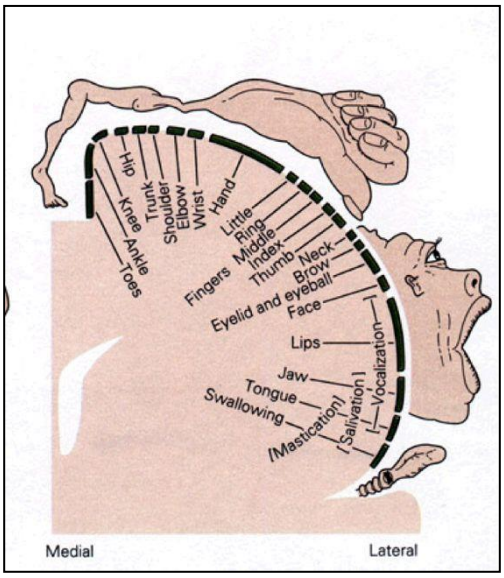

*A cortical homunculus is a distorted representation of the human body, based on a neurological "map" of the areas and proportions of the human brain dedicated to processing motor functions, or sensory functions, for different parts of the body. Homunculus is a Latin word which means little man.

It was found that the lower part of the precentral gyrus was the area responsible for the movement of the muscles of the face, mastication, and vocalization. It was found that (in an ascending order), areas represented the motor supply to the fingers, hand, shoulders, trunk, hip, and lower limb. Keep in mind that the paracentral lobule is responsible for movement of the lower limb and perineum

The representation of any part depends on the skills of the motor area rather than the surface area of the organ itself.

2-premotor area 6 (Extrapyramidal center) (secondary motor area)
Site: in front of area 4 broad superiorly and narrow inferiorly (inverted triangle in the superior and middle frontal gyri)

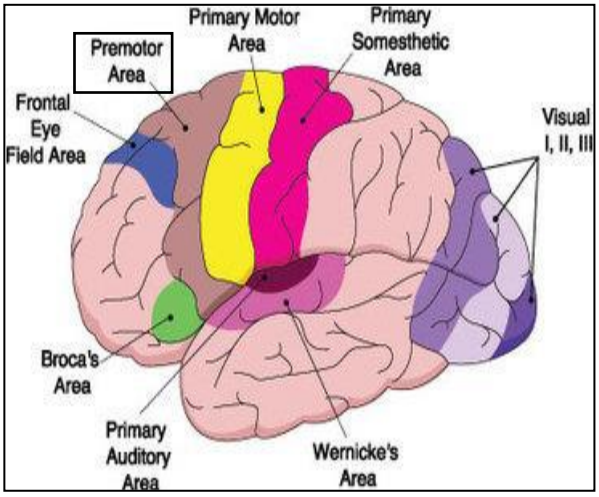

Function: storing motor programs of sequential and coordinated movements (typing, running…) ,coordination of coarse movement mainly trunk, shoulders and hip muscles.

Inhibitory to muscle tone, Sends inputs to M4

Lesion: motor apraxia, spasticity, loss of postural stability.
-Motor apraxia: individual has difficulty with the motor planning to perform tasks or movements, in the **absence** of paralysis as there are other areas in the brain which still sends motor supply to the muscles.

Motor apraxia also can be caused by lesions of the corpus callosum where the two halves of the body will function separately. An example for motor apraxia can be seen when your patient can move but performs some of the simple acts in a wrong way, as an example they might not be able to brush their teeth properly or wear their t-shirt in an incorrect way.

-spasticity: since the premotor area is inhibitory to muscle tone , a lesion in this area will increase the muscle tone since the primary motor area is dominant in this case.

3-Supplementary Motor Area (SMA) Extrapyramidal centre:

Site: Mostly on the medial frontal gyrus anterior to paracenteral lobule, as a continuation of the premotor area 6

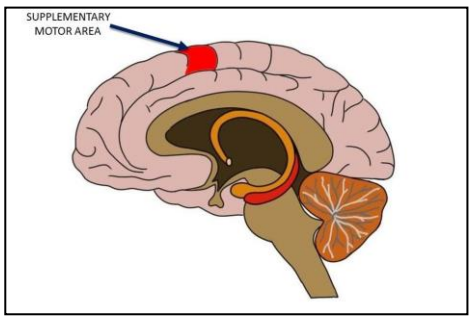

Function: postural stabilization of the body, the coordination of both sides of the body and the control of **sequences** of movements.

Lesion: not definite; a lesion won't cause significant manifestations.

4-Frontal eye field area 8

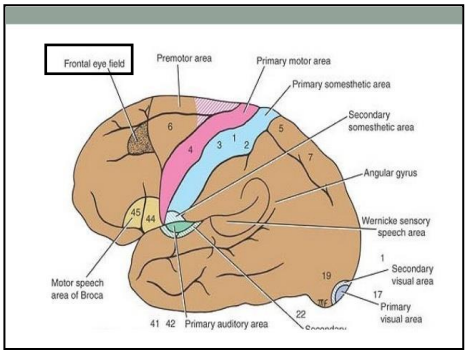

Site: in front of premotor area mainly middle frontal gyrus

Function: **voluntary** tracking movement (conjugate movement) to the **opposite** side

While the occipital eye field is responsible of reflex movement of both eyes.
Lesion: deviation of both eyes to **same** side of lesion

5-Brocca's area (motor area of speech)44,45

Site: inferior frontal gyrus. Mainly on the dominant hemisphere.

Function: coordination of muscles of larynx, mouth, tongue and palate.

Connected to Wernicke's area which is responsible of understanding both written and spoken words. A lesion in Wernicke's area will lead to sensory aphasia .

Lesion: (motor aphasia) non-fluent aphasia

Motor aphasia: **Broca's aphasia**, is a type of aphasia characterized by partial loss of the ability to produce language, although comprehension generally remains intact. A person with motor aphasia will exhibit effortful speech. Speech generally includes important content words, but leaves out function words .

For example if a person with motor aphasia wants to say he went shopping , had lunch and then slept .He might say the important words such as shopping, lunch, sleep only.

A person with motor aphasia will be aware of his problem and this will cause depression.

Wernicke’s aphasia: Persons with Wernicke’s aphasia can produce many words and they often speak using grammatically correct sentences with normal rate and prosody. However, often what they say doesn’t make a lot of sense or they pepper their sentences with non-existent or irrelevant words. They may fail to realize that they are using the wrong words or using a non-existent word and often they are not fully aware that what they say doesn’t make sense.