CNS

Anatomy

Sheet Slide

Number

6

Done by:

مَها أبو عجميّة

Corrected by:

Dergam Al-Tarawneh

Doctor:

Maha ElBeltagy

"وَ قُل رَّبِّ زِدْنِي عِلْمًا {سورة طه : 114}

- The doctor corrections are in red, preceded by #.
- The not-an-exam-material slides are not included in the midterm exam but we're going to take them later in this course and study them for the final exam.
- In the previous lecture, we have talked about the ventricles, the only thing that is not included in the midterm is the floor of the fourth ventricle.
- The doctor has repeated some points from the previous lecture; the roof of the fourth ventricle and how this ventricle is connected with other ventricles and the spinal cord (the angles of the 4th ventricle).
- The doctor said that Interpeduncular fossa was explained in the online material

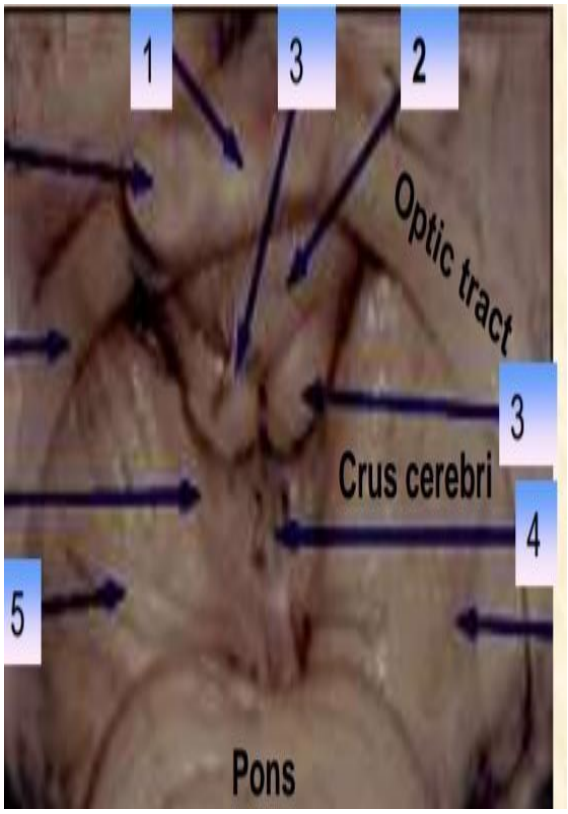

Its Boundaries,

Anterior: Optic chiasma (**1**).

Posterior: Pons

#**Posterolateral**: - Optic tract & crura cerebri

Its Contents:

- Tuber cinereum (**2**) – to which is attached the infundibulum where we find the pituitary gland. -Mammillary bodies (**3**)

-Posterior perforated substance (**4**)

-Oculomotor nerve (**5**) emerges from the medial aspect of crus cerebri.

- we will take the cranial nerves after the midterm exam, the only thing you should know is that cranial nerve four (IV) "the trochlear" is the only one that could be seen from the posterior aspect of the midbrain.

CSF

Some areas contain more cerebrospinal fluid (CSF) than other areas, if **more CSF** was present in a particular area, this would indicate that this area requires **more protection**, (dangerous area) some examples on these areas are subarachnoid cisterns.

Subarachnoid cisterns:

- Additional note (you can skip), its definition: subarachnoid cisterns are discrete spaces or openings within the subarachnoid space, they are filled with CSF, (Remember that subarachnoid space is the space between the arachnoid mater and pia mater that surround the brain and spinal cord.) ● The major 6 subarachnoid spaces are:

1- **Cerebello-medullary cisterna (Cisterna magna)**: this cistern is between cerebellum and roof of the fourth ventricle, it receives CSF from the fourth ventricle via foramen of Magendie, it contains more CSF in the back of medulla oblongate, why? because it contains important centers such as, respiratory, cardiac, emetic (vomiting) and others.

2- **Pontine (ponto-medullary) cistern**: this cistern is found in front of pons (slide: and medulla), it contains basilar and vertebral arteries and it receives CSF via two 2 lateral foramens (foramens of Luschka), it is transversed by roots of lower 8 cranial nerves

(note: basilar artery is formed by the joining of 2 vertebral arteries, and at the upper border of pons, the basilar artery divides into a pair of posterior cerebral arteries)

To supply the posterior aspect of the brain, thalamus, lateral and medial geniculate bodies.

3- **Chiasmatic cistern**: it lies around optic chiasma 4- Cisterns around the arteries:

a- Interpeduncular cistern: it lies over interpeduncular fossa, it contains circle of Willis and is transversed by roots of 3rd and 4th cranial nerves

b- Cistern of lateral fissure: it contains the middle cerebral vessels.

c- Callosal cistern: (on the medial surface of the brain) it lies above corpus callosum and it contains anterior cerebral vessels (remember: anterior cerebral artery could be found in the callosal sulcus)

What is CSF?

- Its definition: The Cerebrospinal Fluid (CSF) is the fluid filling the ventricles & central canals of the CNS and subarachnoid spaces around brain and spinal cord.
- Production of CSF: It is secreted by the choroid plexuses, ○ the location of choroid plexus: the choroid fissure between the thalamus and fornix is where the choroid plexus's lodged, the choroid plexus enters the inferior horn and body (the medial wall) of the lateral ventricles & the roof of the 3rd ventricle & the inferior half of the roof of the 4th ventricle, by entering the foramen of Magendie forming a **T-shaped** with 2 limbs, each of which goes through foramen of *Luscka.*

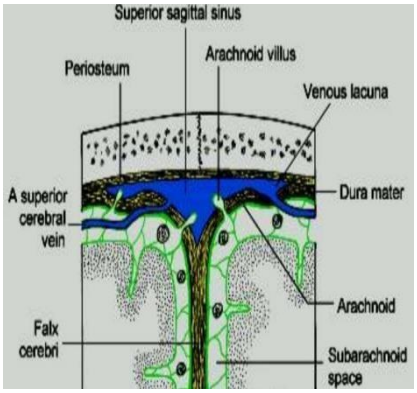

○ the involved vessels:

1- The choroid plexus of the lateral ventricle is formed by posterior and anterior choroidal arteries.
2- The choroid plexus in the 3rd ventricle is formed by the posterior choroidal artery.
3- The choroid plexus in the 4th ventricle is formed by Posterior inferior cerebellar artery (PICA).

You should know the different locations of choroid plexus and the arteries that are involved in forming it.

- Circulation of CSF: It circulates in the ventricles & central canals of the CNS. Beginning from the **lateral ventricles** (the majority of CSF is produced from within the lateral ventricles) then it leaves the lateral ventricle through interventricular foramen (foramen of Monro) to the **3rd ventricle** then through cerebral aqueduct of midbrain to the **4th ventricle** & leaves either directly to **the spinal cord** through central canal or to the **subarachnoid space** through 3 apertures (Magendie and 2Lusckae) forming a water cushion to protect the brain & spinal cord.

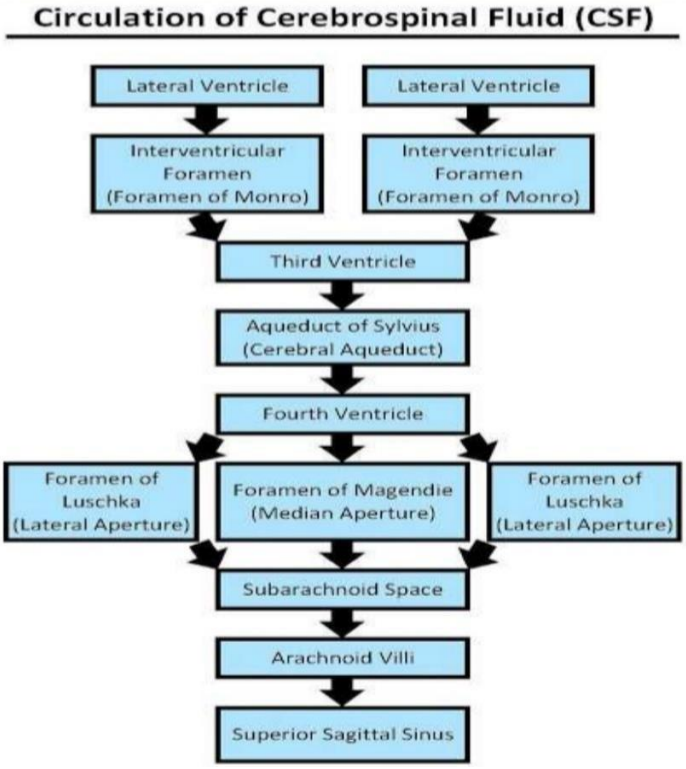

- An action that counteracts the secretion of CSF should take place, absorption of CSF should occur to reach a balance .
- Absorption of CSF: CSF is absorbed and collected by finger-like projections that are called arachnoid villi (subarachnoid granulations) in subarachnoid space, these granulations will force the CSF into superior sagittal sinus which is found in falx cerebri, then collects it to venous circulation (from the right transverse sinus to the internal jugular vein to drain it back to the heart).

Lab note: This occurs 3 times a day.

Question: if resorption of CSF was decreased/blocked, or secretion was increased, what would happen? increasing the CSF which will lead to:

1- The separation of the skull bones in newborns (because the sutures not closed yet).
2- Hydrocephalus which is the accumulation of (CSF) within the brain (could be either communicating/non-obstructive or

noncommunicating/obstructive), some symptoms and signs: a- Seizures and other motor manifestations. b- Projectile vomiting (without nausea).

c- Sunset eyes (downward deviation of the eyes) because of compressing both oculomotor and trochlear nerves.

IMPORTANT NOTE: Choroid plexus **secretes** CSF and arachnoid plexus **absorbs** CSF.

Lumbar Puncture

Lumbar puncture is a procedure by which CSF is taken out from the subarachnoid space.

From where it is taken? The spinal cord terminates at lower border of L1, but the subarachnoid space terminates at S3, meaning that we can find CSF without spinal cord from L1 to S3, although there would be cauda equina nerves there, taking CSF from there would not be as risky as injuring the spinal cord (there would be less damage anyway), the CSF is drawn by introducing a needle between the 3rd and 4th lumbar vertebrae where the subarachnoid space is wider).

Purposes of Lumbar Puncture:

1- diagnostic purposes, such as:
   a- infections such as meningitis if bacteria was detected in the CSF sample.
   b- Subarachnoid hemorrhage (probably in the brain) if there was blood in the CSF sample. c- Jaundice if there was Xanthochromia (additional note: Xanthochromia: the term used for CSF stained yellow with bilirubin).
2- Spinal Anesthesia, in cesarean section and other surgical procedures that requires local anesthesia. 3- Measuring CSF pressure.

Papilledema

Optic nerves are surrounded by pia mater, arachnoid mater and dura mater, meaning that the subarachnoid space is extending around optic nerve to the back

of eyeball, so any increase in CSF pressure would lead to the compression of the retinal vessels, this will cause congestion of the retinal vein and bulging of the optic disc, and as a result, optic atrophy and blindness.

Blood Brain Barrier BBB

the most important piece of information is that astrocytes are important for this blood brain barrier.

(slides)

- Its definition: This barrier is present between the brain and the blood.
- Its structure: The capillaries of the brain consist of endothelial lining which have tight junctions which close the pores in the blood vessels - Astrocytes completely cover the capillaries and make it less porous - The blood vessels have a thick basement membrane.
- It exists in all parts of the brain except hypothalamus, pineal gland and area posterem.

The Blood CSF Barrier (copied from the slides)

The barrier between the blood and CSF exists at the choroid plexus whose function is similar to blood brain barrier. Doesn't allow the entry of substances into the CSF from the blood.

The brainstem is composed of 3 parts: 1) midbrain 2) pons 3) medulla.

Cerebellum

The cerebellum is located below the brain (cerebra), and separated from it by tentorium cerebelli, it is found behind the brainstem, it consists of 2 lateral right&left cerebellar hemispheres connected by a midline vermis which has an inferior surface and a superior surface (slides: The surfaces of cerebellum have many parallel folds called folia).

Slides: Arbor vitae means “tree of life” in Latin, it is the white matter of cerebellum, It is so called because of the tree like appearance, It brings sensory and motor sensation to and from cerebellum.

subdivisions of the cerebellum

There are vertical and horizontal subdivisions of the cerebellum, the horizontal subdivision is functionally unimportant.

The Lobes of Cerebellum : (the horizontal subdivision)

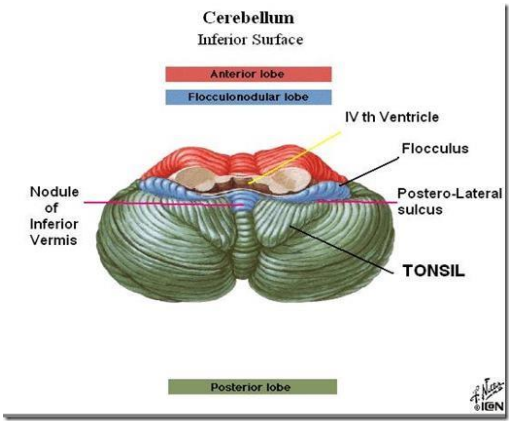

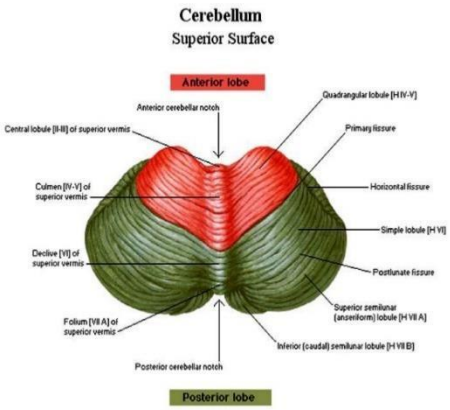

- Anterior lobe (red): in front of the primary fissure.
- Posterior lobe (green): behind the primary fissure, it makes 2/3 of the superior surface of cerebellum, and most of the inferior surface.
- Flocculo-nodular lobe (blue): Consists of the flocculus & paraflocculus nodule, can be seen on the inferior surface.

Lab note: Nodule- is part of the vermis

both anterior surface and posterior surface can be seen from the superior surface, the three lobes can be seen from the **inferior surface.**

The vermis is part of the anterior and posterior lobes on the superior surface, and part of the anterior, posterior, flocculo-nodular lobes on the inferior surface.

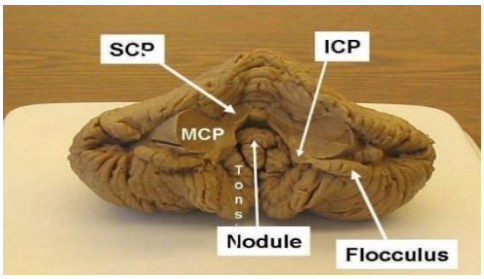

this represents the inferior surface, #anterior notch can be seen here.

****SCP: superior cerebellar peduncle **ICP: inferior cerebellar peduncle (note: peduncles connect cerebellum and different parts of brainstem)**

Lab note: The cerebral peduncles are found between the brainstem and cerebellum, and they are separated from the cerebellum by the cavity of the 4th ventricle, The cut edge of cerebral peduncles appear on the inferior surface of cerebellum, the largest part is the lateral part which represents the middle cerebral peduncles and the small upper part represents the superior cerebral peduncle, the lowermost part represents the inferior cerebral peduncle.

(Slides) cerebellum has 2 surfaces:

1) Superior surface: facing the midbrain & tentorium cerebelli.
2) Inferior surface: divided into anterior & posterior parts

The main fissures of the cerebellum: -

1) Primary fissure: it is found on the superior surface dividing it into anterior one third and posterior two third.
2) Horizontal fissure: it divides the cerebellum into upper and lower parts, #it begins from anterior notch on one side and ends at the anterior notch on the other side.
   (slides: it extends between the middle cerebellar peduncles.)
3) Posterolateral fissure: on the inferior surface, it separates the flocculonodular lobe from the rest of the cerebellum.

(slides) -Cerebellar tonsils: on either side of uvula of inferior vermis, the tonsils lie near the medulla oblongata in foramen magnum,

Retrotonsillar fissure: it separates tonsil from the rest of cerebellum.

Lab note: cerebellar tonsils can herniate from the foramen magnum, when the intracranial pressure increases, which can compress the vital centers in the medulla oblongata, this condition is called herniated cerebellar tonsil.

The cerebellum has 2 notches: -

1) Anterior notch (aka midbrain notch) occupied by the brainstem (# midbrain, the pons, and medulla).
2) Posterior notch (vellecula) occupied by falx cerebelli.

The folded paper on the right is analogues to the cerebellum, unfolding the paper on the other way around, will imaginarily represent an unfolded cerebellum as shown in the diagram on the left, look at anterior lobe, posterior lobe, flocclonodular lobe, vermis and paravermis.

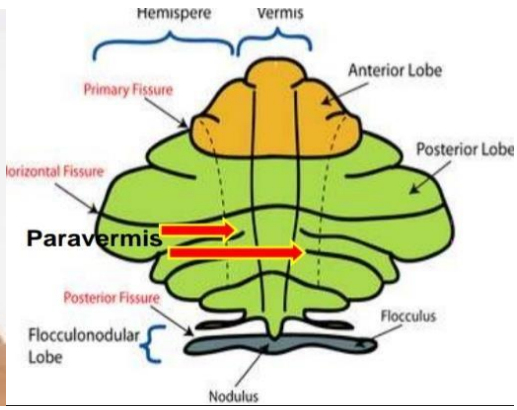

<u>The vertical subdivision:</u>

1- vermis (**central** part on superior and inferior surfaces) represents head, neck, <u>trunk</u>, shoulders and hips). In other words, it represents the central part of body and truncal/ axial muscles, the body is represented on the vermis in an upsidedown fashion, the head down, the trunk is above and so on (it reminds us of the motor area on cerebral cortex). It is connected to **fastigeal** nucleus.

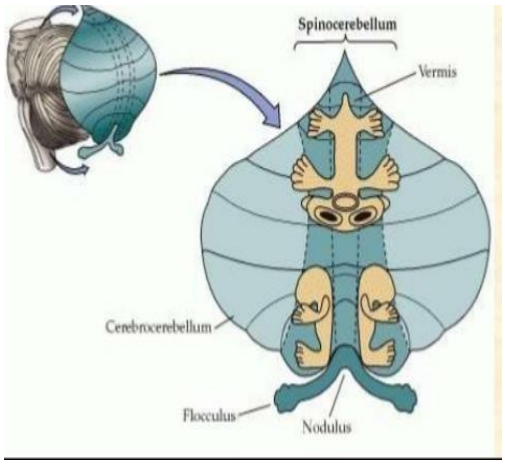

2- Paravermis (lateral to vermis)
represents **muscles** of upper and lower limbs (extra: appendicular muscles), it is connected to **Globose** and **Emboliform** nucleus.

3- Rest of the lateral cerebellar hemispheres connected to **Dentate nucleus**.

Cerebellar deep nuclei

(these remind us of the cerebral basal nuclei), from medial to lateral, the deep nuclei in cerebellum are:

1- **Fastigial** (inside vermis to control central muscles of the body)
2- Interposed nuclei: **Emboliform** - **Globose** (inside paravermis to control limbs)
3- **Dentate** nucleus (inside lateral cerebellar hemispheres to control the remaining parts)

- Mnemonic (from lateral to medial) : "Don't Eat Greasy Food"

The structure of cerebellum the

cerebellum consists of:

1- Cerebellar cortex

This cortex consists of 3 layers, the **middle layer** is the most important layer (this reminds us of the 6 layers of the cerebral cortex, the fifth was the most important), the cerebellar layers are:

a- Outer **Molecular** Layer (stellate and basket cells)
b- Middle **Purkinje Cell Layer** (it is the **most important** layer because it contains inhibitory to all other cells)
c- Inner **Granular** Layer Include 2G cells (granule and golgi) (Granule cells are the only excitatory to all other cells).

2- Corpus Medullare (Medullary Center)
3- Deep cerebellar nuclei.

The white matter (axons) of the cerebellum consists of three types of nerve fibres in the white matter:

1- **Mossy fibres (afferent)** They end in the granular layer first then purkinje layer (indirect activation of pyrkinje).
2- **Climbing fibers (afferent**) They end directly in purkinje (direct activation) or molecular layer (olivocerebellar tracts mainly)
3- **Axons of purkinje cells (efferent)**, it is the **most important** because it is the only efferent, The only axons to leave cerebellar cortex to end in deep cerebellar nuclei (inhibitory). These fibers then projects to brain stem nuclei, thalamus and cerebral cortex.

Note: These afferent and efferent fibres move through peduncles, (superior, middle, inferior peduncles).

Functional Subdivisions of The Human Cerebellum

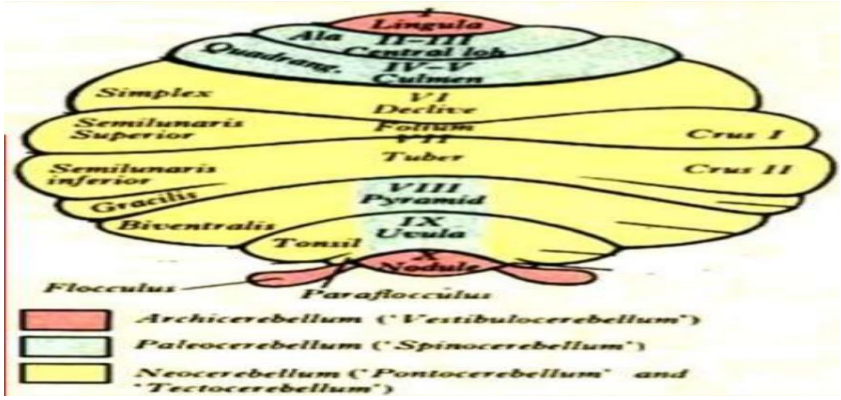

1- Archicerebellum (Vestibulo-cerebellum) "red":

- Flocculo-Nodular Lobe + Lingual Lobule
- Function: Vestibulo-Ocular Reflex (**VOR**) and **Equilibrium**
- Note: the vestibulo-ocular reflex functions to preserve the image on the center of the visual field by producing eye movements in the direction opposite to head movements.
-)it is well developed in fish because they need equilibrium.(2- **Paleocerebellum (Spino-cerebelllum) "blue":**
- Anterior lobe +midline vermis + paravermis
- Function: regulating **muscle tone** of axial and proximal limb muscle, By receiving afferent proprio-ceptive impulses from muscles and tendons via

spino-cerebellar tracts to reach the spino-cerebellar part of the cerebellum, (anterior lobe/ vermis/paravermis).

4-Neocerebellum (cerebro cerebellum) "yellow": represents the rest of cerebellum, It includes the majority of the 2-cerebellar hemispheres + dendate nuclei.

Functions:

a- controls voluntary movements, coordinating and planning of sequence of intended movements (even before execution of motor activity) i.e anticipation

b- Regulation of force and time of Movement

c- **Learning** new complex movements

close your eyes, and try to touch your nose, if you didn't make it, you would probably have a lesion in your cerebro-cerebellar.

The whole pathway: Cortico-ponto-cerebellar-Dentato-rubro-thalamo-corticalspinal

For example, if you want to learn something new , the impulse should travel from the cortex to pons to cerebellum to dentato nucleus to red nucleus of the midbrain to thalamus to the cortex and finally to the spinal cord. (we will take this pathway in detail later in this course)

Cerebellar lesion Syndromes:

-Ataxia: incoordination of movement.

The man most likely has a lesion in his paravermix (because he tries to control his movement with his limbs), but the young girl most likely has a lesion in vermix (because she cannot control her trunk).

A Special Dedication to Danah Hweiti :P

"Sometimes, it falls upon a generation to be great. YOU can be that great generation, let your greatness blossom."