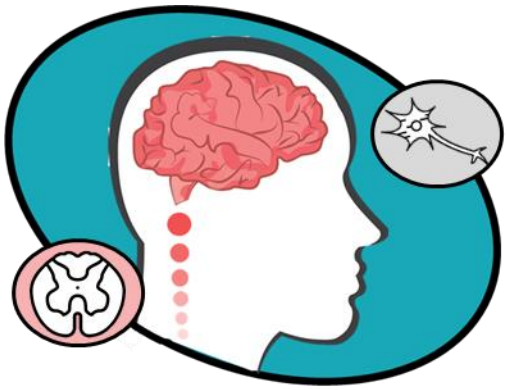

CNS

Anatomy

Sheet Slide

Number

Done by:

- Mohammad Abed

Corrected by:

- Rama Nada

Doctor:

-

Pain control in the central nervous system

1-Gating Theory (discussed in the previous lecture)

2-Descending control of pain
it's a type of **negative feedback mechanism**
It's considered the CNS analgesic system to reduce pain.
it's made of two systems

1) The **spinoreticular fibers** (while they're ascending) activate certain areas named **periaqueductal gray** (collection of neurons around the cerebral aqueduct)
2) periaqueductal gray activates **Nucleus Raphe Magnus** in medulla oblongata through excitatory descending fibers
3) Nucleus Raphe Magnus neurons release serotonin. Serotonin activates inhibitory interneurons in **Substantia Gelatinosa** (in the dorsal horn) that secrete endorphins and enkephalins.
4) endorphins and enkephalins inhibit the pain pathway while it is ascending in the area where the first order neurons synapse with the second order neurons (in substantia gelatinosa), this area is the site of pain modulation
   Note: substantia gelatinosa is an area in the dorsal horn mainly lamina 2 and inner layer of lamina 1; endorphins and enkephalins are both morphine like (endogenous ligands for opioid receptors).

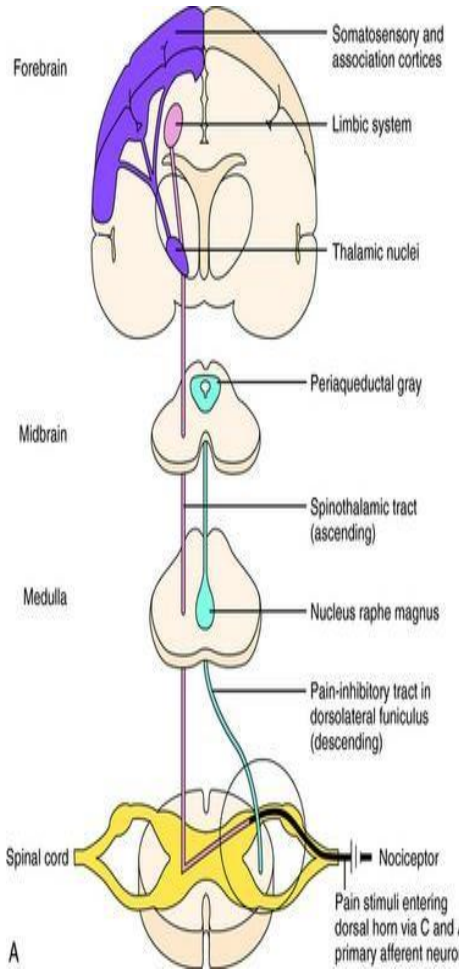

3-Locus Coeruleus is a nucleus in pons, it receives excitatory fibers from the ascending pain pathway and give directly a descending inhibits neurons to substantia gelatinosa (pain modulation area).

Anterior spinothalamic tract

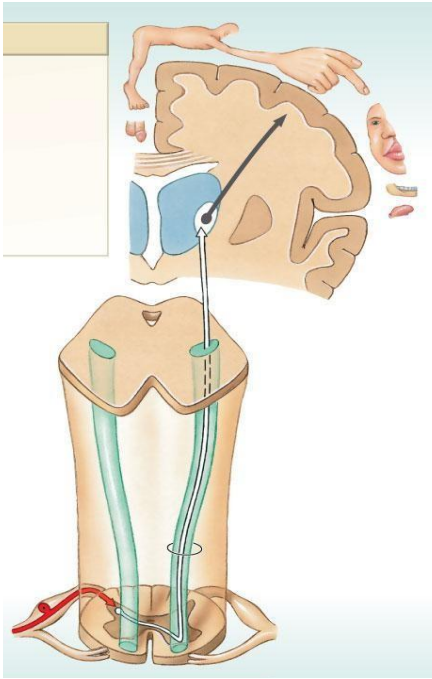

- **Modality**: crude touch and pressure
- **Receptors**: free nerve endings
- **1st Neuron**: cell body in Dorsal root ganglia
- **2nd Neuron**: cell body in the posterior gray column (substantia gelatinosa/dorsal horn) The axons of 2nd order neurons cross obliquely to the opposite side in the anterior gray and white commissures (anterior to the central canal of spinal cord), ascending in the contralateral white column as the Anterior spinothalamic tract
- **3rd Neuron**: cell body in Thalamus (VPL) and these project to the cortex through Internal Capsule
this projection is called Corona Radiata
- **Termination**: Primary Somatic Area (S I)

Spinotectal Tract

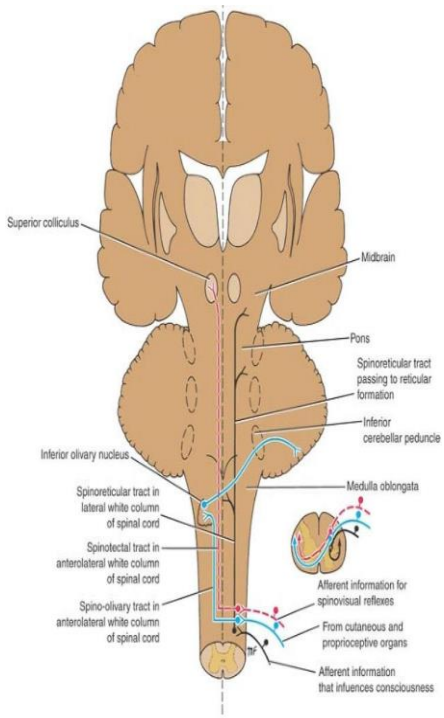

- it's a **crossed** tract
- tectum is the posterior aspect of midbrain which contains both superior and inferior colliculus (thus called corpora quadrigemina). Superior colliculus controls visual reflexes.
- It ascends in the anterolateral white column lying close to the lateral spinothalamic tract
- Terminate: superior colliculus
- It provides afferent information for spinovisual reflexes

note about reflexes :1) has an afferent limb (spine the sensation) and an efferent limb (motor of neck and eyes)
Each reflex composed of two main components: afferent limb and efferent limb, for the spinovisual reflex: the afferent limb is spinal (spinotectal tract) and the efferent limb is motor to bring the head and neck to the site of injury.

In Medulla: ant spinothalamic tract + lateral spinothalamic + spinotectal will create the **spinal leminiscus**

Spinocerebellar tract

made of: -

1-posterior spinocerebellar (Dorsal)	2-anterior spinocerebellar (Ventral)
• modality: unconscious muscle and joint proprio sensation (unconscious proprioception) • Receptors: most types of receptors except free nerve endings • 1st order neuron cell body in dorsal root ganglia and axons terminate at the base of dorsal horn in nucleus dorsalis (or Clarks nucleus) which is in lamina 7 and 6 • the axons of 2nd order neurons enter **posterolateral part of the <u>lateral white matter</u>** on the same side (ipsilaterally) • ascend as the posterior spinocerebellar tract to medulla oblongata •Terminates in cerebellar cortex (through inferior cerebellar peduncle) **Note**: axons of lower lumbar and sacral spinal nerves ascend in the posterior white column until they reach L3 or L4 segments where they synapse with nucleus dorsalis	• modality: unconscious muscle and joint sensation (unconscious proprioception) • Receptors: most types of receptors except free nerve endings • 1st order neuron cell body in dorsal root ganglia and axons terminate at the base of dorsal horn in nucleus dorsalis/Clarks ➢ the **<u>majority</u>** of axons of 2nd order neurons cross to opposite side and ascend as anterior spinocerebellar tract in the contralateral white column, these fibers that **crossed** over in spinal cord will cross back within cerebellum parenchyma and enters through middle cerebellar peduncle (double crossing). ➢ the **<u>minority</u>** of axons ascend as anterior spinocerebellar tract in the lateral white column of the same side • ascend as anterior spinocerebellar tract to medulla oblongata and pons •Terminates in cerebellar cortex through superior cerebellar peduncle

<u>Rule</u>: cerebellum rt hemisphere receives afferent from the rt side of the body and left hemisphere receives afferent from the left side of the body, unlike the sensation.

Note: these are mossy fibers (in the cerebellum).

Note: The cerebellum receives fibers from the spinal cord but doesn't give fibers to it.

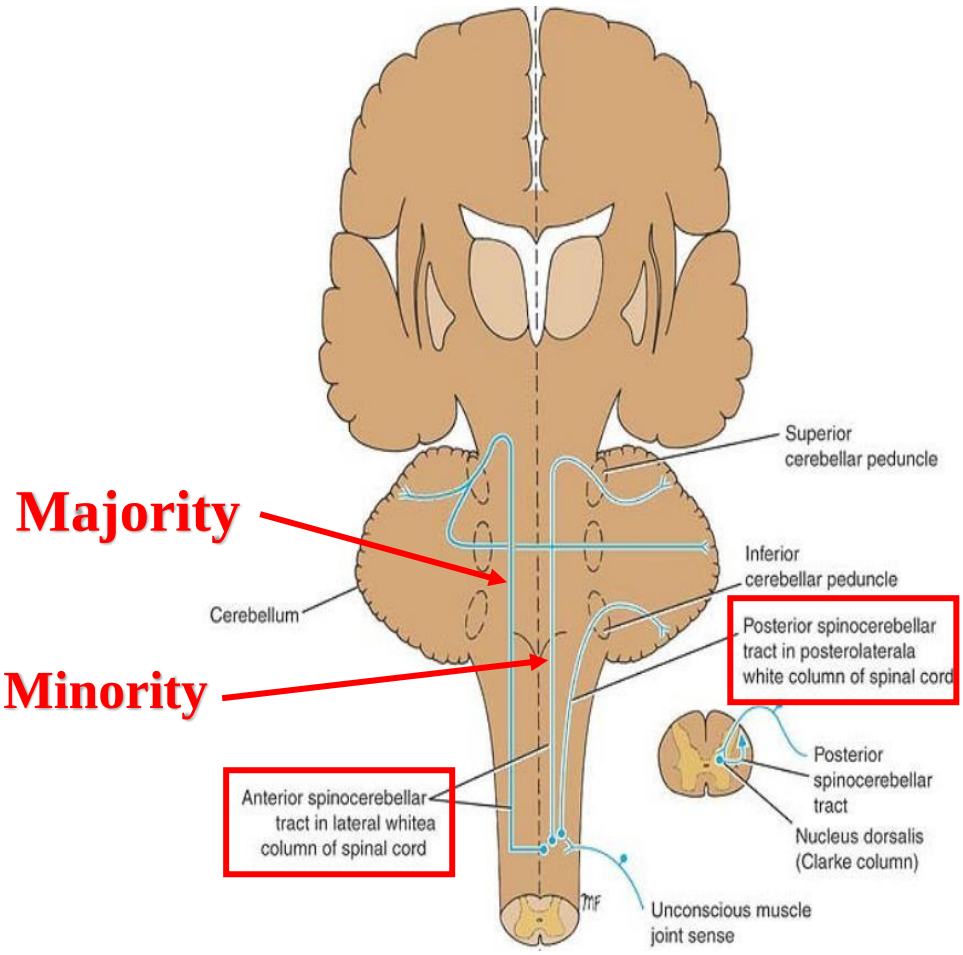

Rexed laminae

- **Lamina 1** relay information related to pain and temperature
- **Lamina 2:** relay information related to pain and temperature **(pain modulation)**
- **Lamina 3 and 4:** nucleus proprius; these laminae have many interneurons

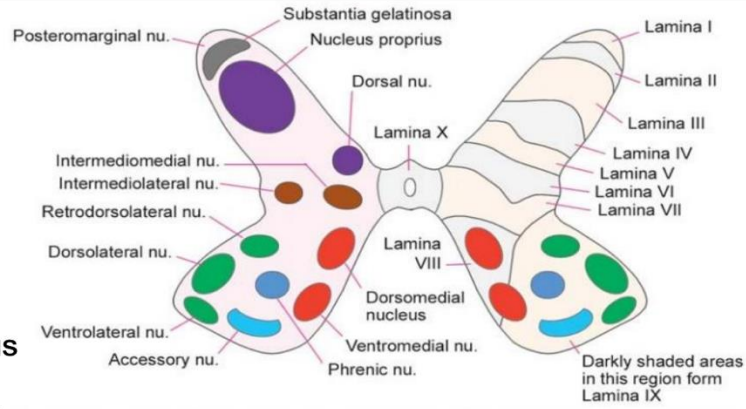

Fig. 5.2. Subdivisions of the grey matter of the spinal cord. The left half of the figure shows the cell groups usually described. The right half shows the newer concept of laminae.

- **Lamina 5:** relay information related to pain and temperature
- **Lamina 6:** presents only at the cervical and lumbar enlargements and receives proprioception
- **Lamina 7: Intermedio-lateral** nucleus, contains preganglionic fibers of sympathetic (T1 -L2). **Intermedio-medial nucleus** ,all over the spinal cord, receive visceral pain. **Dorsal nucleus of Clark's** presents at (C8 – L2 or T1- L4) , relay center for **unconscious proprioception**

The following topics will be a quick revision for the eLearning lecture, when the doctor starts with new information I will remined you.

Motor tracts (descending tract)

Note: descending tracts come not only from the primary motor area and premotor, but some even come from the primary sensory area
They descend to the anterior horn and synapse usually with an interneuron in lamina 8, then the interneurons will synapse with lower motor neuron in lamina 9 (where the cell bodies of the lower motor neurons are located).
There are two major descending tracts

➢ **Pyramidal tracts** (Corticospinal): Conscious control of skeletal muscles, final executional movement.
Descends from primary motor area (area 4)
named so because it passes in the anterior aspect of medulla

➢ **Extrapyramidal**: **Subconscious** regulation/coordination of balance, muscle tone, eye, hand, and upper limb position:

❖ Vestibulospinal tracts
❖ Reticulospinal tracts
❖ Rubrospinal tracts
❖ Tectospinal tracts Motor tracts

Structures in midbrain

Note: Extrapyramidal tracts arise in the brainstem but are under the influence of the cerebral cortex
Subconscious control of skeletal muscle not smooth muscle!!
Extrapyramidal are mainly from the premotor (area 6) and supplementary (SMA).

Muscle spindles

are sensory receptors within the belly of a muscle that primarily detect changes in the length of this muscle.
Each muscle spindle consists of an encapsulated cluster of small striated muscle fibers ("intrafusal muscle fibers") with somewhat unusual structure (e.g., nuclei may be concentrated in a cluster near the middle of the fiber's length).

❑The skeletal muscle is composed of:

➢Extrafusal fibers (**99%):** innervated by alpha motor neurons.

➢Intrafusal fibers (**1%):** innervated by gamma motor neurons. depend on the muscle spindle receptors responsible for <u>stretch reflex;</u> where when the muscle is stretched nerve fibers fire and activate a lower motor neuron going to the same muscle which causes it to contract.

Intrafusal fibers are supplied by gamma motor neurons **<u>to maintain muscle tone.</u>**

The anterior corticospinal tract

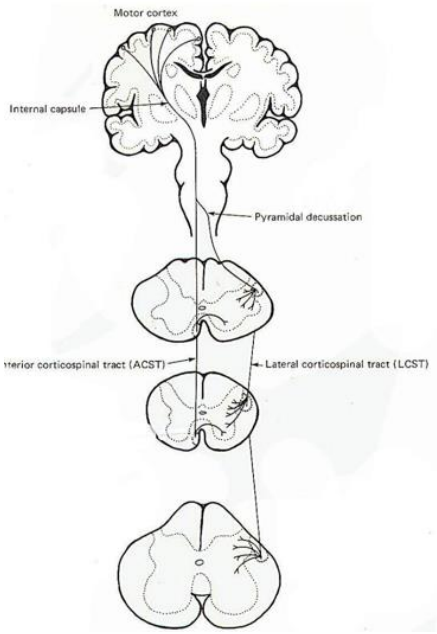

It starts in the cortex and descend through the internal capsule and in lower part of medulla 85% of fibers cross to the contralateral side and 15% continue on the ipsilateral side.
The site of fiber crossing is called pyramidal decussation/primary motor decussation
These fibers (crossed 85%) continue down until the anterior horn of spinal cord.
Uncrossed fibers (15%) eventually cross at the level of spinal cord and reach the anterior horn of the contralateral side.
Lamina 8 contains interneuron and receives upper motor neuron
Lamina 9 contains the cell body of the lower motor neuron and is divided into medial and lateral, the lateral area controls the lateral muscles (limbs muscles) through the lateral corticospinal tract, and the medial area controls axial muscles (medial muscles) through the anterior corticospinal tract
So, the anterior corticospinal tract supplies the medial area of lamina 9 which is axial muscles.

Lateral corticospinal tract

lateral corticospinal tract supplies the lateral area of lamina 9 which is lateral muscles.
Lateral corticospinal tract descends the full length of the spinal cord

- ➢ LCST fibers synapse with alpha and gamma nuclei of the
  - ➢ Cervical region (55%) (great effect on the upper limb); ends in the cervical segments.
  - ➢ Thoracic 20%; ends in the thoracic segments.
  - ➢ Lumbar and Sacral 25%
- ➢ The lateral corticospinal tract synapses mainly by interneurons in lamina IV, V, VI, VII, VIII
- ➢ Exception: 3% originate from the fifth layer of area 4 (giant cells of betz) synapse directly without the use of interneurons (these are for Accurate movements).

The Corticoneuclear Tract (fibers)

There is no anterior and posterior horn; anatomically it's not pyramidal since it doesn't pass through the medulla pyramid but functionally its pyramidal and its function is very important, so it is considered pyramidal.

➢ This tract is composed of fibers originating in the precentral gyrus of the lower quarter of the motor cortex (area 4).

➢The descending fibers terminate in the motor nuclei of cranial nerves III and IV in the midbrain; V, VI. and VII in the pons; and IX, X, XI, and XII in the medulla.

➢ The corticobulbar fibers from one side of the brain project to the motor nuclei on both sides of the brainstem (bilateral input)

The corticoneuclear input is bilateral Except:

1- Part of 7th (which supplies LOWER facial muscles)
2- Part of 12th (which supplies genioglossus muscle)

The Subconscious Motor Tracts (Extrapyramidal tract)

Consists of four tracts involved in monitoring the subconscious motor control

•Vestibulospinal tracts
•Tectospinal tracts
•Reticulospinal tracts
•Rubrospinal tracts

These motor pathways are complex and multi-synaptic, and regulate:

• Axial muscles that maintain balance and posture
• Muscles controlling coarse movements of the proximal portions of limbs
• Head, neck, and eye movement

Rubrospinal tract

• Red nucleus
– In the midbrain at the level of superior colliculus
– Receives afferent fibers from cerebral cortex and the cerebellum (globose-emboliform rubral pathway)
• Crossed (at the level of the nucleus, very early crossing that's why when we take a section in midbrain, we can see both the red nucleus and the crossing fibers).
•descends in the Lateral white column
• Function: facilitate the activity of the flexors, especially the distal flexors and the upper limb and inhibit the activity of extensors

It has close relation to the lateral corticospinal tract that we said controls lateral muscles.
So **Rubrospinal tract + lateral corticospinal tract = lateral motor system**
Now, we will start the new lecture:

Reticulospinal tract

Reticular system is the conscious part imbedded in the brain stem, mainly in the medulla oblongata, so the reticulospinal tract is divided according to the site of origin into: Pontine reticulospinal (from the pons) & Medullary reticulospinal (from the medulla oblongata).

Pontine reticulospinal tract/medial reticulospinal;

• From pons:
• axons of RF (reticular formation) neurons descend uncrossed into the spinal cord (This tract is uncrossed so Rt. stays Rt. and left stays left).
• descends in the Anterior white column
• **tonically active**, the cortex is acts to inhibit this system not full inhibition however it reduces its action so if we were to cut the cortex control on this tract (disinhibition), the pontine reticulospinal tract will tend to over shoot
• normally under inhibition from cortex
•Function:

- activate the axial and proximal limb extensors (Antigravity muscles)
- inhibit the flexors

Medullary reticulospinal tracts/ Lateral reticulospinal tract;

• From medulla
• axons of RF neurons descend crossed and uncrossed into the spinal cord
• descend in the **<u>Lateral white column</u>**
• NOT tonically active
• normally under stimulation, the cortex control here is very minimal and in general it doesn't affect it.
• Function: Inhibit the axial and proximal limb extensors
Note: it is considered an antagonist to the pontine.
<u>Note:</u> the lateral horns in the spinal cord (which have the cell bodies of the preganglionic fibers) receive fibers from higher center, which is the hypothalamus (the big boss of the ANS), these fibers while they are descending from the hypothalamus to the lateral horn pass through the medullary reticulospinal fibers, pay attention that these fibers are not part from the medullary reticulospinal fibers but they only pass through them.

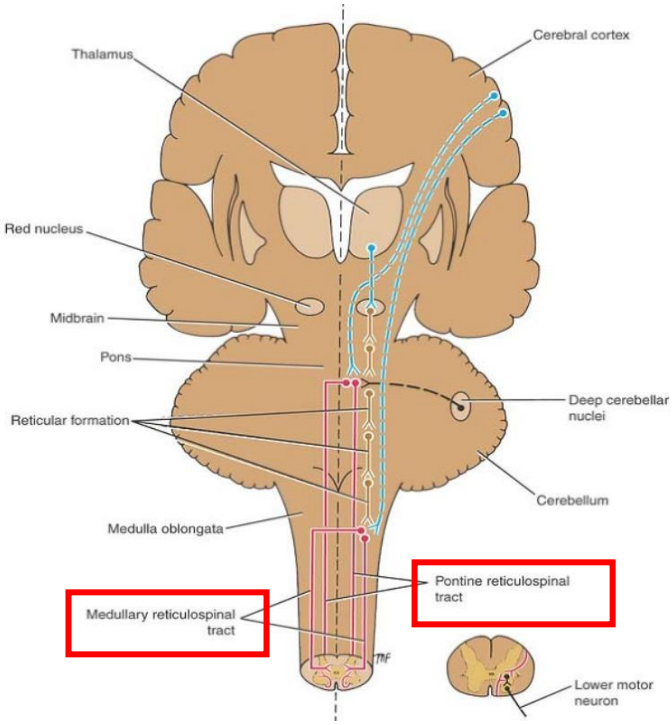

Vestibulospinal Tract

• Vestibular nuclear complex (more than one nucleus) – in the lower pons and upper medulla beneath the floor of 4th ventricle (pontomedullary junction).

– Receives afferent fibers from the inner ear through the vestibular nerve (which detect your relation with the gravity) and from the cerebellum.

• Uncrossed

• descends in the Anterior white column

• Function: facilitate the activity of extensor muscles (antigravity muscles) and inhibit the activity of flexor muscles in association with the maintenance of balance.

Note: it is similar to the pontin reticular tract, but not tonically active as the pontine.

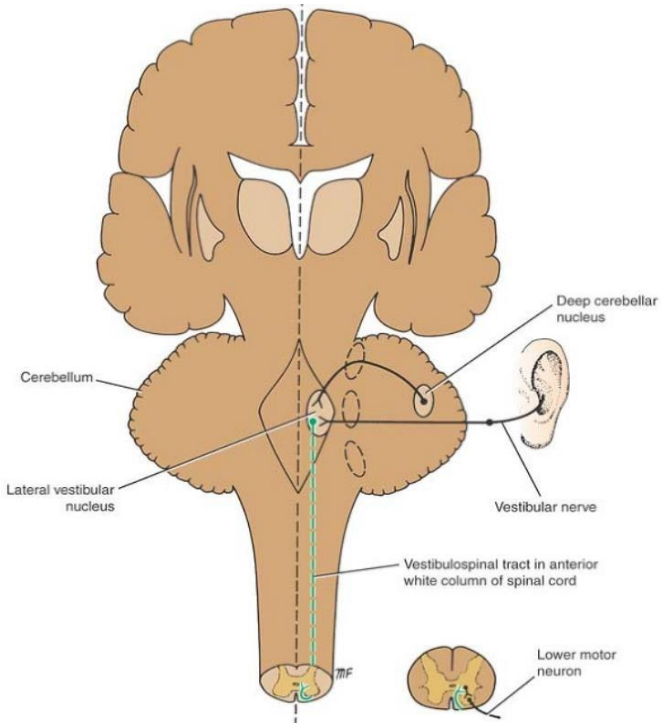

Tectospinal tract

This is the efferent limb of visual spinal reflex (the motor limb)

- Arise from the nerve cells in superior colliculus of the midbrain
- They are Crossed
- The tract descends in the anterior white column close to Anterior median fissure
- Majority of fibers terminate in the anterior gray column of upper cervical segments of spinal cord (responsible for reflex movement of head & neck in response to visual stimuli)

Conclusion

The motor pathways are classified into

❑ **Medial Motor system**: axial & proximal muscles. Medial Motor system include:

➢ Anterior corticospinal tract.

➢ Extrapyramidal pathway in general

❑ **Lateral Motor system**: distal muscles mainly, lateral Motor system include

➢ lateral corticospinal tract

➢ Rubrospinal tract distal muscles mainly (and proximal).

COMPARISON BETWEEN UMN AND LMN

Features	Upper motor neuron lesions(UMN)	Lower motor neuron lesion(LMN)
	UMN starts from motor cortex to the cranial nerve nuclei in brain and anterior horn cells in spinal cord	LMN is the motor pathway from anterior horn cell(or Cranial nerve nucleus)via peripheral nerve to the motor end plate
Bulk of muscles	No wasting	Wasting of the affected muscles (atrophy)
Tone of muscles	Tone increases (Hypertonia)	Tone decreases (Hypotonia)
Power of muscles	Paralysis affects movements of group of muscles Spastic/ clasp knife	Individual muscles is paralyzed Flaccid (flaccid paralysis)
Reflexes	Exaggerated. (Hyperreflexia)	diminished or absent. (Hyporeflexia)
Fasciculation	Absent	Present
Babinski sign	Present	Absent
clasp-knife reaction	Present	Absent
Clonus	Present	Absent

hypertonia and hyperreflexia, is the result of an increase in gamma motor neurons activity

	Posterior White Column-Medial Lemniscal Pathway	**lateral spinothalamic tract**	**Anterior spinothalamic tract**	**Spinotectal Tract**	**Posterior spinocerebellar**	**Anterior spinocerebellar tract**
Modality	Discriminative Touch Sensation (include Vibration) and Conscious Proprioception	pain and temperature	crude touch and pressure	Provides afferent information for spinovisual reflexes	muscle and joint sensation (Unconscious Proprioception)	muscle and joint sensation (Unconscious Proprioception)
Receptor	Most receptors except free nerve endings	free nerve endings	free nerve endings		Most receptors except free nerve endings	Most receptors except free nerve endings
1st Neuron	Dorsal Root Ganglion	Dorsal root ganglia	Dorsal root ganglia	Dorsal root ganglia	1st order neuron axons terminate at the base of post gray column (nucleus dorsalis or Clarks nucleus)	1st order neuron axons terminate at the base of post gray column (nucleus dorsalis)
2nd Neuron	Dorsal Column Nuclei (Nucleus Gracilis and Cuneatus)	the posterior gray column (substantia gelatinosa)	the posterior gray column (substantia gelatinosa)	In the posterior gray column and ascend in the anterolateral white column lying close to the lateral spinothalamic tract	the axons of 2nd order neurons enter posterolateral part of the lateral white matter on the same side and ascend as the posterior spinocerebellar tract to medulla oblongata	➢ the majority of axons of 2nd order neurons cross to opposite side and ascend as anterior spinocerebellar tract in the contralateral white column ➢ the minority of axons ascend as anterior spinocerebellar tract in the lateral white column of the same side ascend as anterior spinocerebellar tract to medulla oblongata and pons
3rd Neuron	Thalamus (VPL)	Thalamus (VPL)	Thalamus (VPL)			
Termination	Primary Somesthetic Area (S I)	Primary Somesthetic Area (S I) and Widespread Cortical Region (Reticular formation, Cingulate and insular gyrus)	Primary Somesthetic Area (S I)	superior colliculus (Tectum)	cerebellar cortex (through inferior cerebellar peduncle)	cerebellar cortex (through superior and middle cerebellar peduncles)