Physiology of the sensory system

Sensations receptors

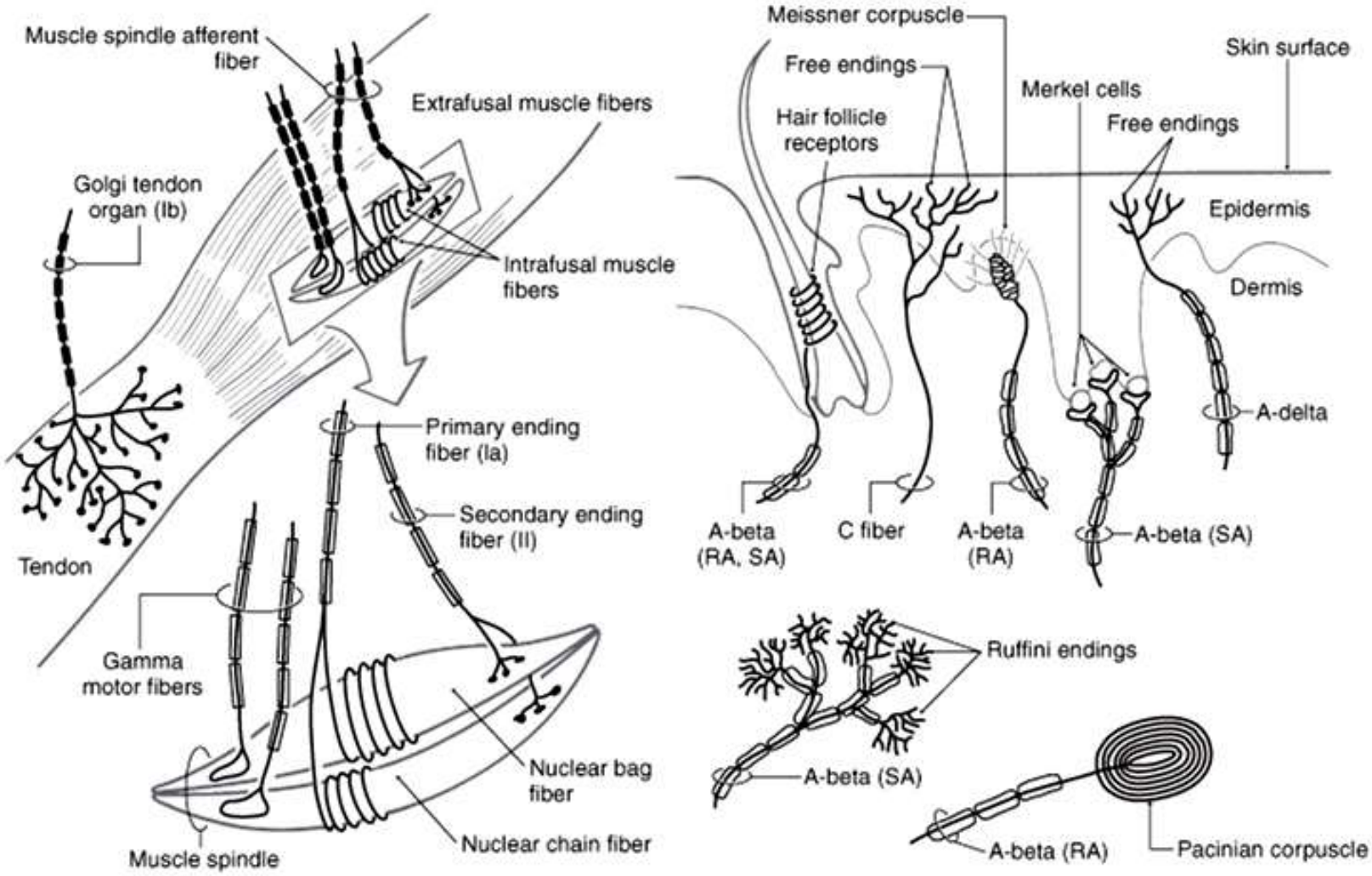

Two-point discrimination

- **Number receptors / area**

(receptive field of the receptor)

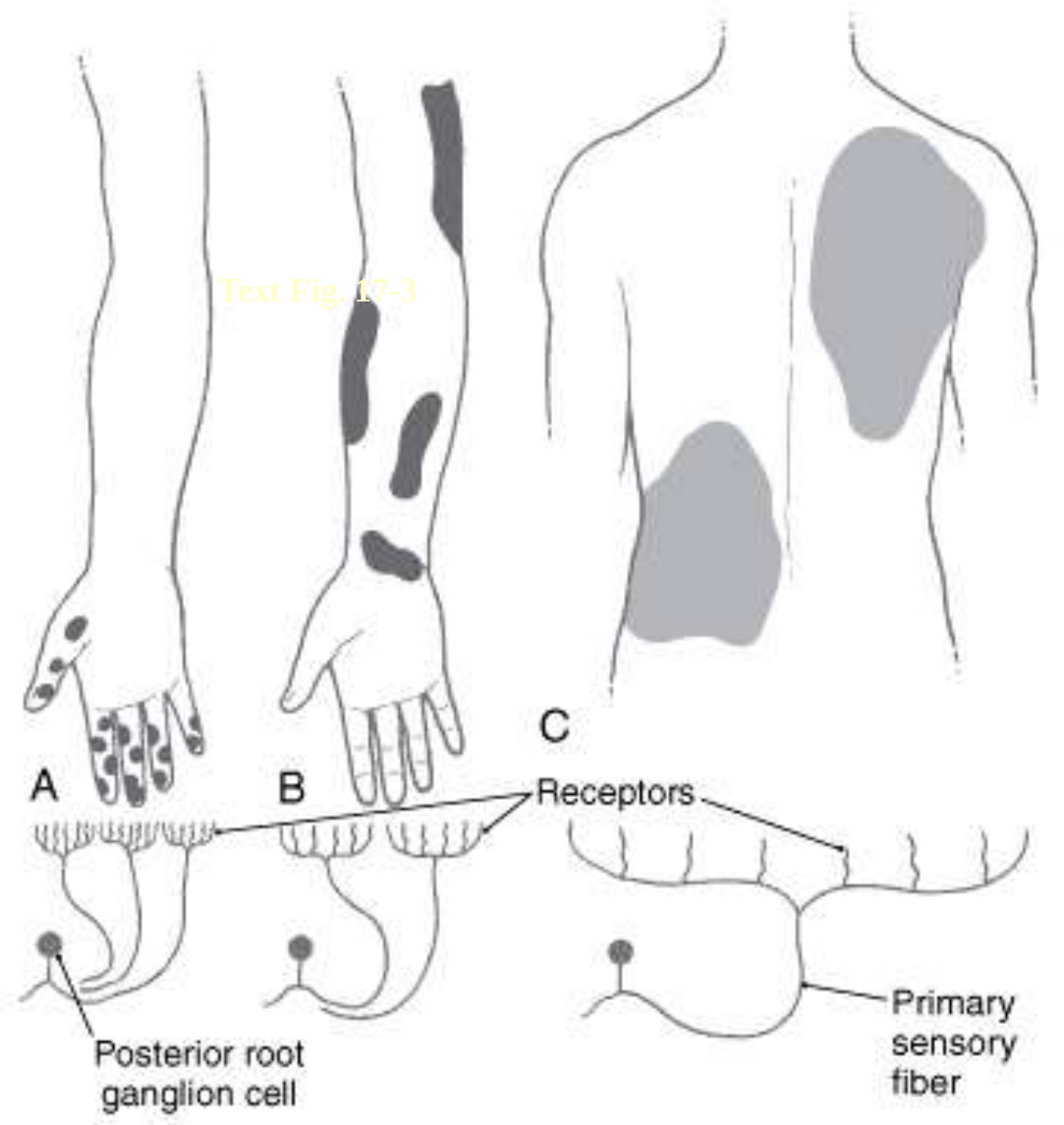

Smaller the receptive fields, greater the density of receptors.
This relationship allows for greater discrimination in sensory inputs.

Two-point discrimination

- **Number receptors / area**
- **Pathway arrangement**

Sensations modalities

Fast

- 2-point discrimination
- Vibration
- Prorioception

Posterior Column-Medial lemniscus Pathway (PCML)

Slow

- Crud touch (itch & rub)
- Temperature
- Pain

Sensations modalities

Fast

- 2-point discrimination
- Vibration
- Prorioception

Slow

- Temperature
- Crud touch (itch & rub)
- Pain

Antero-lateral system (ALS)
Other name: Spinothalamic pathway

Posterior Column-Medial lemniscus Pathway (PCML)

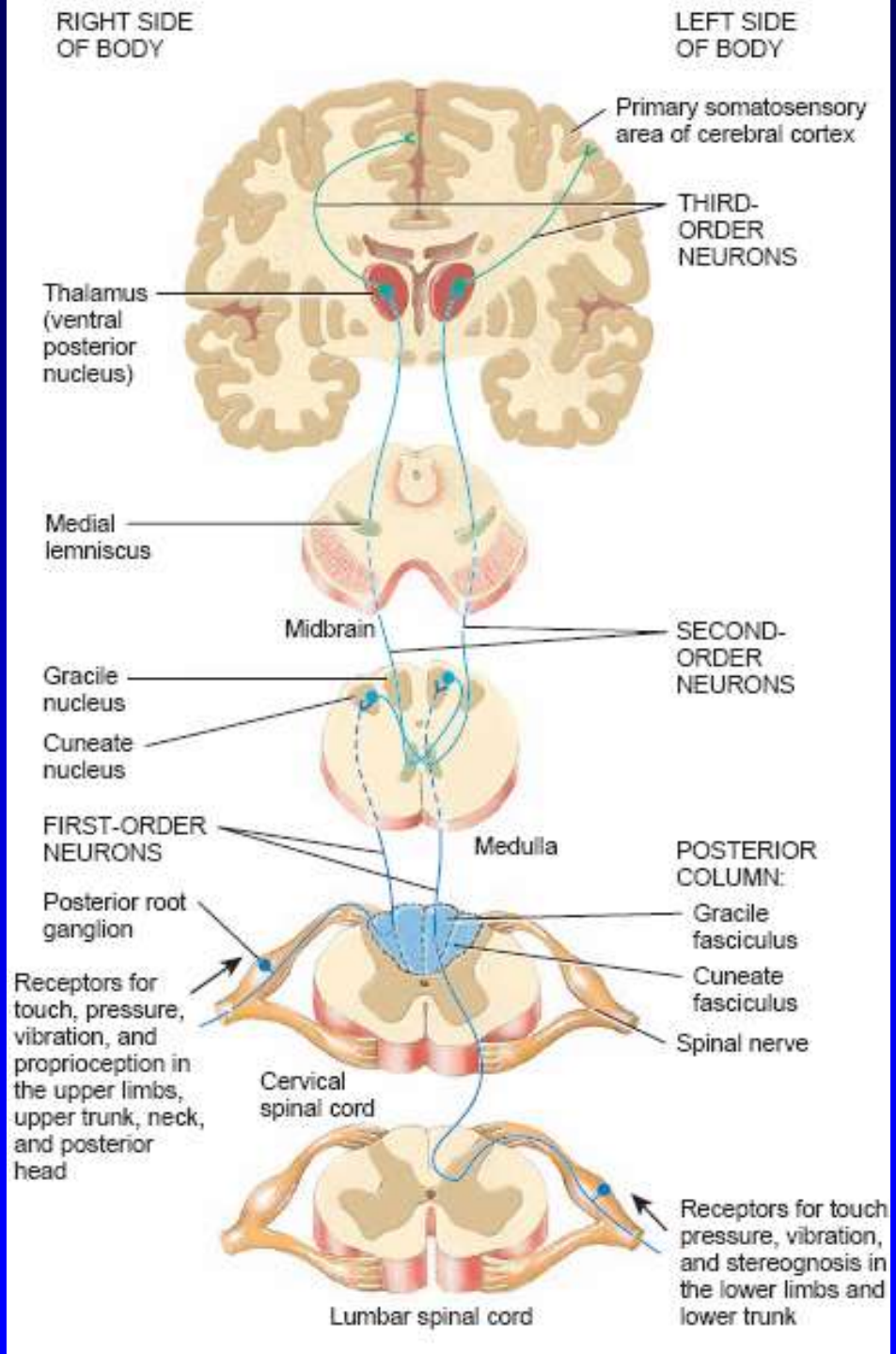
RIGHT SIDE OF BODY
LEFT SIDE OF BODY
Primary somatosensory area of cerebral cortex
THIRD-ORDER NEURONS
Thalamus (ventral posterior nucleus)
Medial lemniscus
Midbrain
SECOND-ORDER NEURONS
Gracile nucleus
Cuneate nucleus
FIRST-ORDER NEURONS
Medulla
POSTERIOR COLUMN:
Posterior root ganglion
Gracile fasciculus
Cuneate fasciculus
Receptors for touch, pressure, vibration, and proprioception in the upper limbs, upper trunk, neck, and posterior head
Spinal nerve
Cervical spinal cord
Receptors for touch pressure, vibration, and stereognosis in the lower limbs and lower trunk
Lumbar spinal cord

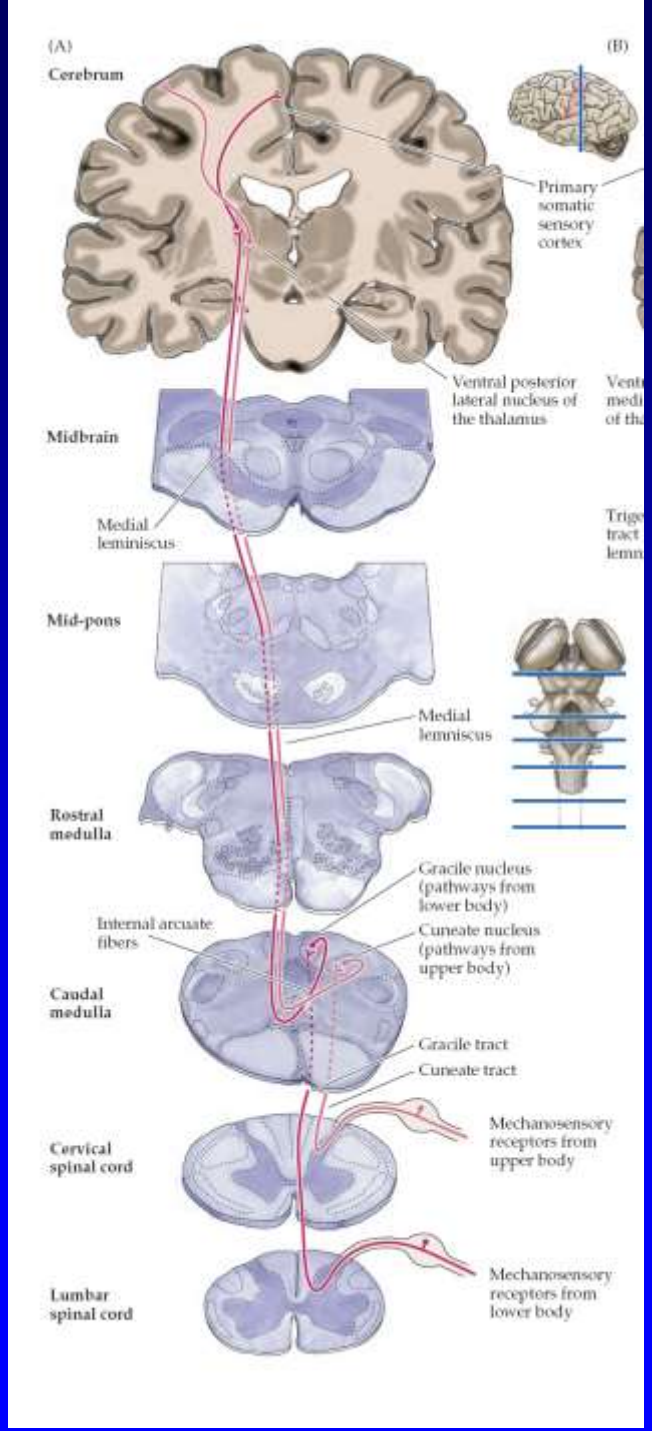
(A)
(B)
Cerebrum
Primary somatic sensory cortex
Ventral posterior lateral nucleus of the thalamus
Midbrain
Medial leminiscus
Mid-pons
Medial lemniscus
Rostral medulla
Gracile nucleus (pathways from lower body)
Cuneate nucleus (pathways from upper body)
Internal arcuate fibers
Caudal medulla
Gracile tract
Cuneate tract
Cervical spinal cord
Mechanosensory receptors from upper body
Lumbar spinal cord
Mechanosensory receptors from lower body

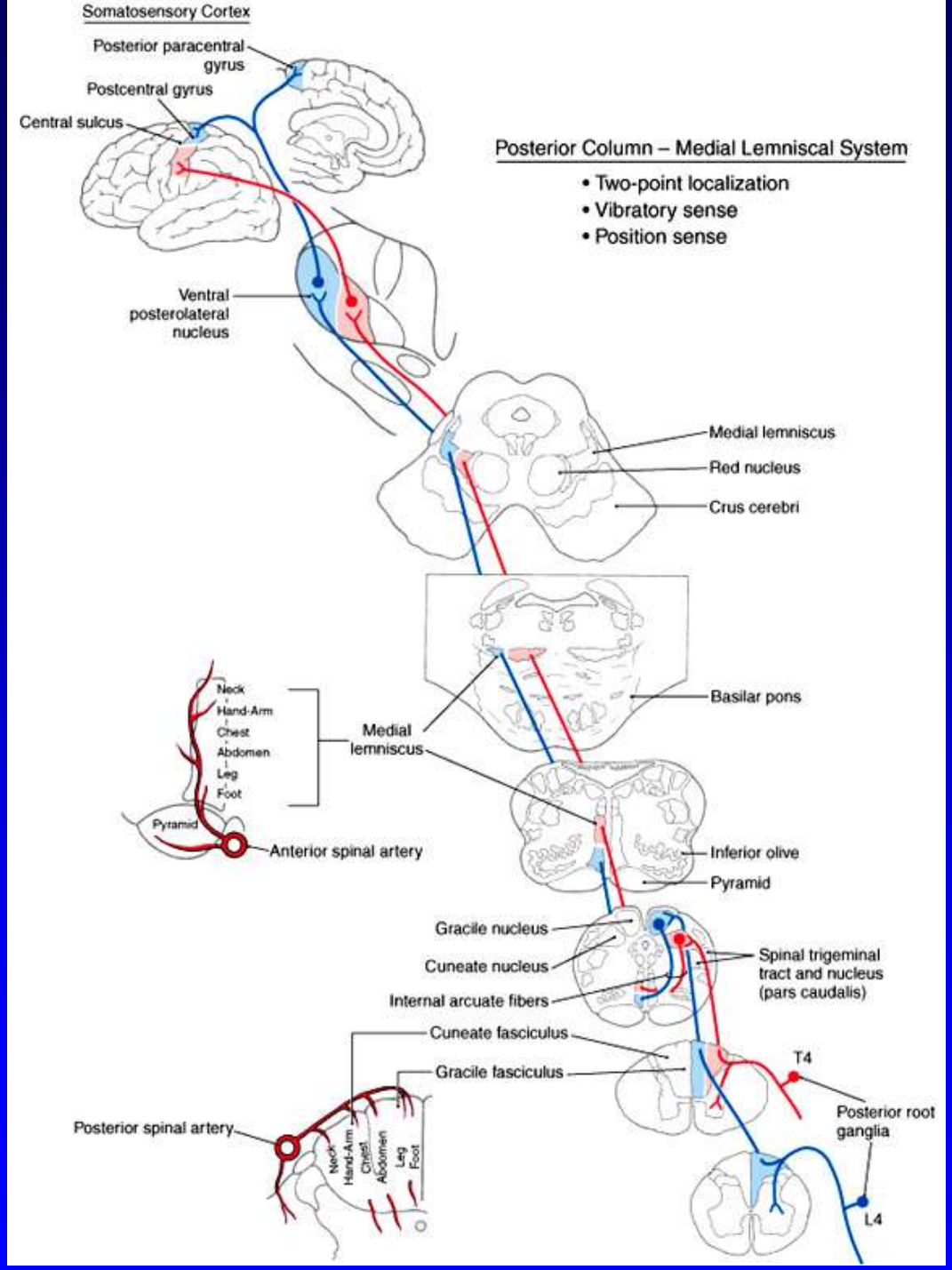
Somatosensory Cortex
Posterior paracentral gyrus
Postcentral gyrus
Central sulcus
Posterior Column – Medial Lemniscal System
• Two-point localization
• Vibratory sense
• Position sense
Ventral posterolateral nucleus
Medial lemniscus
Red nucleus
Crus cerebri
Basilar pons
Neck
Hand-Arm
Chest
Abdomen
Leg
Foot
Pyramid
Medial lemniscus
Anterior spinal artery
Inferior olive
Pyramid
Gracile nucleus
Cuneate nucleus
Internal arcuate fibers
Spinal trigeminal tract and nucleus (pars caudalis)
Cuneate fasciculus
Gracile fasciculus
T4
Posterior root ganglia
Posterior spinal artery
L4

Somatotopic organization of (PCML)

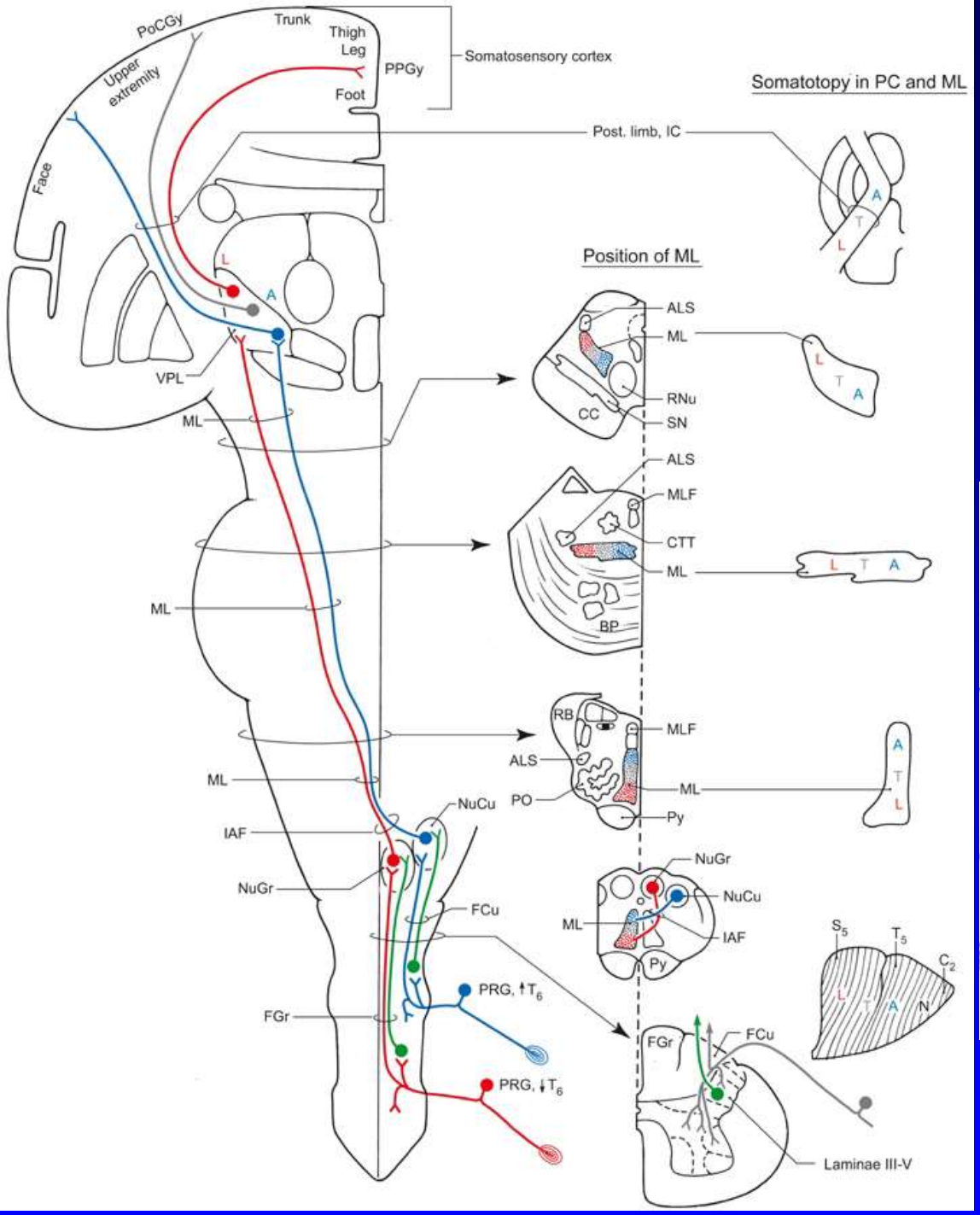
PoCGy
Trunk
Thigh
Leg
Foot
PPGy
Upper extremity
Face
Somatosensory cortex
Somatotopy in PC and ML
Post. limb, IC
Position of ML
VPL
ML
ALS
RNu
SN
CC
MLF
CTT
BP
RB
PO
Py
NuCu
IAF
NuGr
FCu
FGr
PRG, ↑T6
PRG, ↓T6
Laminae III-V
S5
T5
C2
L
T
A
N

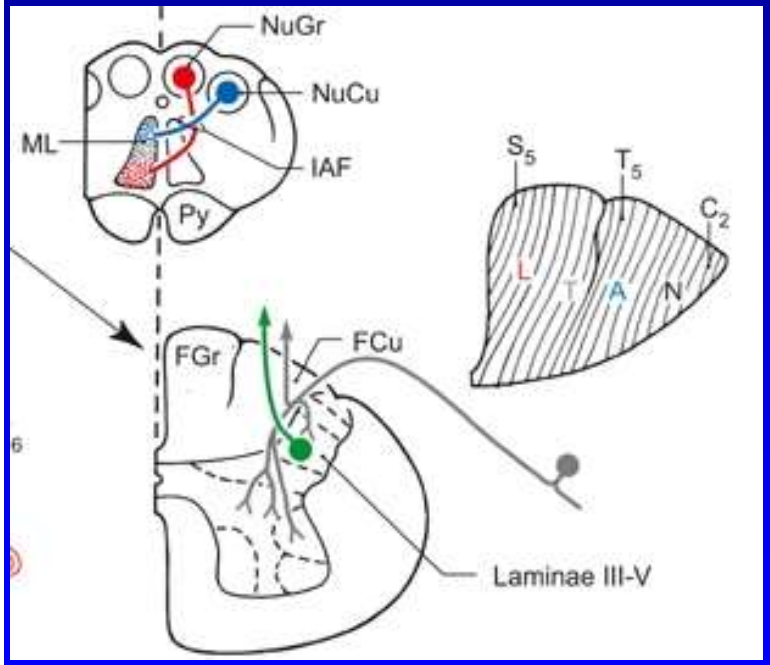
NuGr
NuCu
ML
IAF
Py
FGr
FCu
Laminae III-V
S5
T5
C2
L
T
A
N

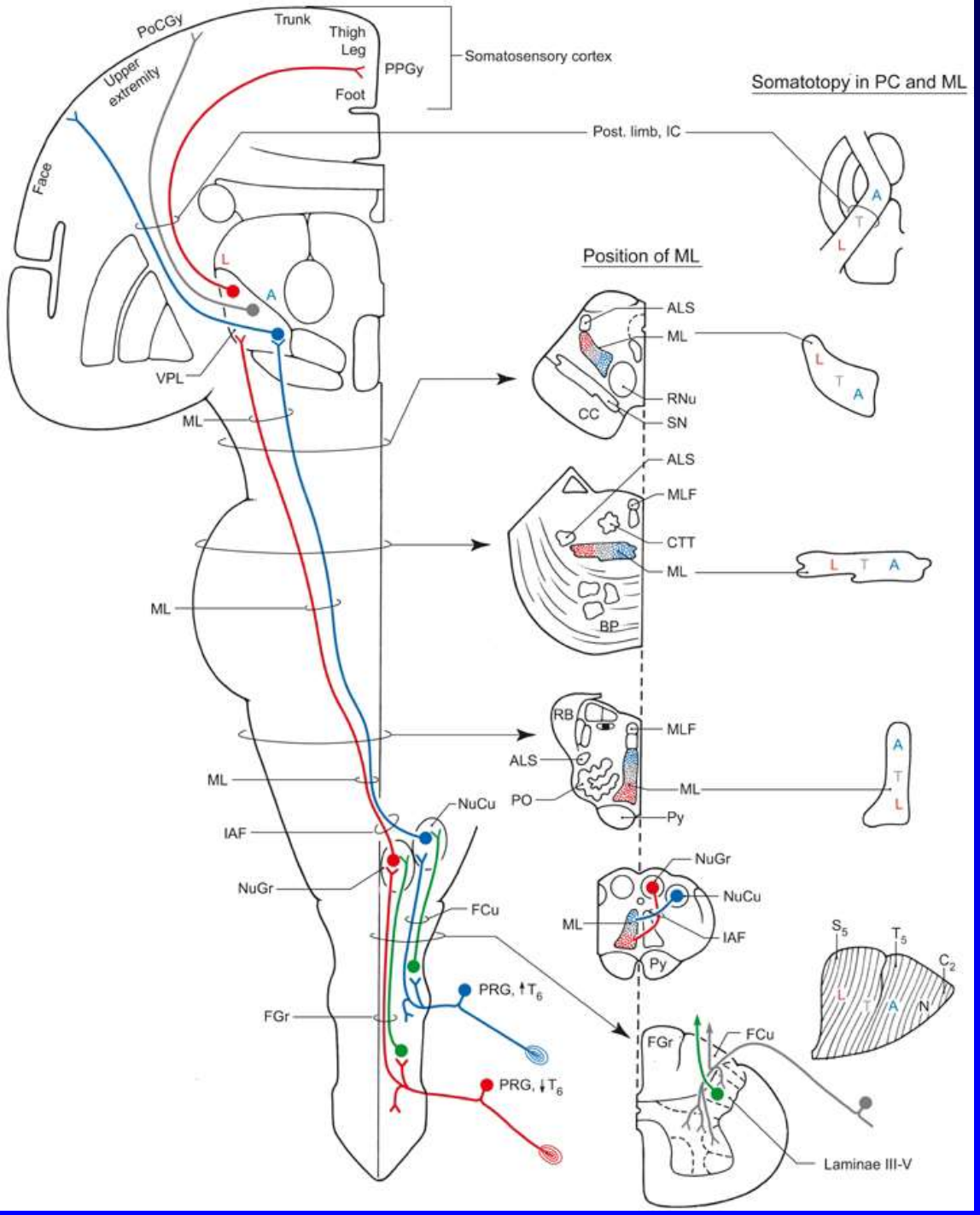
PoCGy
Trunk
Thigh
Leg
Foot
PPGy
Upper extremity
Face
Somatosensory cortex
Somatotopy in PC and ML
Post. limb, IC
Position of ML
VPL
ML
ALS
RNu
SN
CC
MLF
CTT
BP
RB
PO
Py
NuCu
IAF
NuGr
FCu
FGr
PRG, ↑T6
PRG, ↓T6
Laminae III-V
S5
T5
C2
L
T
A
N

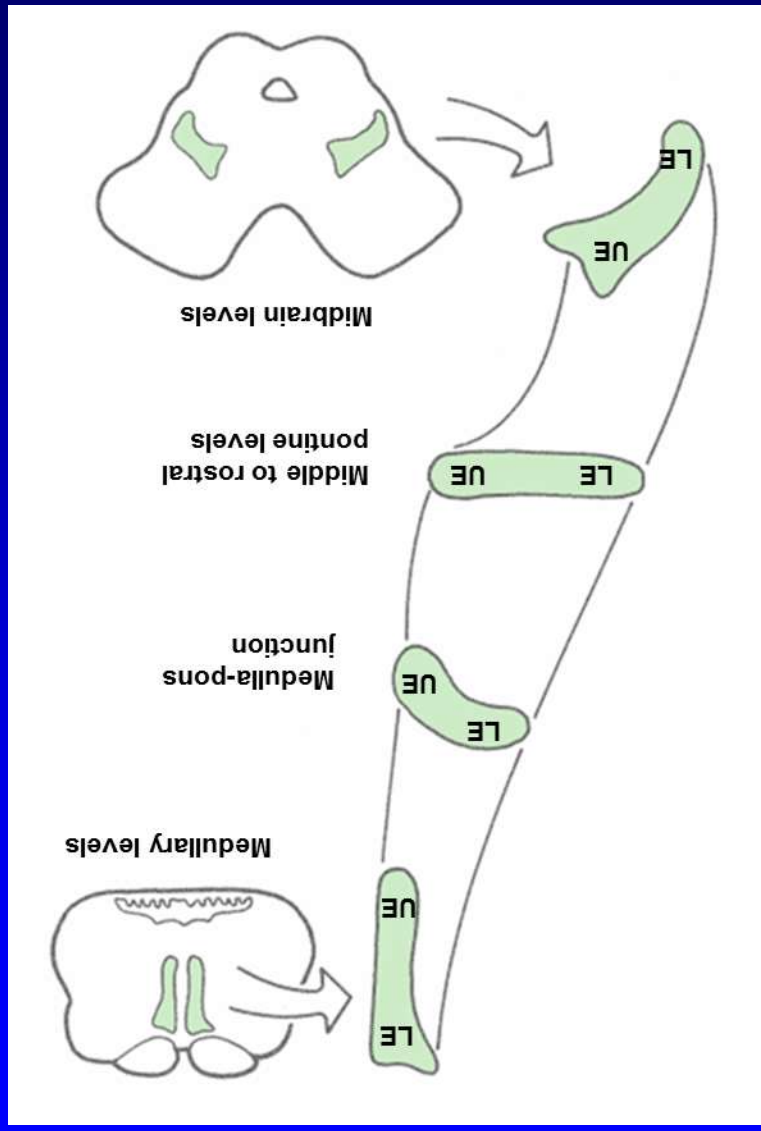
Medullary levels
Medulla-pons junction
Middle to rostral pontine levels
Midbrain levels
LE
UE

PCML Function

- 2-point discrimination
- Vibration
- Prorioception

PCML Function

- 2-point discrimination
- Vibration
- Prorioception

❖ **STEREOGNOSIS**

❖ **GRAPHESTHESIA**

❖ **Help in movement and Wight recognition**

PCML lesion associated symptoms

- Loss of 2-point discrimination sensation
- loss of Vibration sensation
- Loss Prorioception sensation

❖ **ASTEREOGNOSIS / STEREOGNOSIA**

❖ **AGRAPHESTHESIA**

❖ **ABAROGNOSIS**

❖ **SENSORY ATAXIA**

PCML lesion associated symptoms

- Loss of 2-point discrimination sensation
- loss of Vibration sensation
- Loss Prorioception sensation

❖ **ASTEREOGNOSIS / STEREOGNOSIA**

❖ **AGRAPHESTHESIA**

❖ **ABAROGNOSIS**

❖ **SENSORY ATAXIA**

PCML lesion associated symptoms

- Loss of 2-point discrimination sensation
- loss of Vibration sensation
- Loss Prorioception sensation

❖ **ASTEREOGNOSIS / STEREOGNOSIA**

❖ **AGRAPHESTHESIA**

❖ **ABAROGNOSIS**

❖ **SENSORY ATAXIA**

Antero-lateral system (ALS)

Sensations modalities

Fast

- 2-point discrimination
- Vibration
- Prorioception

Slow

- Temperature
- Crud touch (itch & rub)
- Pain

Antero-lateral system (ALS)
Other name: Spinothalamic pathway

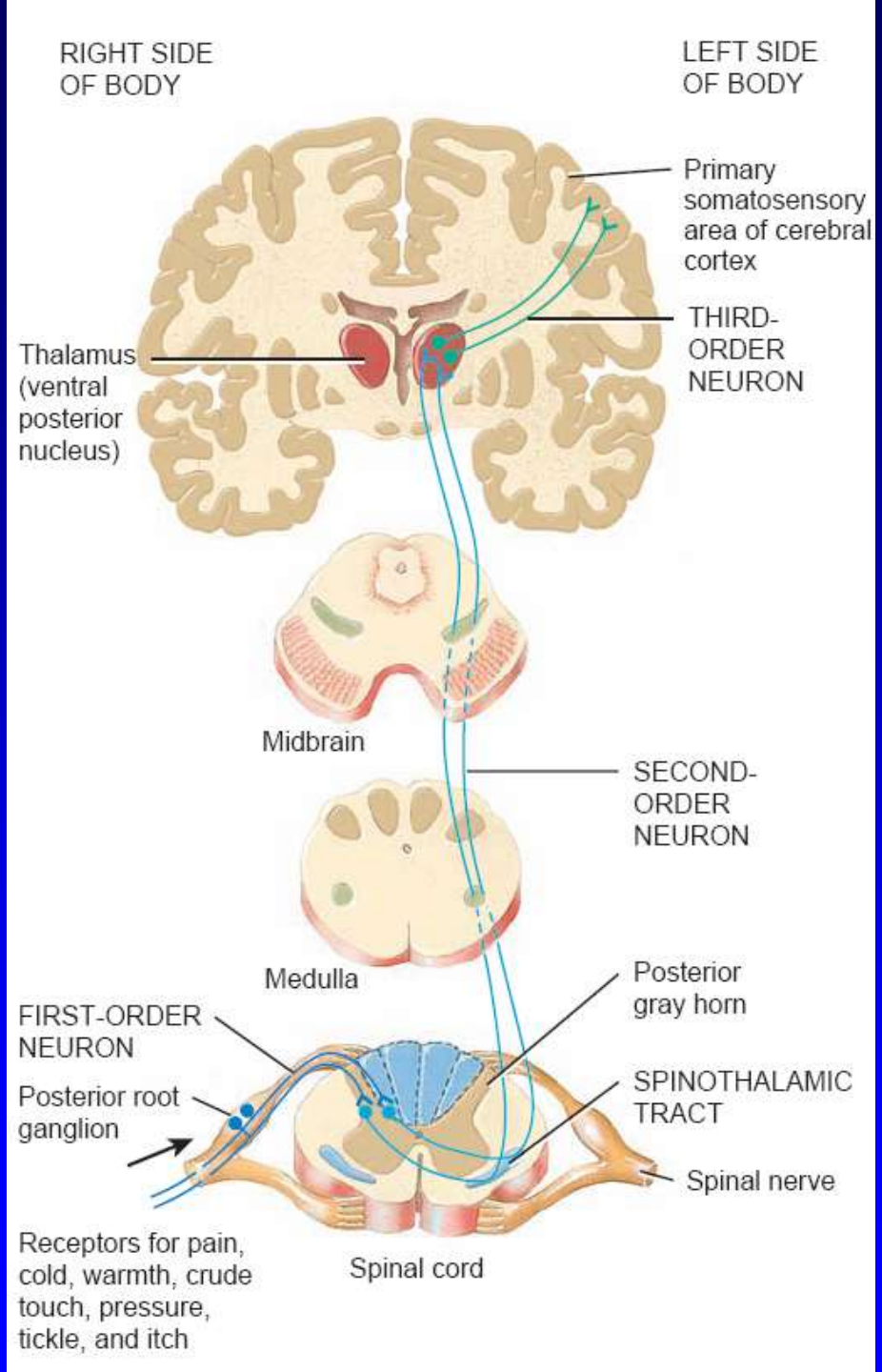
RIGHT SIDE OF BODY
LEFT SIDE OF BODY
Primary somatosensory area of cerebral cortex
THIRD-ORDER NEURON
Thalamus (ventral posterior nucleus)
Midbrain
SECOND-ORDER NEURON
Medulla
Posterior gray horn
FIRST-ORDER NEURON
SPINOTHALAMIC TRACT
Posterior root ganglion
Spinal nerve
Receptors for pain, cold, warmth, crude touch, pressure, tickle, and itch
Spinal cord

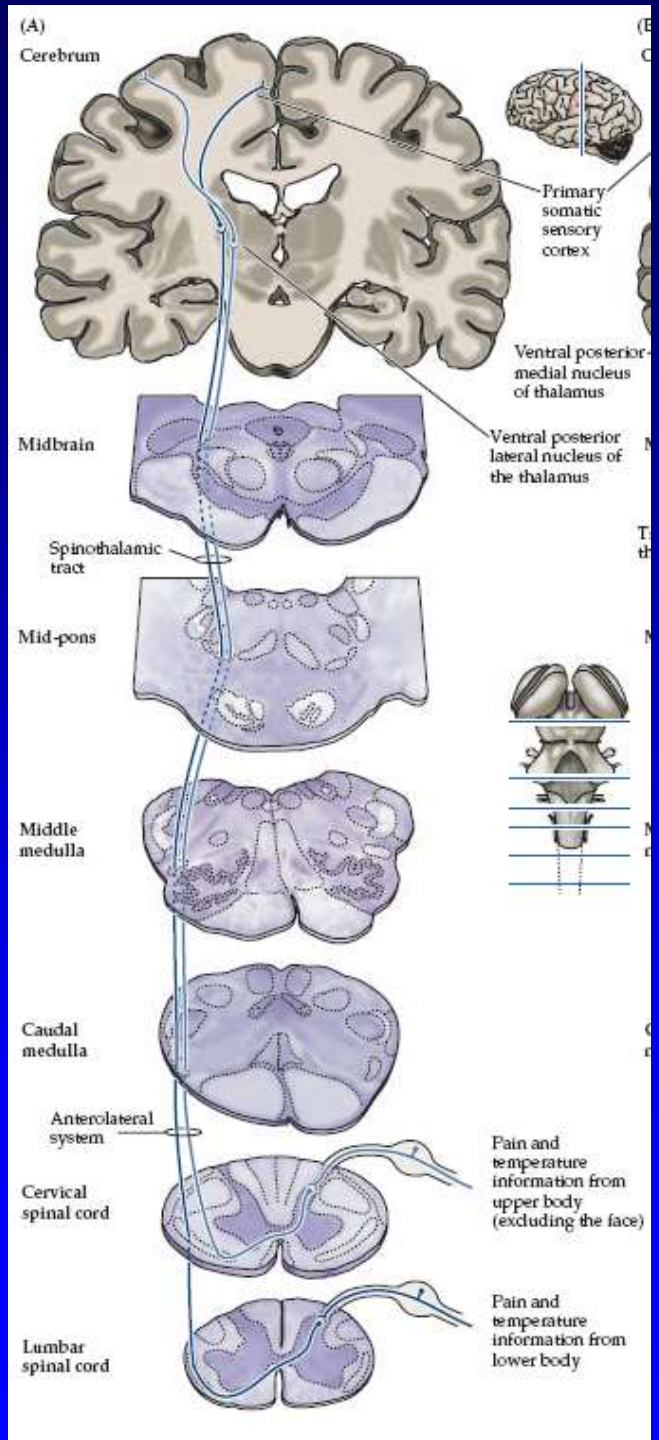
(A)
Cerebrum
Primary somatic sensory cortex
Ventral posterior-medial nucleus of thalamus
Ventral posterior lateral nucleus of the thalamus
Midbrain
Spinothalamic tract
Mid-pons
Middle medulla
Caudal medulla
Anterolateral system
Cervical spinal cord
Pain and temperature information from upper body (excluding the face)
Lumbar spinal cord
Pain and temperature information from lower body

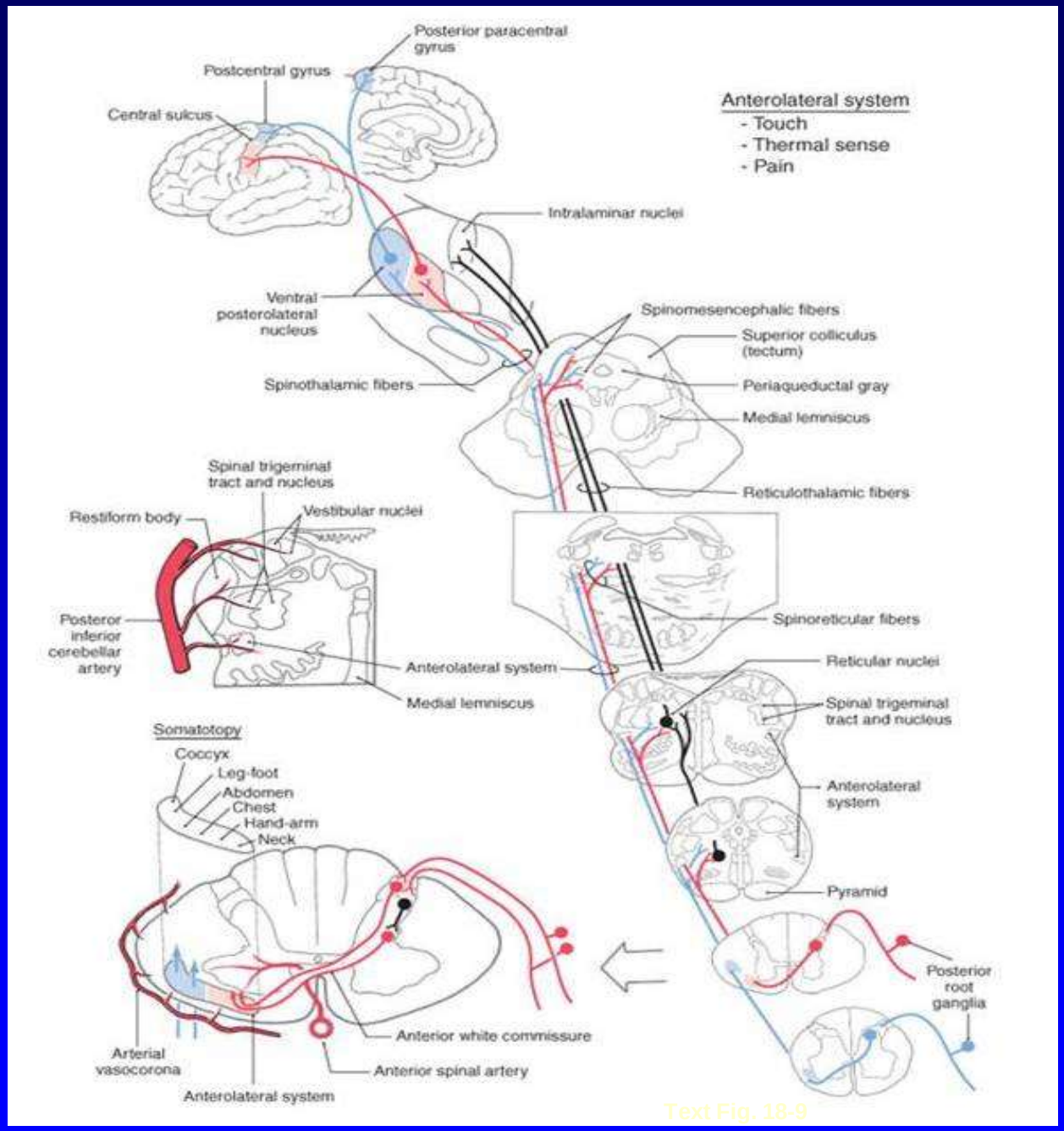
Posterior paracentral gyrus
Postcentral gyrus
Central sulcus
Anterolateral system
- Touch
- Thermal sense
- Pain
Intralaminar nuclei
Ventral posterolateral nucleus
Spinomesencephalic fibers
Superior colliculus (tectum)
Spinothalamic fibers
Periaqueductal gray
Medial lemniscus
Reticulothalamic fibers
Spinal trigeminal tract and nucleus
Restiform body
Vestibular nuclei
Posterior inferior cerebellar artery
Spinoreticular fibers
Anterolateral system
Reticular nuclei
Medial lemniscus
Spinal trigeminal tract and nucleus
Somatotopy
Coccyx
Leg-foot
Abdomen
Chest
Hand-arm
Neck
Anterolateral system
Pyramid
Posterior root ganglia
Anterior white commissure
Arterial vasocorona
Anterior spinal artery
Anterolateral system

Text Fig. 18-9

Syringomyelia and the ALS

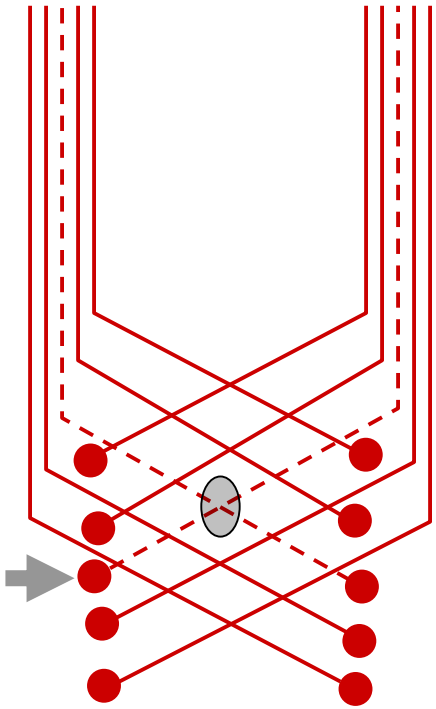

Spinal cord Hemisection and the ALS

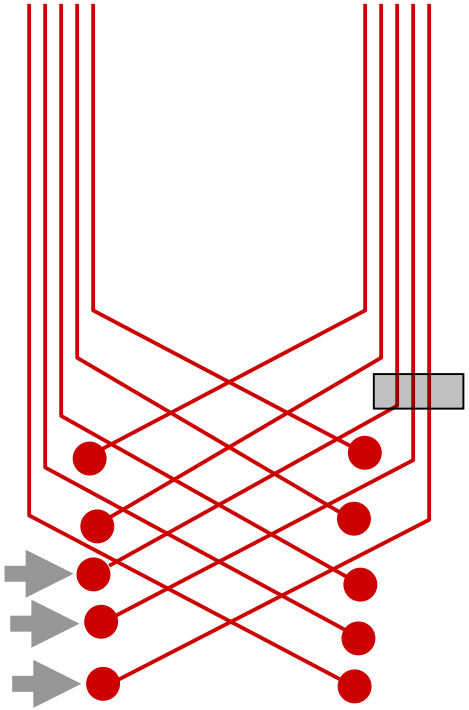

Dermatomes

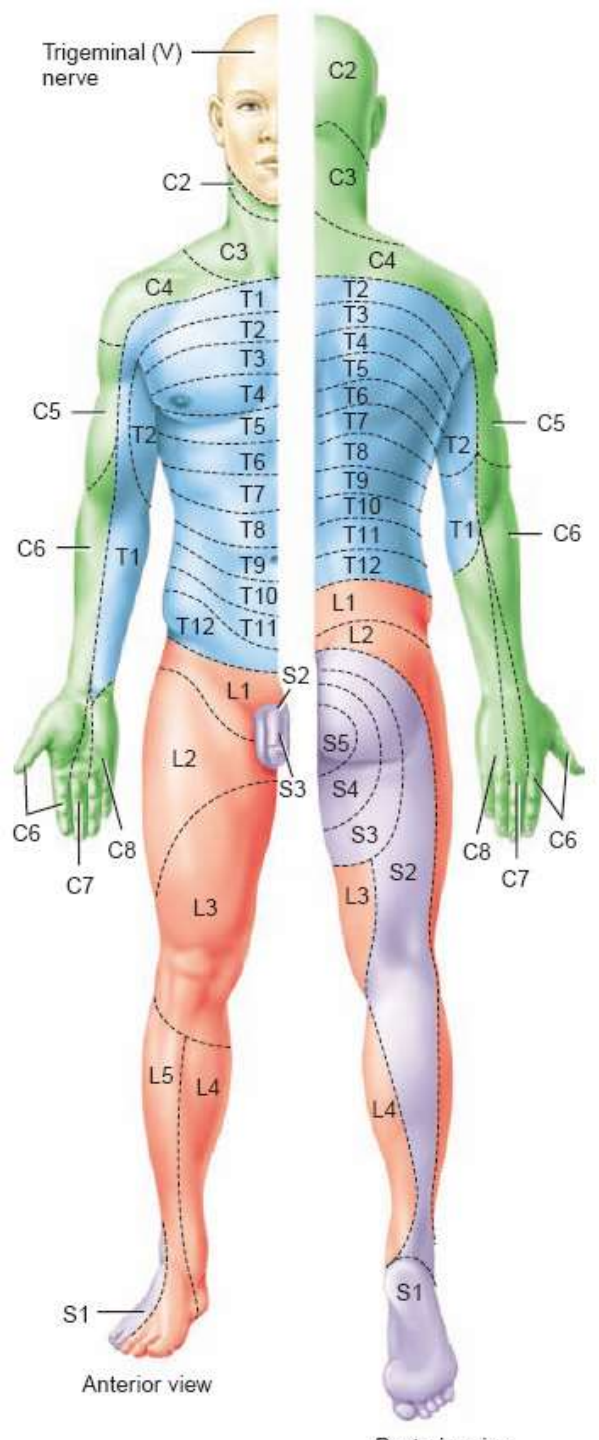
Trigeminal (V) nerve
C2
C3
C4
C5
C6
C7
C8
T1
T2
T3
T4
T5
T6
T7
T8
T9
T10
T11
T12
L1
L2
L3
L4
L5
S1
S2
S3
S4
S5
Anterior view

Dermatomes

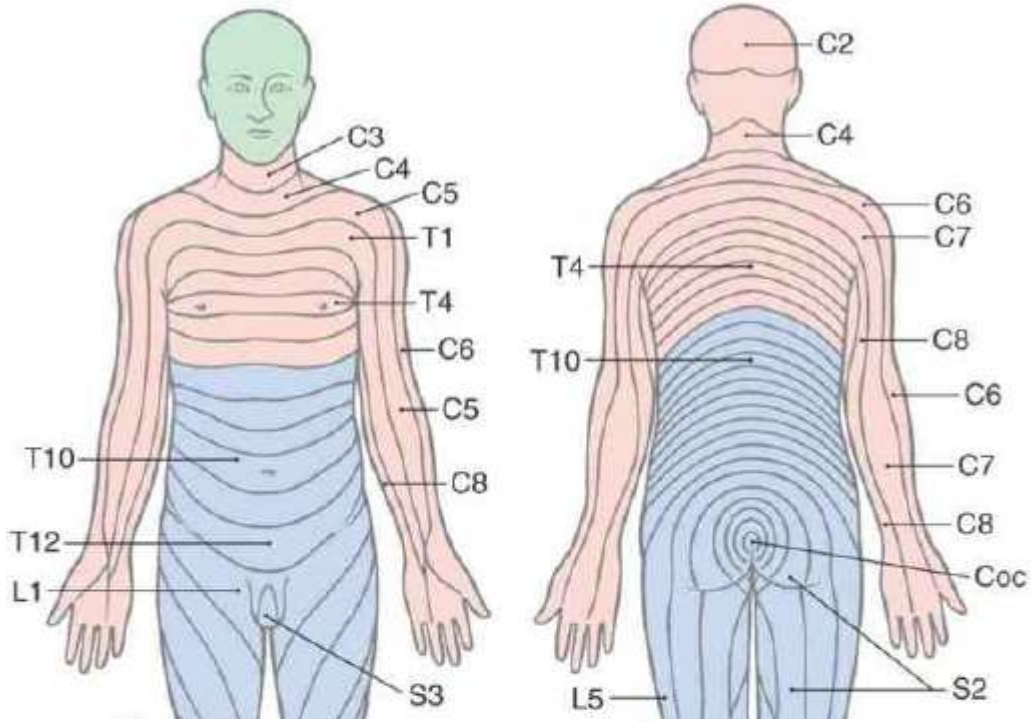
C3
C4
C5
T1
T4
C6
C5
T10
C8
T12
L1
S3
C2
C4
C6
C7
T4
C8
T10
C6
C7
C8
Coc
L5
S2

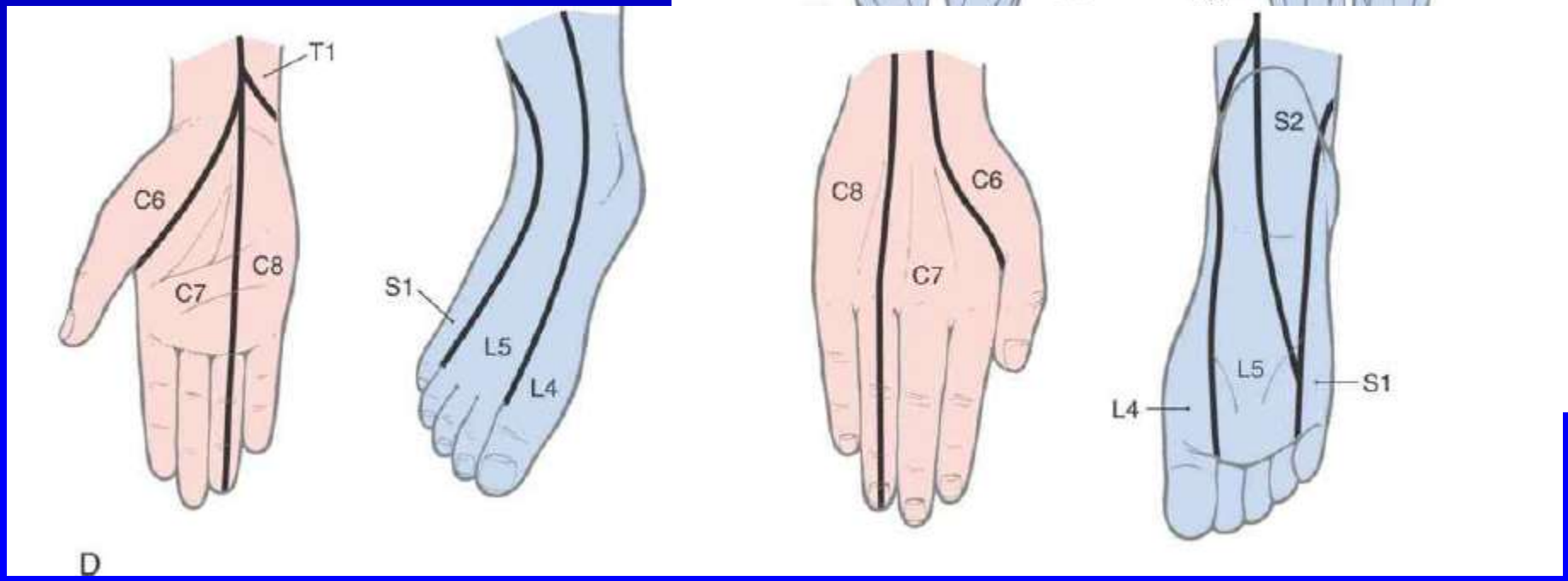
T1
C6
C8
C7
S1
L5
L4
C8
C6
C7
S2
L5
S1
L4
D

Dermatomes

- Shoulder (C5-C6)
- Hand (C6-C8): 6= thumb the, 7= index finger, 8= small finger
- Nipple (T4),
- Umbilicus (T10),
- Inguinal region (T12-L1),
- knee (L3, L4),
- The big toe (L4-L5)
- Small toe (S1)
- The genitalia and anus (S4 and S5)

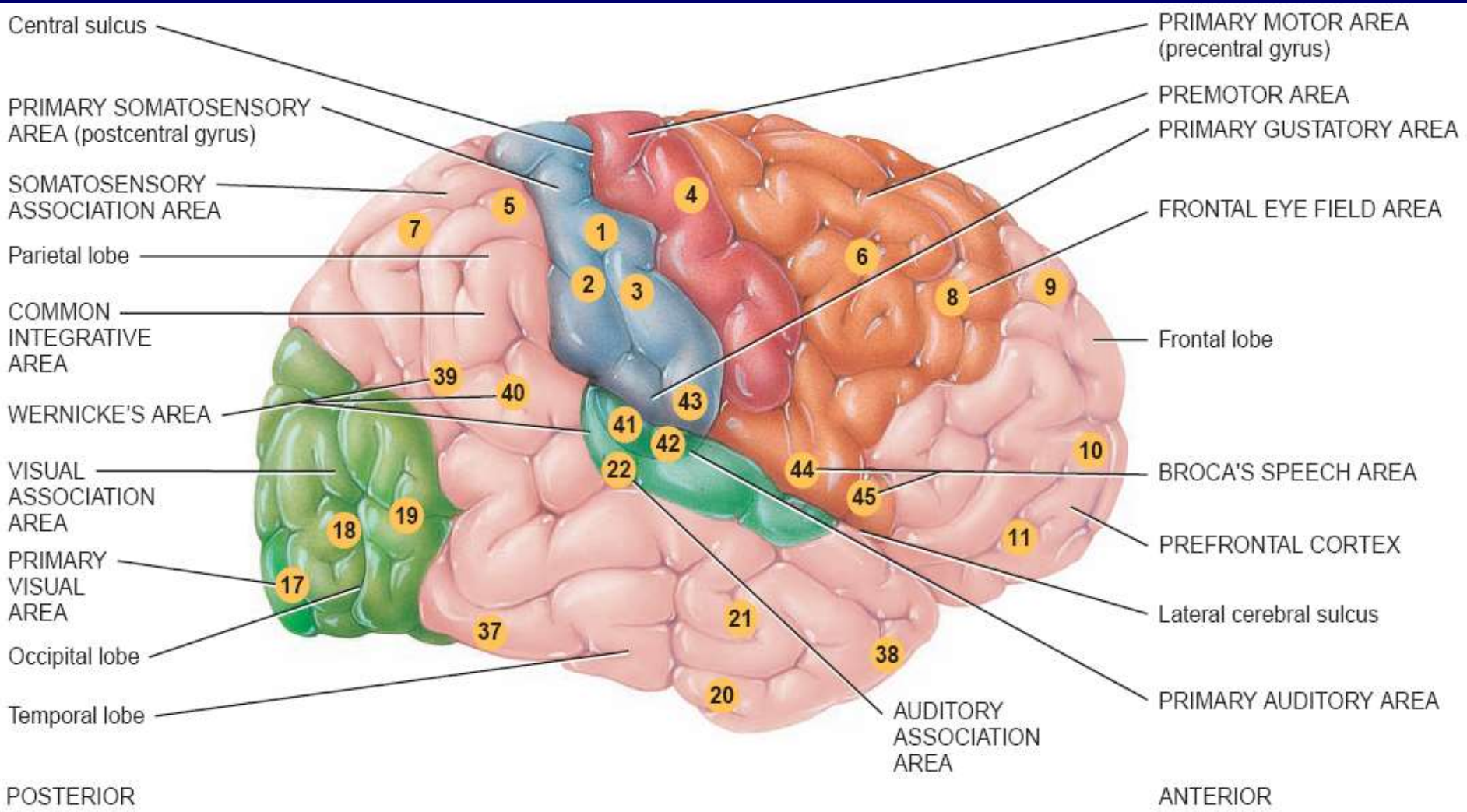

Lateral view of right cerebral hemisphere

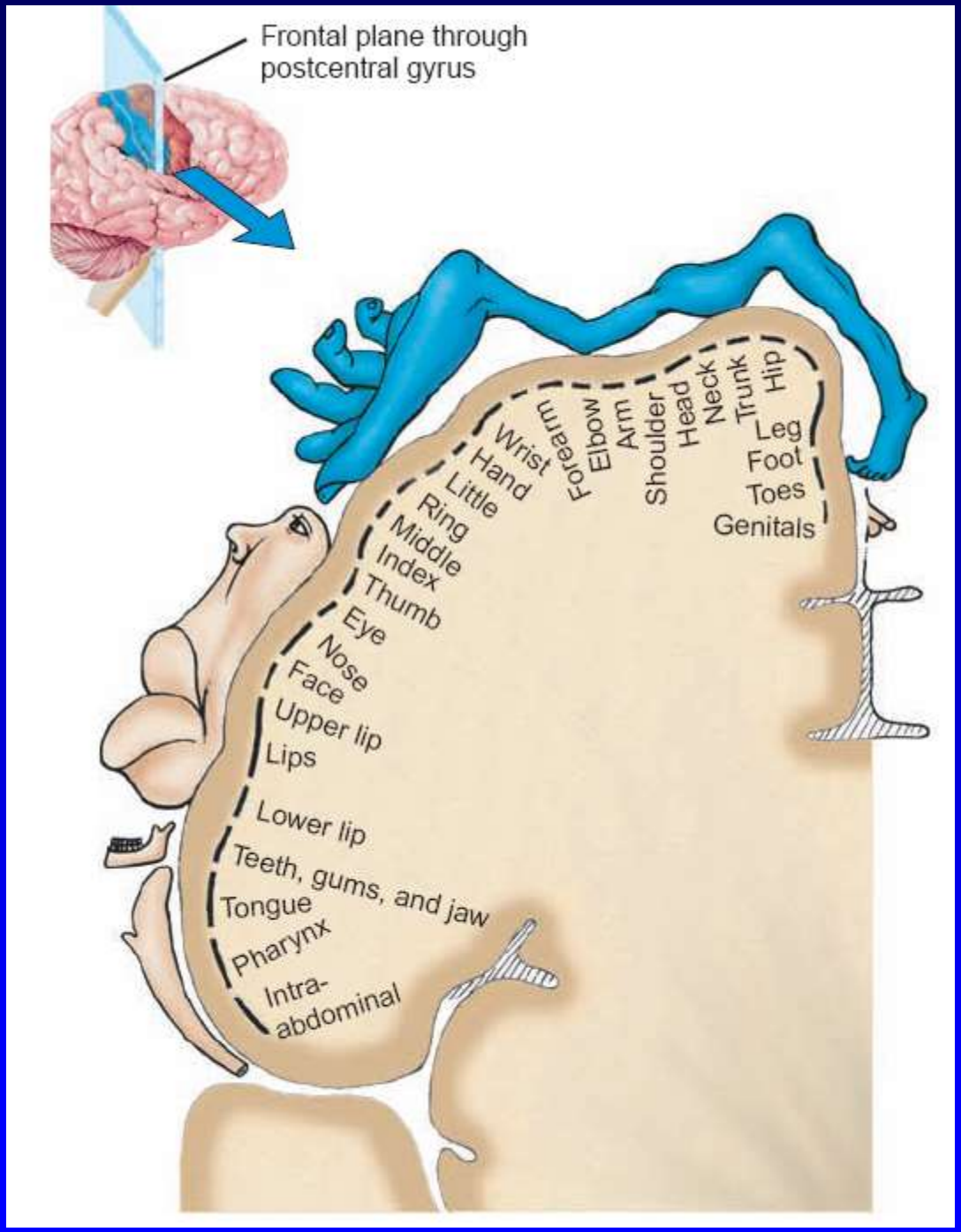
Frontal plane through
postcentral gyrus
Wrist
Hand
Little
Ring
Middle
Index
Thumb
Eye
Nose
Face
Upper lip
Lips
Lower lip
Teeth, gums, and jaw
Tongue
Pharynx
Intra-
abdominal
Forearm
Elbow
Arm
Shoulder
Head
Neck
Trunk
Hip
Leg
Foot
Toes
Genitals

- **Stocking-glove sensory loss**
  - **tabes dorsalis**

Visceral sensory & referred pain

Visceral sensory & referred pain

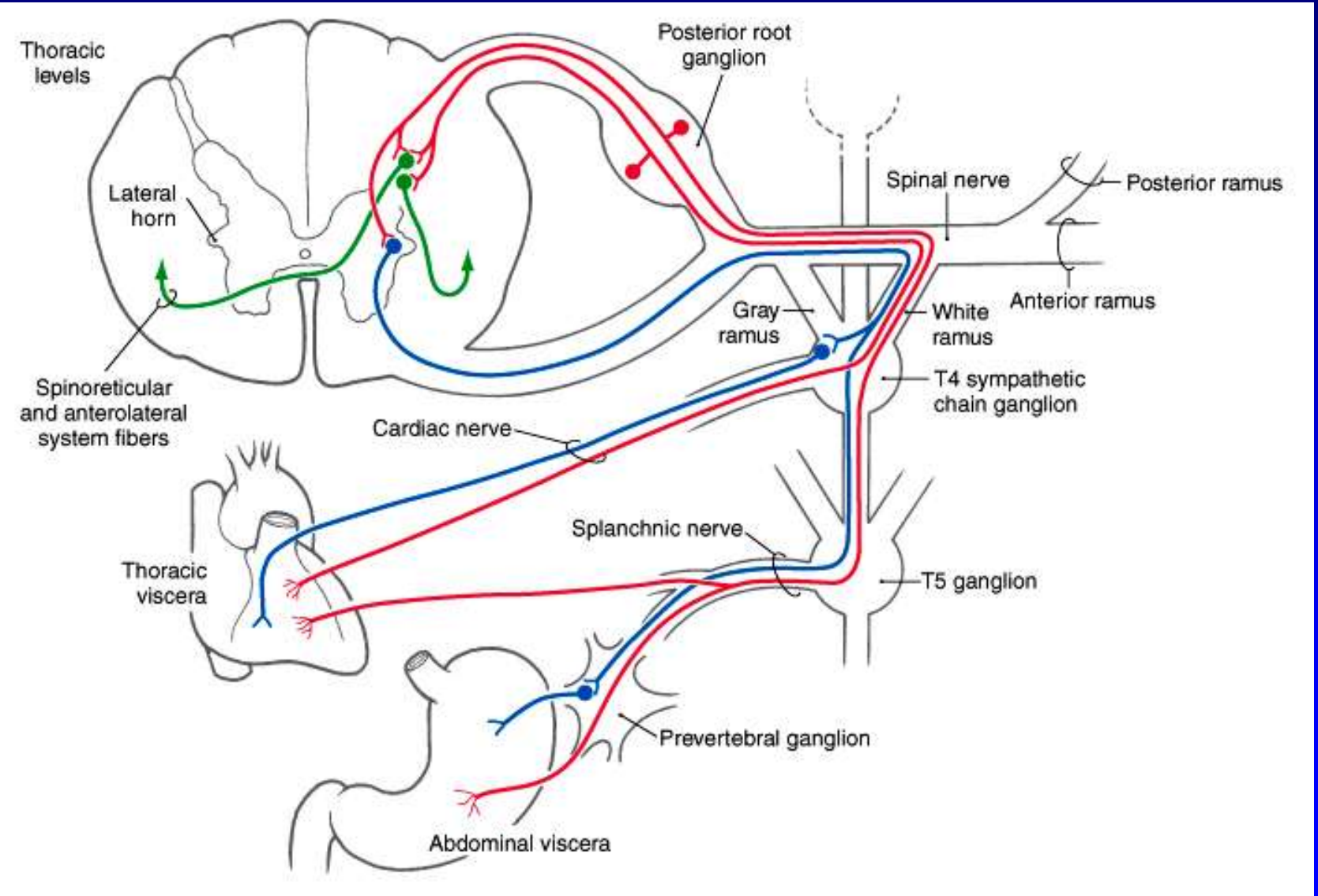

Visceral sensory & referred pain

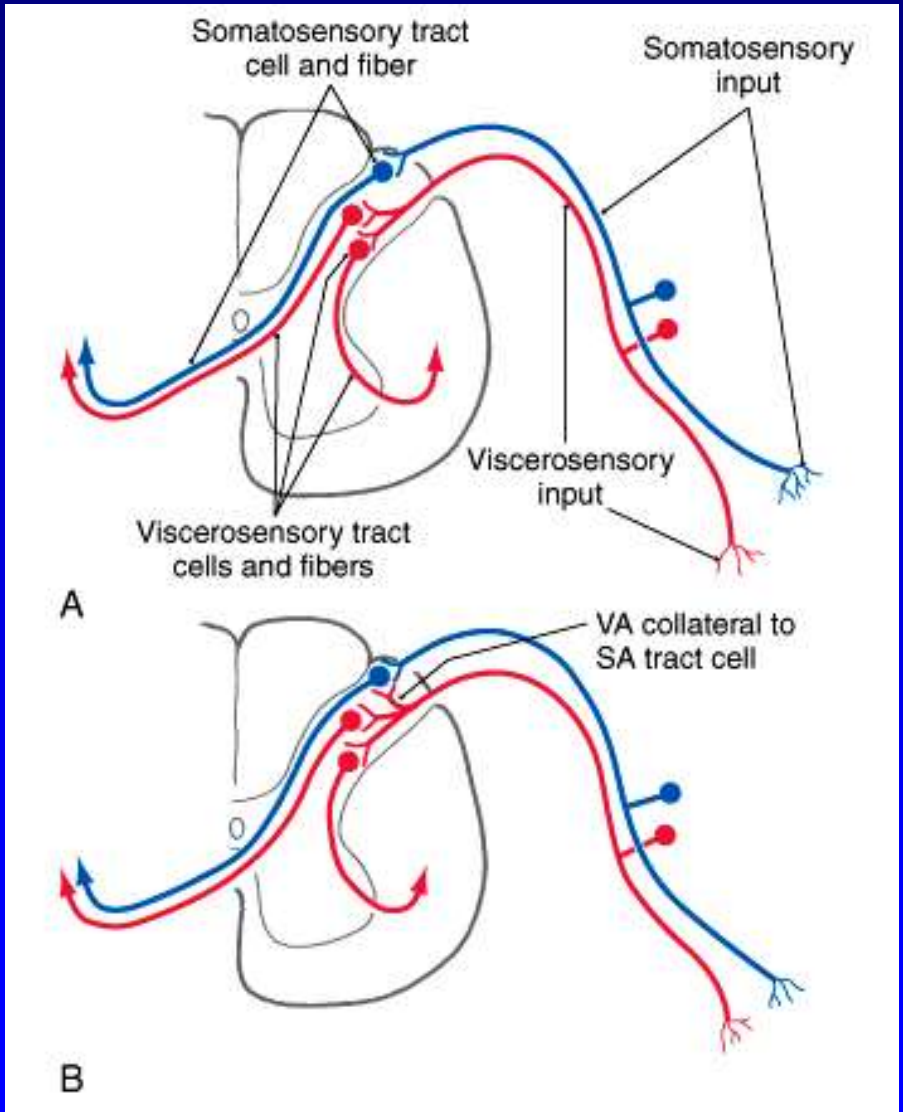

Visceral sensory & referred pain

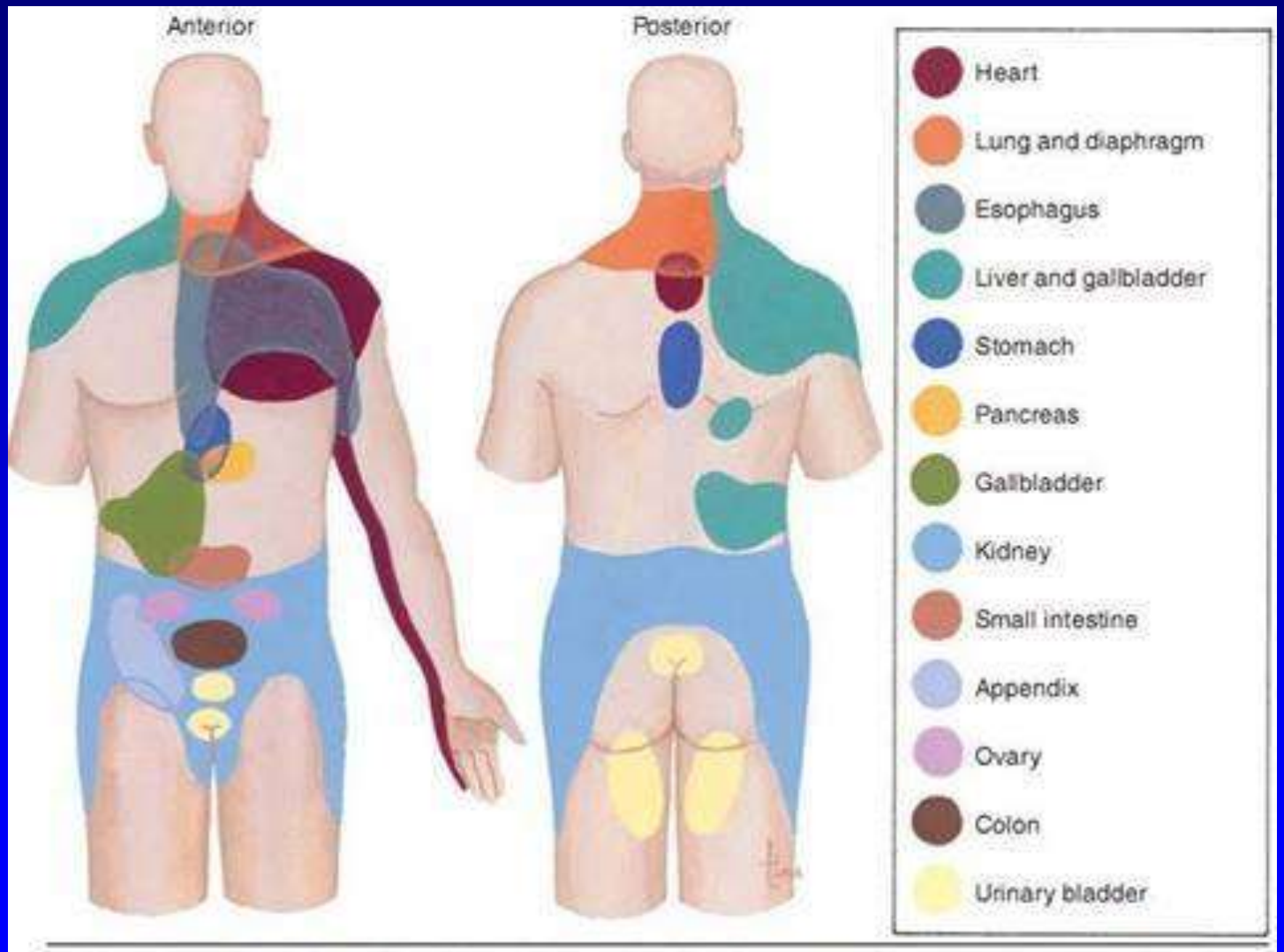

Referred pain. The sites for referred pain from various organs are shown.

Referred pain Vs. radiating pain

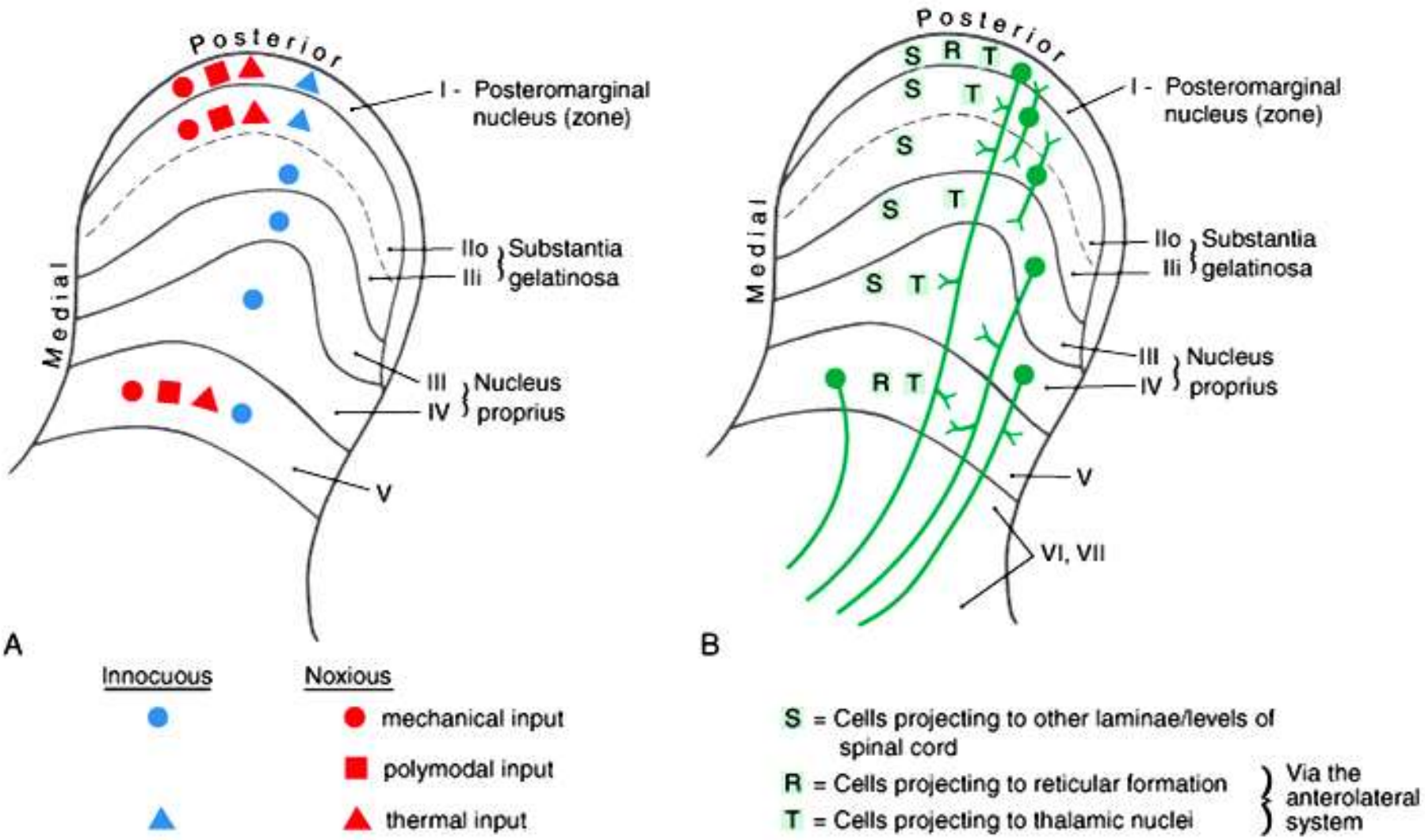
Posterior
Medial
I - Posteromarginal nucleus (zone)
IIo
IIi
Substantia gelatinosa
III
IV
Nucleus proprius
V
A
Innocuous
Noxious
mechanical input
polymodal input
thermal input
Posterior
Medial
S R T
S T
S
S T
S T
R T
I - Posteromarginal nucleus (zone)
IIo
IIi
Substantia gelatinosa
III
IV
Nucleus proprius
V
VI, VII
B
S = Cells projecting to other laminae/levels of spinal cord
R = Cells projecting to reticular formation
T = Cells projecting to thalamic nuclei
Via the anterolateral system

Text Fig. 18-7

Phantom limb

Deafferentation pain

Thalamic syndrom

deafferentation pain

anterolateral cordotomy Vs posterior root entry zone) procedure

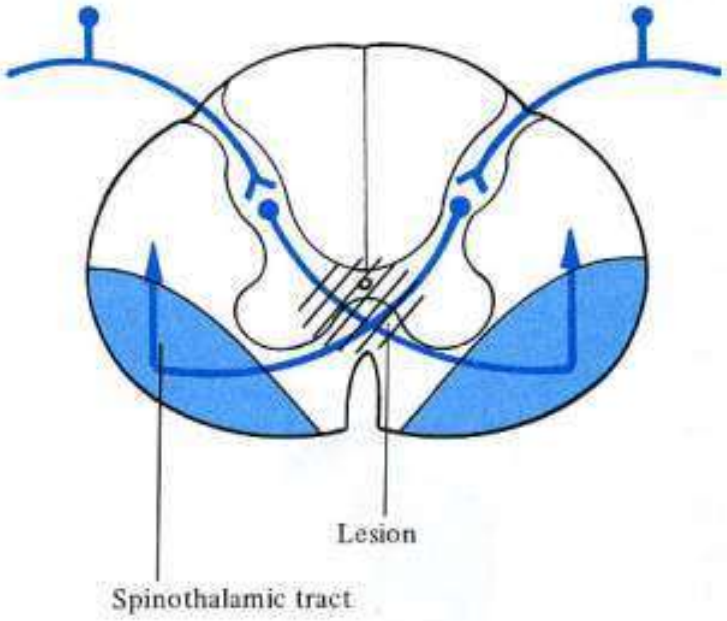

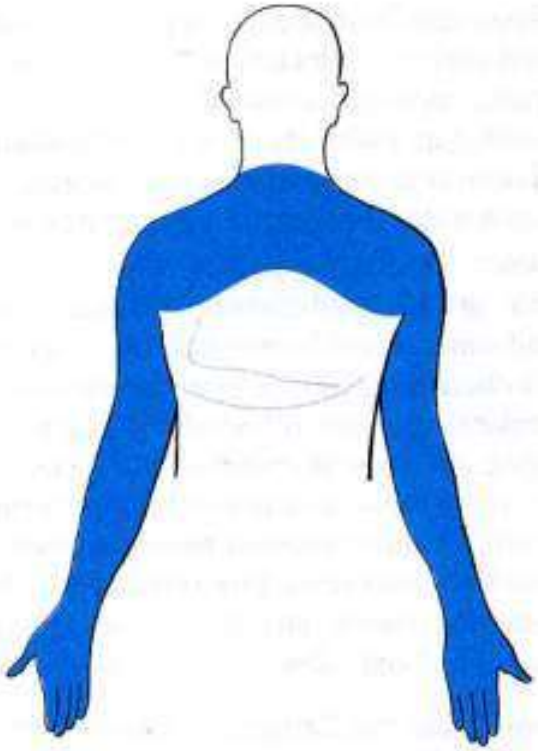

Syringomyelia

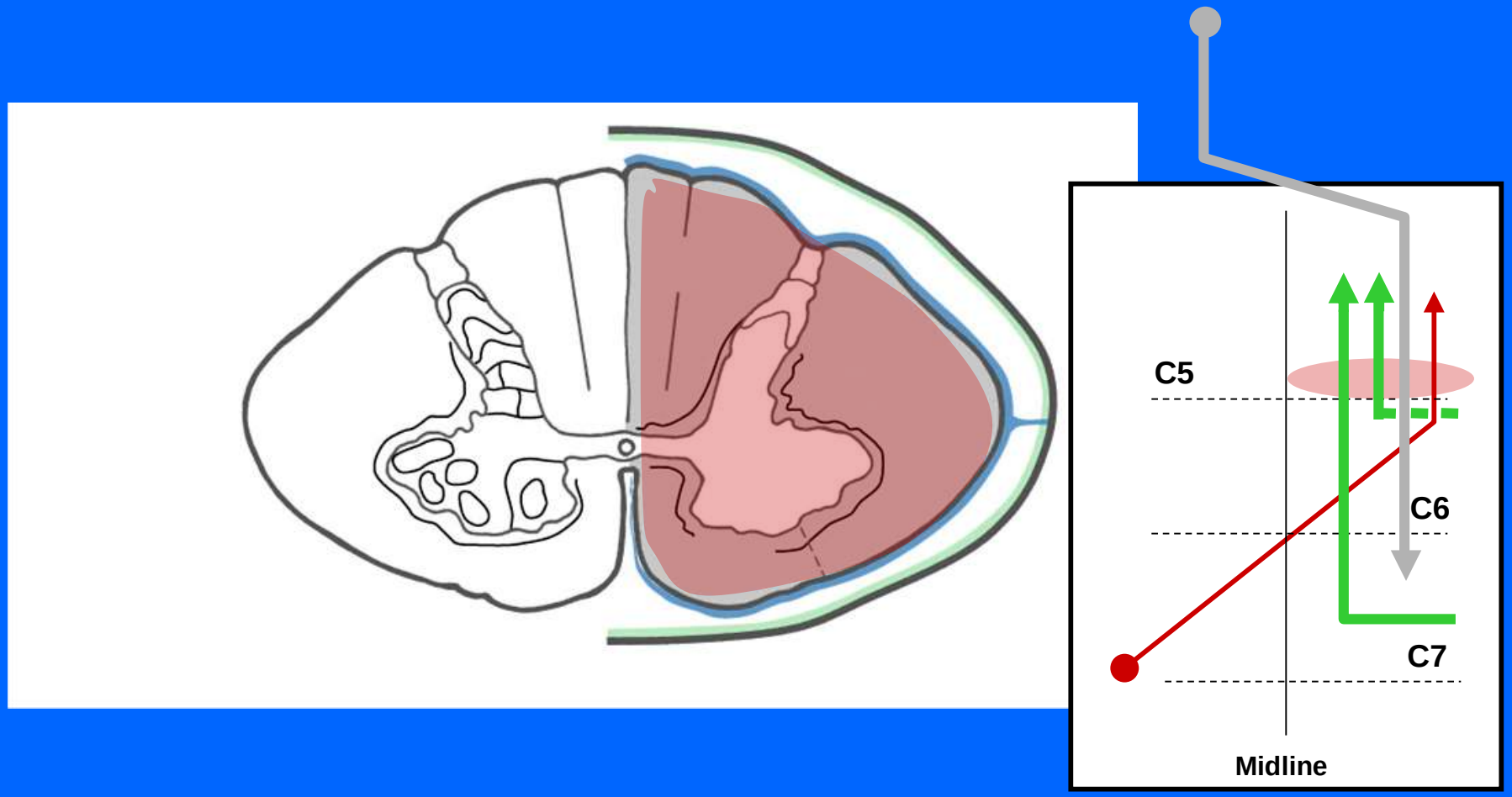
C5
C6
C7
Midline

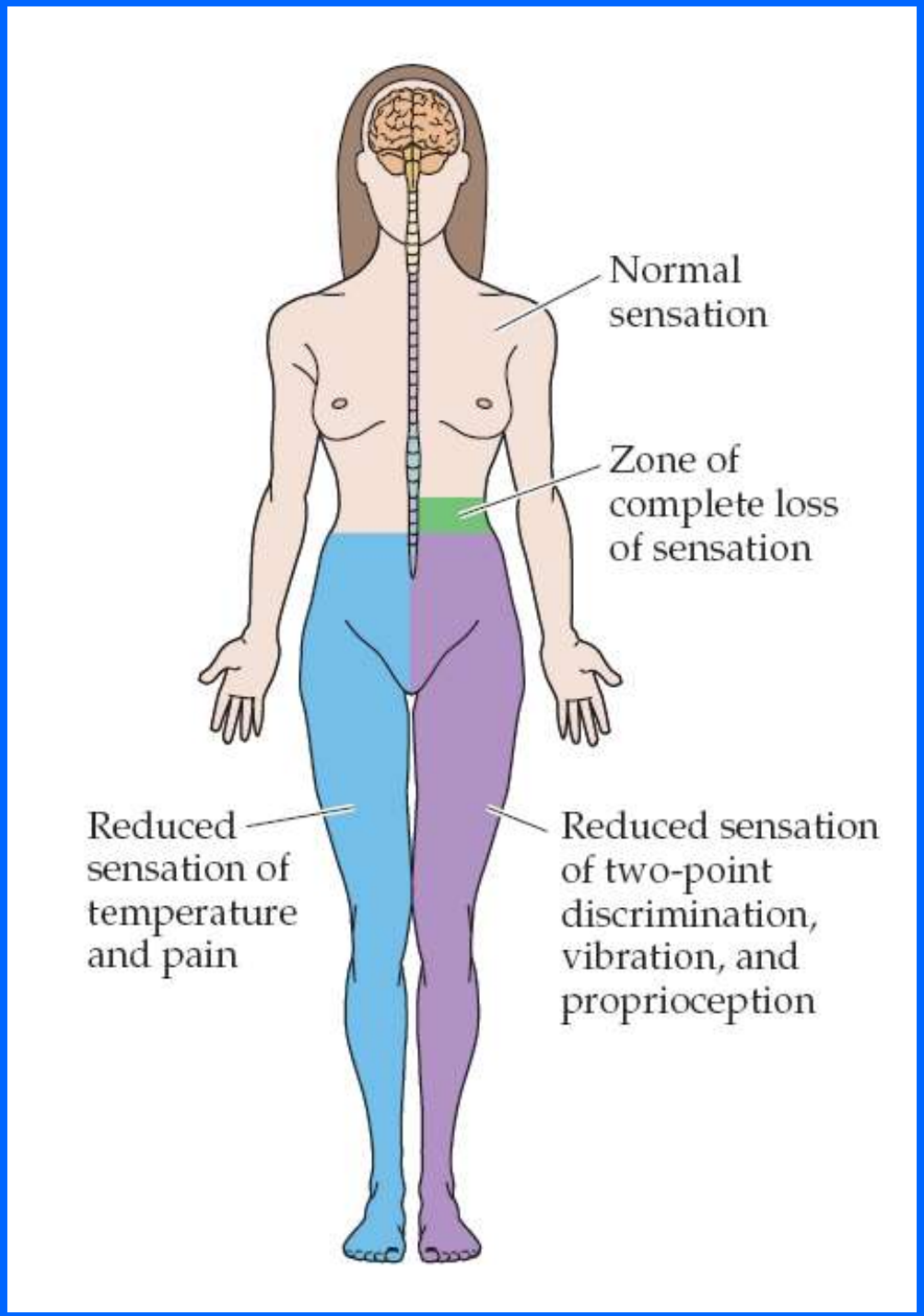
Normal sensation
Zone of complete loss of sensation
Reduced sensation of temperature and pain
Reduced sensation of two-point discrimination, vibration, and proprioception