

 Review Article

# Acute Limb Ischemia

Hideaki Obara, MD, PhD, Kentaro Matsubara, MD, PhD, and Yuko Kitagawa, MD, PhD

Acute limb ischemia (ALI) is a rapid decrease in lower limb blood flow due to acute occlusion of peripheral artery or bypass graft, and in ALI not only limbs but also life prognosis will be poor unless quick and appropriate treatment is given. The etiology is broadly divided into embolism and thrombosis with various comorbidities. The symptoms of ALI are abrupt with pain, numbness, and coldness of lower limb, and paresthesia, contracture, and irreversible purpura will appear with the exacerbation of ischemia. Severity and treatment strategy should be determined based on physical findings and image findings. Considering life prognosis, limb amputation should be done without hesitation when the limb was diagnosed as irreversible. ALI can be treated by means of open surgical revascularization, endovascular, or hybrid approach with rapid systemic administration of heparin. In any cases, evaluating the lesions by intraoperative angiography and appropriate additional treatment are important. ALI is a serious disease requiring urgent treatment, and it is essential to promptly perform the best initial treatment that can be performed at each facility. (This is a translation of *Jpn J Vasc Surg* 2018; 27: 109–114.)

**Keywords:** acute limb ischemia, embolectomy, endovascular treatment, hybrid therapy, thrombolysis

## Introduction

Acute limb ischemia (ALI) presents as sudden lower limb ischemia that can result in amputation, regardless of the underlying cause,<sup>1)</sup> unless appropriate treatment is administered. It has poor prognosis not only for the limb but also


for survival. In general, ALI progresses into advanced limb ischemia within 2 weeks from its acute onset, and it has a reported mortality rate of 15%–20% due to concurrent illness such as cardiovascular or cerebrovascular disease and ischemia–reperfusion injury.<sup>1,2)</sup> Thus, ALI requires localized treatment as well as strict systemic management.

## Etiology

The reported incidence of ALI is 1–1.5 individuals per 10,000 individuals per year.<sup>2,3)</sup> The causes of ALI, excluding trauma, are broadly divided into embolism and thrombosis. According to a recent report from England, the incidence rates of embolism, thrombosis due to an occlusive atherosclerotic lesion, complex factors, and stent or graft-related thrombosis are 46%, 24%, 20%, and 10%, respectively.<sup>2)</sup> In the 2012 annual report of the Japanese Society for Vascular Surgery based on enrolments in the National Clinical Database, the number of patients with embolism and thrombosis accounted for approximately half of the total patients enrolled in the database. Most cases of embolism are cardiogenic embolism, among which atrial fibrillation accounts for the majority. Other causes include valvular diseases, including post-valve replacement, left ventricular wall thrombosis following myocardial infarction, cardiac/aortic tumor, and paradoxical embolism. When surgical treatment is performed for embolism of unknown etiology without arrhythmia, a pathological specimen should be submitted for analysis to differentiate malignant tumors. Generally, the most common site of embolism is the femoral artery.<sup>4)</sup> Vascular embolism can be caused by atheroma of the aortic wall, such as in shaggy aorta and penetrating atherosclerotic ulcer, as well as aneurysm associated with mural thrombus, and iatrogenic embolism can arise from catheter manipulations. ALI due to peripheral embolism caused by popliteal artery aneurysm and thrombotic occlusion of an actual aneurysm are not rare and require another caution. Thrombosis occurs when chronic stenotic lesions in occlusive atherosclerosis cause acute obstruction resulting from plaque breakdown, circulatory failure, or a hypercoagulable state. This also includes thrombotic occlusion of stents and bypass grafts. The embolus can be trapped at stenotic lesions of arteriosclerosis obliterans, and it is often difficult to clearly distinguish embolism from thrombosis.

*Department of Surgery, Keio University School of Medicine, Tokyo, Japan*

Received: June 17, 2018; Accepted: June 17, 2018  
Corresponding author: Hideaki Obara, MD, PhD. Department of Surgery, Keio University School of Medicine, 35 Shinanomachi, Shinjuku-ku, 160-8582 Tokyo, Japan  
Tel: +81-3-3353-1211, Fax: +81-3-3355-4707  
E-mail: obara.z3@keio.jp  
This is a translation of *Jpn J Vasc Surg* 2018; 27: 109–114.

 ©2018 The Editorial Committee of Annals of Vascular Diseases. This article is distributed under the terms of the Creative Commons Attribution License, which permits use, distribution, and reproduction in any medium, provided the credit of the original work, a link to the license, and indication of any change are properly given, and the original work is not used for commercial purposes. Remixed or transformed contributions must be distributed under the same license as the original.

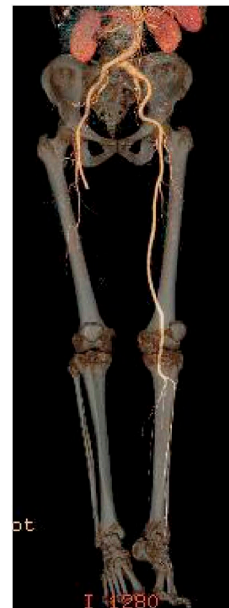Furthermore, in aortic dissection, compression of the true lumen by the false lumen can cause lower limb ischemia.

### Symptoms and Severity Classification

Characteristic physical findings of ALI include the 5Ps—acute onset of progressive pain in the affected limb (pain), pulselessness, pallor, paresthesia, and paralysis. After assessing blood flow in the dorsalis pedis and posterior tibial arteries with a Doppler instrument, blood pressure in the ankle is measured. ALI can be diagnosed when at least one of the 5P symptoms is present and the ankle blood pressure is  $\leq 50$  mmHg. When the ankle blood pressure is  $\geq 50$  mmHg, in many instances, it is not ALI but severity classification I to be described later. Resistance to ischemia differs depending on the tissue. In complete arterial obstruction, irreversible changes occur to the nerves in 4–6 h, to the muscles in 6–8 h, and to the skin in 8–12 h. The severity of ALI is generally classified using the TASC II and Rutherford classifications,<sup>1,5)</sup> in which four groups are classified according to the presence or absence of sensory disturbance, muscle weakness, and Doppler auscultation (Table 1).<sup>6)</sup> Foot drop (drop foot) is a highly urgent finding that causes peroneal nerve paralysis and is often the first symptom of motor paralysis. It should be duly assessed because it can be easily overlooked in medical examinations performed with the patient in the dorsal position and if the patient is frail. Unlike chronic limb ischemia, embolism that develops without collateral circulation presents with sudden and severe symptoms. On the contrary, thrombosis arises from an underlying chronic occlusive lesion, often progressing relatively gradually because of the development of collateral circulation, which gives some time allowance to treatment. However, several cases become serious, not only those presenting thrombotic occlusion with collateral circulation and those with underlying thrombophilic conditions (Fig. 1).

### Diagnosis

ALI is diagnosed on the basis of medical history, visual examination, palpation, and Doppler examination of the peripheral arterial pulse using vascular ultrasonography and contrast-enhanced computed tomography (CT) as imaging tests. To determine the range of the occluded site, for the close examination of the underlying disease and source of the embolus, and to distinguish among multiple embolisms, whole-body examination using contrast-enhanced CT of the lower limbs as well as of the head, thoracoabdominal, and pelvic areas is useful. Contrast-enhanced CT requires 20–30 min for completion and can be performed while preparing the operating room. ALI has poor prognosis for the limbs as well as for survival, and it is recommended to perform a CT whenever pos-



**Fig. 1** Acute limb ischemia associated with antiphospholipid syndrome occurred in a 73-year-old male. Three-dimensional reconstruction of a computed tomographic angiogram shows total occlusion of the entire femoropopliteal artery and below the knee arteries.

**Table 1** Stages of acute limb ischemia

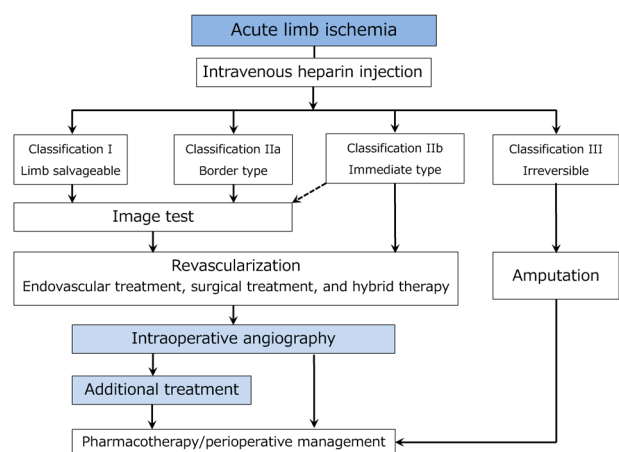
Classification	Description/prognosis	Findings		Doppler signals	
		Sensory loss	Muscle weakness	Arterial	Venous
I. Viable	Not immediately threatened	None	None	Audible	Audible
II. Threatened					
a. Marginally	Salvageable if promptly treated	Minimal (toes) or none	None	(Often) inaudible	Audible
b. Immediately	Salvageable with immediate revascularization	More than toes, associated with rest pain	Mild, moderate	(Usually) inaudible	Audible
III. Irreversible	Major tissue loss or permanent nerve damage inevitable	Profound, anesthetic	Profound, paralysis (rigor)	Inaudible	Inaudible

Reproduced and partially modified from Reference 6 by permission of Japanese College of Angiology. Reprinted from J Vasc Surg., 45 Suppl S, Norgren L, Hiatt WR, Dormandy JA, et al., Inter-society consensus for the management of peripheral arterial disease (TASC II), S5-67, Copyright (2007), with permission from the Society for Vascular Surgery®.

sible, even for cases with severity classification IIb. When contrast-enhanced examination cannot be performed, such as in severe renal dysfunction and/or allergy, simple CT alone can provide important information regarding aneurysms and arterial calcification. To identify the cause and evaluate the patient's general health status, electrocardiography, thoracoabdominal radiography, blood count, biochemistry, coagulation system testing (including protein C and S, anticardiolipin antibodies, and antithrombin III, etc for thrombophilia screening), urine analysis, blood gas analysis, and echocardiography are performed. In particular, blood and urinary myoglobin, blood creatine kinase (CK), lactate dehydrogenase (LDH), potassium (K), and lactic acid (on blood gas analysis) levels and the presence or absence of acidosis are important parameters to determine the severity of ischemia and to predict the onset of ischemia–reperfusion injury. However, currently, it is often difficult to clearly distinguish cases with severity classifications IIb and III.

## Treatment

Upon the diagnosis of ALI, as long as heparin therapy is not contraindicated, an intravenous injection of unfractionated heparin (50–100 units/kg) is immediately administered to prevent the proximal and distal progression of secondary thrombosis to the site of occlusion, and a systemic administration of thrombolytic agents is not recommended. Subsequently, the severity and treatment plan are determined (Fig. 2). When severity classification III with severe motor paralysis, stiffness, and cyanosis of the skin is already observed, it is considered as irreversible ischemia and limb amputation will be needed. Furthermore, in patients with extensive ischemia due to high occlusion and when time has passed since its onset, there is a high risk of severe ischemia–reperfusion injury; thus, limb amputation might be necessary to prioritize the patient's life.

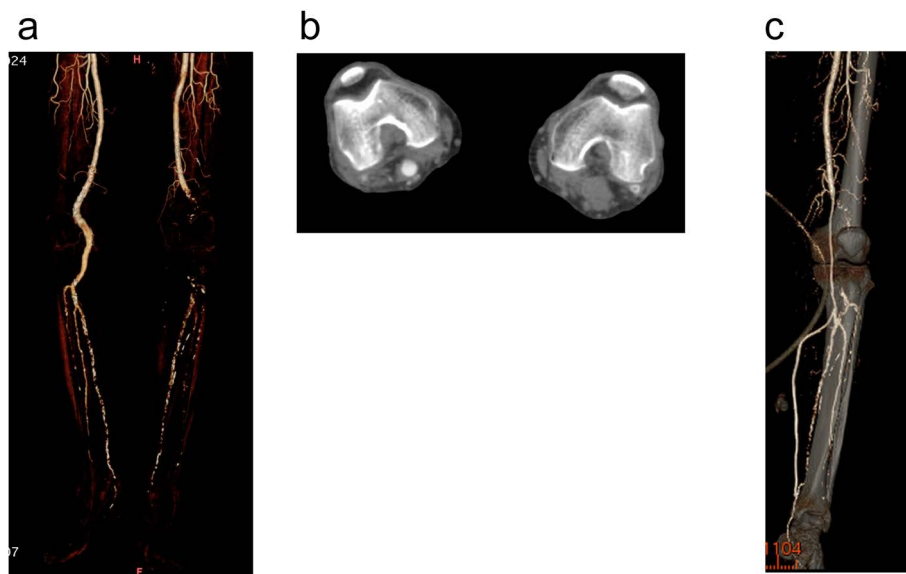


**Fig. 2** Algorithm for the treatment of acute limb ischemia.

Treatment methods for ALI include surgical treatment (such as thromboembolectomy and bypass surgery), endovascular treatment (such as catheter-directed thrombolysis [CDT], percutaneous thrombus aspiration, and stent placement), and hybrid treatment that combines both therapies. A meta-analysis of five randomized controlled trials<sup>7–12</sup>) investigating whether surgical or endovascular treatment (thrombolytic therapy) should be performed as the first line of treatment for ALI was reported in 2013.<sup>13</sup>) While there was no significant difference between the two groups in terms of limb salvage and mortality rates, the endovascular treatment group showed a significantly higher incidence of severe complications, such as stroke and bleeding, within 30 days of treatment. In recent years, the popularization of hybrid operating rooms has led to hybrid treatment with endovascular surgery being simultaneously performed under intraoperative angiography for residual lesions following surgical thromboembolectomy. Diagnosis by angiography, with the initial and additional treatments simultaneously performed, enables extremely effective revascularization (Fig. 2). However, rather than being overly particular regarding complete revascularization, surgeons should save time and perform adequate and necessary therapeutic procedures to salvage the limb to the best of their ability. In fact, when severity classification IIb is determined, immediate surgical revascularization is indicated to eliminate the ischemia as soon as possible. For severity classifications I and IIa, there is relatively more time to spare; thus, endovascular treatment is also an option as the initial therapy.

## Surgical revascularization

Currently, surgical treatment for ALI includes thromboembolectomy using a balloon catheter by arterial cut-down approach, bypass surgery, thromboendarterectomy, patch plasty, and intraoperative thrombolysis. Thromboembolectomy using a Fogarty catheter developed by Thomas Fogarty in 1963<sup>14</sup>) completely changed the treatment system for ALI and largely improved the associated treatment results. More than 50 years later, this Fogarty thromboembolectomy still remains one of the standard treatments. In recent years, the over-the-wire type Fogarty catheter has become available in Japan, enabling intraoperative selective fluoroscopically assisted thromboembolectomy, which has led to the rapid popularization of hybrid treatments, such as thromboembolectomy combined with subsequent balloon dilatation or stent placement using a guidewire passed through the lesion. In 2014, de Donato et al. retrospectively compared 112 patients who underwent conventional thrombectomy and 210 patients who received hybrid treatment. Although they observed no significant difference between the two groups in terms of early complications and long-term sur-



**Fig. 3** Acute limb ischemia due to popliteal artery aneurysm occurred in a 91-year-old male patient who presented with acute onset of severe left lower extremity pain. Computed tomography (CT) shows complete thrombotic occlusion of the left popliteal aneurysm with distal embolization (**a**: volume rendering, **b**: axial view). **c**: Three-dimensional reconstruction of a CT angiogram. Urgent sequential vein bypass grafting (femoro-tibioperoneal trunk and posterior tibial artery) was performed.

vival, the hybrid treatment group was superior in terms of primary/secondary patency, limb salvage, and repeat treatment avoidance rates; thus, hybrid treatment was strongly recommended.<sup>15)</sup> Surgical thromboembolectomy can be performed under local anesthesia. However, patients with ALI can be in a poor general condition, and management by an anesthesiologist is recommended. When sufficient peripheral blood flow cannot be obtained despite thromboembolectomy, additional endovascular treatments are performed (hybrid treatment); when hybrid treatment is difficult, a suitable treatment, such as bypass surgery and patch plasty of the anastomotic site (in cases of bypass graft occlusion), should be rapidly administered to salvage the limb.

### Catheter-directed thrombolysis (CDT)

Target lesions of ALI for which CDT is indicated often affect the femoral artery and arteries distal to the femoro-popliteal arteries. In general, a 6-F sheath is antegradely placed in the common femoral artery of the affected side. After inserting a guidewire to the level of the ankle, a 4-F multihole catheter is positioned in the thrombus. While verifying on angiography, 240,000–480,000 units of urokinase are directly delivered within the thrombus (health insurance covers up to 240,000 units per day in Japan), after which a catheter is placed and CDT is performed over several days. CDT requires more time than does surgical treatment. Therefore, CDT should be considered when there is time, such as in severity classifications I and

IIa.<sup>1)</sup> In contrast, reperfusion after CDT is slower than with surgical thromboembolectomy and can, therefore, reduce the risk of ischemia–reperfusion injury.<sup>1)</sup> Furthermore, in the United States, tissue plasminogen activator (t-PA) is generally used as a thrombolytic agent,<sup>3)</sup> whereas in Japan, its use for the present condition is not covered by health insurance.

### Percutaneous thrombus aspiration

The inner diameter of the catheter or sheath used is often much smaller than that of the thrombus being removed, and percutaneous thrombus aspiration is rarely indicated in the iliac artery area containing several thrombi. The concurrent use of CDT is recommended and is expected to shorten the duration of ischemia more compared with that by CDT alone.

### Thrombosed popliteal aneurysm

Moreover, 3.5% of ALI cases are caused by thrombosed popliteal artery aneurysms<sup>16)</sup> and approximately half of the popliteal artery aneurysms present with ALI<sup>17)</sup>; therefore, thrombosed popliteal aneurysm should always be considered in ALI. Despite revascularization, 8%–18% of patients require limb amputation<sup>18,19)</sup>; thus, it has poor prognosis of the limbs, thereby requiring a rapid diagnosis and an appropriate treatment selection. When endovascular treatment is selected without noticing the presence of a popliteal artery aneurysm, there is a risk of the exacerbation of thromboembolism due to the guidewire or catheter

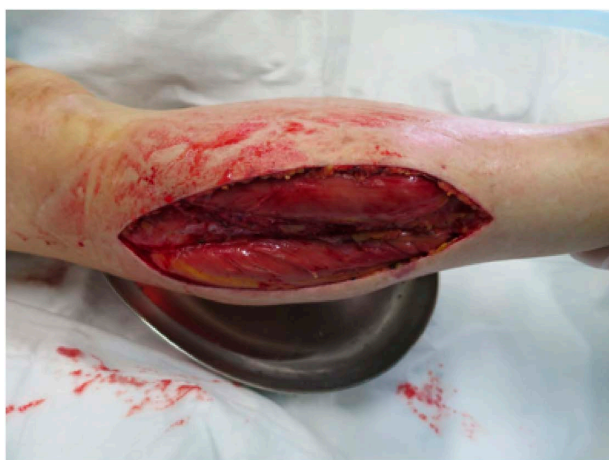manipulations. Several patients have poor distal run-off due to diffuse thromboembolism. In such case, after the run-off is achieved by thrombolysis or thromboembolectomy, bypass surgery is performed (Fig. 3).

### Myoneuropathic metabolic syndrome (MNMS)

Prolonged ischemia can cause muscle cell liquefactive necrosis and  $K^+$  ion, myoglobin, creatine kinase, lactic acid, and superoxide<sup>20)</sup> accumulation in the affected limb. These metabolites perfuse throughout the body upon revascularization and cause hyperkalemia, arrhythmia, pulmonary edema, metabolic acidosis, and myoglobinuria, and in severe cases, it can cause sudden death from heart and renal failure. The so-called ischemia–reperfusion injury is a severe complication that determines prognosis after the revascularization of ALI. Haimovici put forward this disease concept as MNMS,<sup>21)</sup> and the concept is widely used in Japan. Although there are still no established prevention and treatment methods, treatment is generally performed using various blood purification methods. When the patient's general condition does not improve despite such treatment, the affected limb requires amputation. MNMS can be prevented by ensuring the urine volume by forced diuresis and intraoperative and subsequent blood purification. In patients at borderline between primary limb amputation and revascularization, strict systemic management and MNMS-preventive measures are indispensable.

### Compartment syndrome

In compartment syndrome, increased capillary permeability at the time of ischemic reperfusion causes localized edema and increased intramuscular compartment (compartmental) pressure, which leads to circulatory disturbance and neuromuscular dysfunction. The lower



**Fig. 4** Lateral fasciotomy of right lower leg was performed in an 86-year-old male who developed compartment syndrome after the arterial reconstruction for acute limb ischemia.

limbs comprise four muscular compartments, and when the pressure within each compartment exceeds 30 mmHg, irreversible nerve and muscle necrosis occurs, and in some instances, lower limb amputation is necessary even if revascularization is successful.<sup>22)</sup> If leg swelling is observed after revascularization, the pressure within each compartment is measured (via needle insertion), and if the pressure exceeds 30 mmHg, then relaxation incision (fasciotomy) should be positively considered (Fig. 4).

### Postoperative Management

Anticoagulant therapy with heparin is continued in the early postoperative period. In the event of thrombosis and cardiogenic embolism associated with the thrombophilic conditions and localized lesions, long-term anticoagulant therapy with warfarin or direct oral anticoagulant treatment is needed. In patients with bypass graft occlusion in whom patency is successfully achieved by emergency thrombolytic therapy, anticoagulant therapy is intensified if anastomotic stenosis persists, after which a subsequent revascularization, such as patch plasty of the anastomotic site and re-bypass surgery, is considered.

### Conclusion

In the treatment of ALI, prognoses of the limbs and survival vary according to the accuracy of evaluation and rapid therapeutic interventions, including revascularization and limb amputation. In determining the treatment strategy by taking into account the precise preoperative diagnosis and additional treatments, preoperative CT examination and intraoperative angiography are extremely useful. The greatest benefit of surgical treatment is, by far, the early elimination of the ischemia. In the treatment of ALI, vascular surgeons should be well experienced in all treatment methods, including surgical and endovascular treatments (as initial and additional treatments), fasciotomy, and primary limb amputation. However, there are fewer vascular surgeons in Japan than in the Western countries and thus fewer institutions where patients can certainly be treated by a vascular surgeon. Therefore, currently, endovascular treatment by a cardiologist or a radiologist is inevitable even in patients in whom surgical treatment is indicated, which should be addressed in the future.

### Disclosure Statement

All authors have no conflicts of interest to declare with regard to this report.

## Additional Remarks

The outline of this report was presented at the 26th Educational Seminar of the Japanese Society for Vascular Surgery (October 21, 2017, Nagoya).

## References

- 1) Norgren L, Hiatt WR, Dormandy JA, et al. TASC II Working Group. Inter-society consensus for the management of peripheral arterial disease (TASC II). *J Vasc Surg* 2007; **45 Suppl**: S5-67.
- 2) Howard DP, Banerjee A, Fairhead JF, et al. Population-based study of incidence, risk factors, outcome, and prognosis of ischemic peripheral arterial events: implications for prevention. *Circulation* 2015; **132**: 1805-15.
- 3) Creager MA, Kaufman JA, Conte MS. Clinical practice. Acute limb ischemia. *N Engl J Med* 2012; **366**: 2198-206.
- 4) Ascher E. Haimovici's Vascular Surgery, 5th ed. Oxford: Blackwell, 2014.
- 5) Rutherford RB, Baker JD, Ernst C, et al. Recommended standards for reports dealing with lower extremity ischemia: revised version. *J Vasc Surg* 1997; **26**: 517-38.
- 6) TASC II Working Group. Inter-Society Consensus for the Management of PAD (TASC II). Japanese College of Angiology transl. Tokyo: Medical Tribune, 2017. (in Japanese)
- 7) Results of a prospective randomized trial evaluating surgery versus thrombolysis for ischemia of the lower extremity. The STILE trial. *Ann Surg* 1994; **220**: 251-66; discussion, 266-8.
- 8) Nilsson L, Albrechtsson U, Jonung T, et al. Surgical treatment versus thrombolysis in acute arterial occlusion: a randomized controlled study. *Eur J Vasc Surg* 1992; **6**: 189-93.
- 9) Ouriel K, Shortell CK, DeWeese JA, et al. A comparison of thrombolytic therapy with operative revascularization in the initial treatment of acute peripheral arterial ischemia. *J Vasc Surg* 1994; **19**: 1021-30.
- 10) Ouriel K, Veith FJ. Acute lower limb ischemia: determinants of outcome. *Surgery* 1998; **124**: 336-41; discussion, 341-2.
- 11) Ouriel K, Veith FJ, Sasahara AA; for the TOPAS Investigators. Thrombolysis or peripheral arterial surgery: phase I results. *J Vasc Surg* 1996; **23**: 64-73; discussion, 74-5.
- 12) Weaver FA, Comerota AJ, Youngblood M, et al. Surgical revascularization versus thrombolysis for nonembolic lower extremity native artery occlusions: results of a prospective randomized trial. *J Vasc Surg* 1996; **24**: 513-21; discussion, 521-3.
- 13) Berridge DC, Kessel DO, Robertson I. Surgery versus thrombolysis for initial management of acute limb ischaemia. *Cochrane Database Syst Rev* 2013; **6**: CD002784.
- 14) Fogarty TJ, Cranley JJ. Catheter technic for arterial embolectomy. *Ann Surg* 1965; **161**: 325-30.
- 15) de Donato G, Setacci F, Sirignano P, et al. The combination of surgical embolectomy and endovascular techniques may improve outcomes of patients with acute lower limb ischemia. *J Vasc Surg* 2014; **59**: 729-36.
- 16) Byrne RM, Taha AG, Avgerinos E, et al. Contemporary outcomes of endovascular interventions for acute limb ischemia. *J Vasc Surg* 2014; **59**: 988-95.
- 17) Robinson WP 3rd, Belkin M. Acute limb ischemia due to popliteal artery aneurysm: a continuing surgical challenge. *Semin Vasc Surg* 2009; **22**: 17-24.
- 18) Ravn H, Bjorck M. Popliteal artery aneurysm with acute ischemia in 229 patients. Outcome after thrombolytic and surgical therapy. *Eur J Vasc Endovasc Surg* 2007; **33**: 690-5.
- 19) Cervin A, Tjarnstrom J, Ravn H, et al. Treatment of popliteal aneurysm by open and endovascular surgery: a contemporary study of 592 procedures in Sweden. *Eur J Vasc Endovasc Surg* 2015; **50**: 342-50.
- 20) McCord JM. Oxygen-derived free radicals in postischemic tissue injury. *N Engl J Med* 1985; **312**: 159-63.
- 21) Haimovici H. Muscular, renal, and metabolic complications of acute arterial occlusions: myoneuropathic-metabolic syndrome. *Surgery* 1979; **85**: 461-8.
- 22) Fukuda I, Chiyoya M, Taniguchi S, et al. Acute limb ischemia: contemporary approach. *Gen Thorac Cardiovasc Surg* 2015; **63**: 540-8.